

## LITERATURE REVIEW

# Imaging of pulsatile tinnitus caused by vascular anomalies

Andreea Negrila-Mezei<sup>1,2</sup>, Codrut Sarafoleanu<sup>1,2</sup>

<sup>1</sup>ENT&HNS Department, "Sfanta Maria" Hospital, Bucharest, Romania

<sup>2</sup>"Carol Davila" University of Medicine and Pharmacy, Bucharest, Romania

## ABSTRACT

The auditory perception of rhythmic noise synchronous with the heartbeat is defined as pulsatile tinnitus. Pulsatile tinnitus is a symptom that should not be ignored because it may suggest the presence of a vascular abnormality (tumor, congenital anomaly, vascular malformation or vasculopathy). All patients presenting with a complaint of pulsatile tinnitus require a thorough history and physical examination. A correct diagnosis protocol for pulsatile tinnitus consists in a detailed and carefully conducted anamnesis and imaging studies.

**KEYWORDS:** pulsatile tinnitus, arteriovenous fistula, glomus tumor, magnetic resonance imaging, magnetic resonance angiography

## INTRODUCTION

Tinnitus is the perception of sound in the absence of external stimuli; it is equally prevalent in men and women and most common in people aged 40 to 70 years<sup>1,2</sup>.

The auditory perception of rhythmic noise synchronous with the heartbeat is defined as pulsatile tinnitus. In those cases of normal findings on otoscopy, it is a common otological diagnostic dilemma. The differential diagnosis is diverse and includes hydrocephalus, intracranial hypertension, atherosclerosis and valvular heart disease; the condition can be due to serious vascular malformations, such as aneurysms or arteriovenous fistulas (Table 1).

Pulsatile tinnitus is classified into objective and subjective subtypes. These subtypes refer to the ability or respectively inability of the examiner to auscultate a vascular bruit in the periauricular or cervical neck region. Objective tinnitus can result from turbulent or aberrant blood flow or palatal myoclonus<sup>3,4</sup>. Turbulent arterial flow can be caused by arteriovenous fistula (AVF), carotid stenosis, glomus tumor, arteriovenous malformation (AVM), aberrant carotid artery or cardiac murmur<sup>5-7</sup>.

Practitioners separate pulsatile tinnitus into objective and subjective categories, as a means of selecting

patients with a higher likelihood of anatomic pathology. Objective pulsatile tinnitus is routinely evaluated with more invasive tests such as cerebral angiography, because of the perceived higher likelihood of identifying anatomical lesions, while subjective pulsatile tinnitus is often evaluated with less invasive tests such as magnetic resonance imaging or magnetic resonance angiography (MRI/MRA)<sup>8-10</sup>.

All patients presenting with a complaint of pulsatile tinnitus require a thorough history and physical examination, which direct further evaluation and management in patients with pulsatile tinnitus and normal findings on otoscopy<sup>11,12</sup>. Sismanis et al have developed an algorithm to guide the judicious use of diagnostic tests and imaging, given the clinical suspicion<sup>13,14</sup>. This algorithm begins with a thorough history and physical exam, paying close attention to otoscopic and ophthalmoscopic findings, cranial nerve examination, carotid auscultation and cardiac examination. Computed tomography (CT), MRI/MRA, cerebral angiography, carotid duplex, echocardiogram and lumbar puncture (LP) are then utilized appropriately in this algorithm to support clinical suspicion. In this management scheme, patients with pulsatile tinnitus who do not have findings on otoscopy or signs of elevated intracranial pressure are evaluated neuroradiographically,

**Table 1**  
**Causes of pulsatile tinnitus**

Type of lesion	Etiology
Arterial lesion	AVM <sup>1</sup> DAVF <sup>2</sup> Carotid cavernous fistula <sup>3</sup> Aneurysm of the ICA <sup>4</sup> Fibromuscular dysplasia of the ICA <sup>5</sup> Dissection of the ICA <sup>6</sup> Atherosclerosis <sup>7</sup> Vascular anomalies of ear <sup>8</sup> Vascular compression of the eighth nerve <sup>9</sup>
Venous lesion	Jugular bulb anomalies <sup>10</sup> Benign intracranial hypertension <sup>11</sup> Abnormal condylar/mastoid emissary veins <sup>12</sup>
Skull base, temporal lesions	Histiocytosis X <sup>13</sup> Paget's disease <sup>14</sup> Cavernous hemangioma <sup>15</sup> Glomus tumor <sup>16</sup>
Miscellaneous	Anemia, high cardiac output <sup>17</sup>

AVM = arteriovenous malformation; DAVF = dural arteriovenous fistula; ICA = internal carotid artery.

based on the degree of clinical suspicion of the treating practitioner<sup>15-19</sup>.

For young obese women with blurred vision, headaches and papilledema, a diagnosis of benign intracranial hypertension (BIH) may be established by lumbar puncture, after magnetic resonance imaging (MRI)<sup>20,21</sup>. Patients with a history of coronary artery disease, hypertension and neck bruit are likely to have atherosclerotic carotid artery disease and are diagnosed by carotid artery duplex ultrasound. However, for patients without symptoms suggestive of coronary artery disease or BIH, but with a complaint of subjective or objective pulsatile tinnitus, initial diagnostic evaluation may begin with one of the following radiographic examinations: computed tomography (CT), MRI, magnetic resonance imaging combined with magnetic resonance angiography (MRI/MRA) and angiography<sup>17,22-24</sup>. These symptoms may be due to serious vascular malformations, such as transverse or sigmoid sinus dural arteriovenous fistula (transverse or sigmoid sinus [TS] DAVF). Left untreated, TS DAVF may result in significant morbidity and mortality<sup>25-27</sup>.

## IMAGING IN PULSATILE TINNITUS

The radiologic evaluation should be individualized according to the characteristics of the pulsatile tinni-

tus (arterial/venous type, subjective/objective) and other clinical findings such as obesity, papilledema, retrotympenic pathology and the presence of a head/neck bruit<sup>28</sup>.

Recent experience with CT angiography suggests that this test is more sensitive than magnetic resonance angiography/venography (MRA/MRV) in evaluating intracranial vascular lesions and it is likely that it will replace the latter in the near future<sup>19,29-31</sup>. This is a fast imaging technique and, because the upper neck is included, cervical vascular pathology can be detected in the same study. Today, many neuroradiologists prefer CT angiography as a substitute to MRA; however, further studies are needed to document the superiority of this very promising radiologic test<sup>32</sup>.

### a) Tumoral causes

Glomus tumors (chemodectomas, paragangliomas), vascular neoplasms that arise from the paraganglia (normal structures that accompany cranial nerves), are the most frequent tumoral cause of pulsatile tinnitus<sup>33,34</sup>. The glomus tumors most likely to present with pulsatile tinnitus are glomus tympanicum, glomus jugulare and glomus jugulotympanicum.

**Glomus tympanicum** tumors can occur anywhere along the Jacobson nerve, which runs across the medial wall of the middle ear<sup>12,35,36</sup> so it is important to examine the entire middle ear closely when imaging a patient with pulsatile tinnitus. The tumor is usually visible as a red-

dish, pulsatile mass behind an intact tympanic membrane<sup>37,38,39</sup>. Small tumors are best seen on a mastoid bone CT scan, bone window, thin axial section.

**Glomus jugulare tumors** arise from paraganglia in the adventitia of the jugular bulb<sup>40</sup>. If the tumor is limited to the jugular fossa, the otoscopic examination may be normal. In those cases in which glomus jugulare extends into the middle ear it is known as **glomus jugulo-tympanicum**<sup>41-43</sup>.

In case of glomus jugulare tumors, MR imaging shows the tumor characteristics better than CT<sup>13,44</sup>, but CT reveals the anatomic extent of the tumor much more clearly (Figure 1). The earliest abnormality detectable on a temporal bone CT scan is the erosion of the lateral and anterior walls of the osseous jugular fossa. In some cases an enlarged inferior tympanic canaliculus can be seen representing the hypertrophy of the inferior tympanic artery that supplies this vascular tumor<sup>45,46</sup>.

#### b) Vascular causes

Pulsatile tinnitus may be caused by both intra- and extracranial vascular abnormalities and it can be objective as well as subjective<sup>47-49</sup>.

**Vascular malformations** represent abnormal communications between the arterial and venous systems and they may be congenital or not<sup>50-52</sup>. Most extracranial arteriovenous malformations (AVMs) are clinically apparent<sup>53</sup>, but the conventional angiography must be performed because it identifies the arterial supply and venous drainage<sup>54-56</sup>. Brain parenchymal AVMs may be more obscure, but are usually identified on contrast-enhanced CT and MR studies. Even if a dural AVM or arteriovenous fistula (AVF) is a well-known cause of headache and hemorrhagic infarction<sup>57-59</sup>, it is also considered the most frequent cause of objective pulsatile tinnitus in those patients with normal otoscopic examination<sup>50,51</sup>. Considering this aspect, it is important to know that this

vascular malformations are often invisible on CT and MR studies<sup>60,61</sup>. So, a normal CT/MRI result does not exclude a dural AVM or AVF<sup>62,63</sup>.

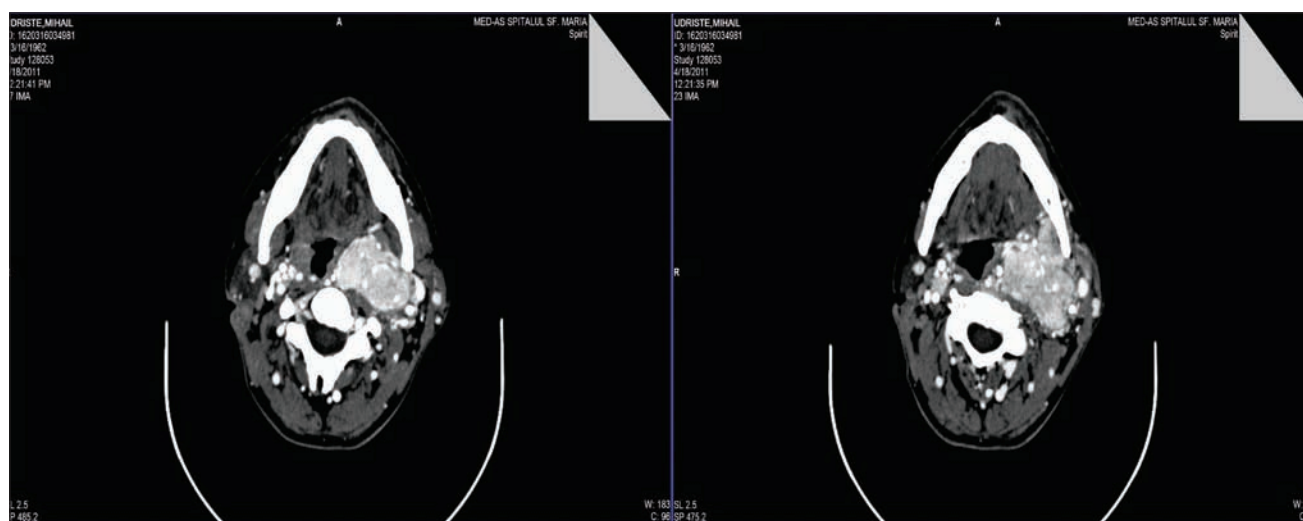
**Congenital vascular anomalies** represent aberrant courses of the petrosal vessels and are extremely rare (50 cases of aberrant internal carotid artery in the middle ear have been reported until now)<sup>64-66</sup>.

The internal carotid artery (ICA) may present 4 variants:

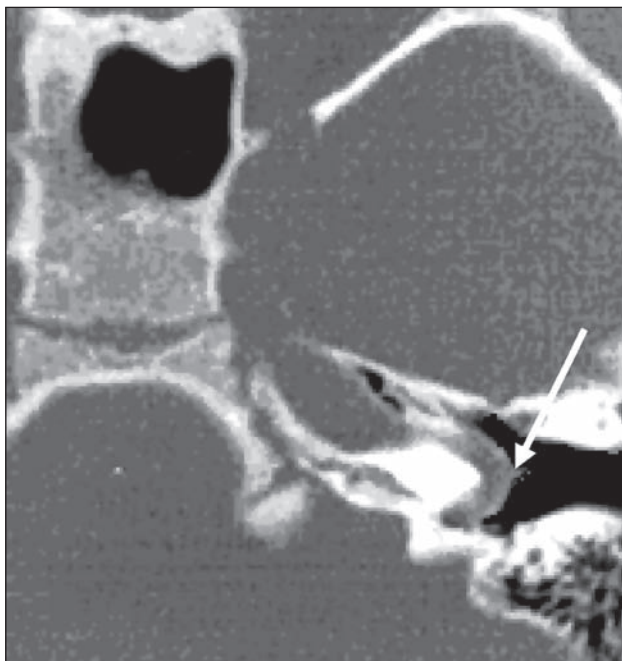
- normal location, exposed, lacking bony cover;
- congenital vascular abnormality secondary to regression of the cervical ICA during embryogenesis, exposed and following an abnormal course;
- aneurysm with protrusion toward the middle ear;
- aberrant course (Figure 2)<sup>67-69</sup>.

The most common symptoms presented by patients with aberrant ICA tend to be pulsatile tinnitus, conductive hearing loss and earache, although many of these patients may remain asymptomatic<sup>70</sup>. Otoscopy may reveal a normal tympanic membrane with a mass in the middle ear that, in some cases, is pulsating. Imaging studies are fundamental for diagnosis, a high resolution computerized tomography (CT) being the technique of choice and it can be complemented with a magnetic resonance angiography<sup>71-74</sup>.

In some particular cases a persistent stapedial artery arises from an aberrant or a normal internal carotid artery<sup>75</sup>. The stapedial artery is a normal fetal artery that normally regresses before birth and runs through the obturator foramen (the space between the crura of the stapes) across the promontory in the middle ear, then goes along the tympanic portion of the facial nerve canal near the geniculate fossa, supplying the territory of the middle meningeal artery<sup>76-79</sup>. When the stapedial artery persists, the middle meningeal artery will not develop and neither does its opening in the skull base, the foramen spinosum<sup>80</sup>. The arterial phase of conventional angiography can reveal the persis-



**Figure 1** Cervical CT scan, axial slices - glomus jugulare tumor



**Figure 2** Aberrant ICA (arrow) in the middle ear

tency of the stapedial artery and in the same time the artery may be too small to be identified by current MR angiographic techniques<sup>81,82</sup>. When the identity of a middle ear mass is in question, absence of the foramen spinosum seen on a thin-bone section CT scan strongly suggests that the “mass” is a persistent stapedial artery<sup>83-86</sup>.

In case of a dehiscent jugular vein due to the lack of a complete cortical covering the vein bulges into the

middle ear from below. The otoscopic examination shows a bluish and pulsatile mass.

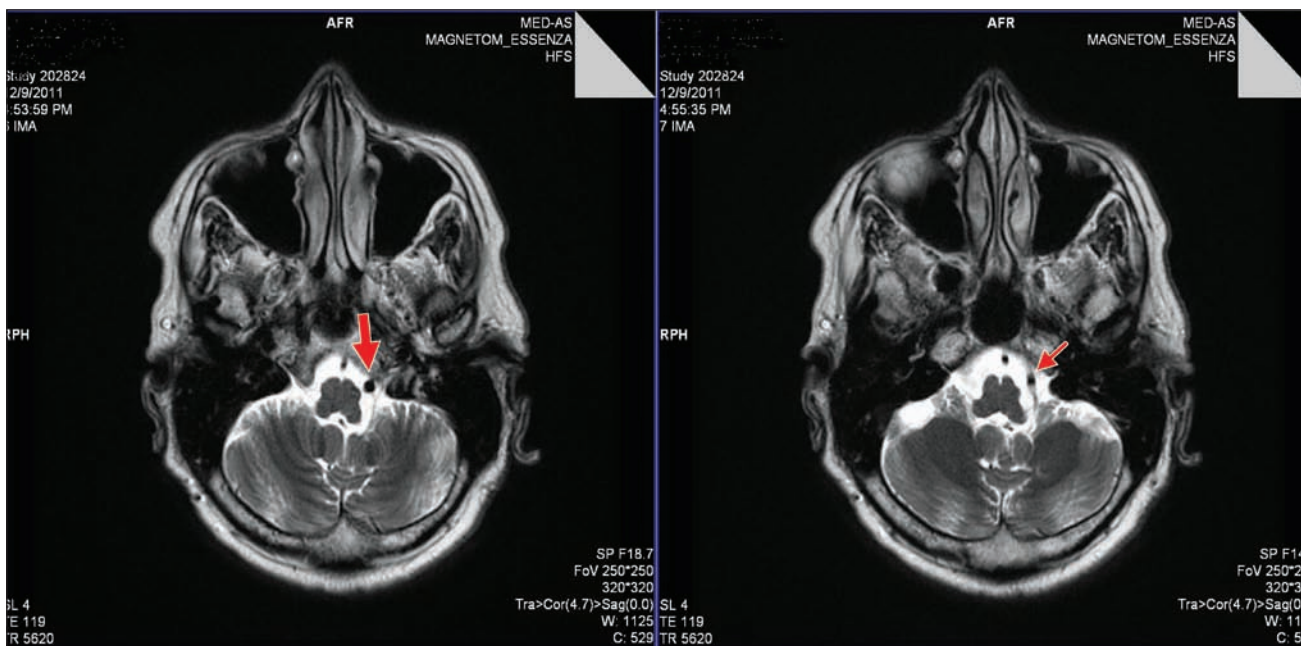
Another cause of pulsatile tinnitus may be a jugular diverticulum, a protrusion of the jugular bulb superior and medial to the jugular fossa<sup>87-89</sup>. Although the diverticulum may be associated with tinnitus, it does not extend into the middle ear and cannot be seen at otoscopy.

#### Other vascular abnormalities

Objective pulsatile tinnitus can be caused by atherosclerotic carotid artery disease, tinnitus being, sometimes, the first manifestation of the disease<sup>90-92</sup>. Fibromuscular dysplasia of the internal carotid artery most frequently manifests with intracranial ischemia, but tinnitus is the next most frequent manifestation, and many patients have both<sup>93</sup>. Contrast-enhanced CT or CT angiography can establish the diagnosis.

Some investigators believe that a vessel that compresses the cochlear nerve in the internal auditory canal or the eighth cranial nerve, at the brainstem root entry zone - a neurovascular conflict - may cause pulsatile tinnitus (Figure 3)<sup>94-96</sup>.

Patients with benign intracranial hypertension (idiopathic intracranial hypertension) often present with headaches or visual disturbances<sup>97-100</sup>, even if it is reported to be the most frequent diagnosis in patients with pulsatile tinnitus<sup>101</sup>. An elevated opening pressure at lumbar puncture confirms the diagnosis. Imaging studies are usually normal and are useful to exclude other causes of increased intracranial pressure<sup>102</sup>.



**Figure 3** Brain MRI scan, axial slices – left vertebral artery with tortuous course and increased size; aberrant branch emerging from the left vertebral artery runs intimate with the VII-VIII nerves in the cisternal area; suggestive aspect for neurovascular conflict

## CONCLUSIONS

Pulsatile tinnitus is a symptom that should not be ignored because it may suggest the presence of a vascular abnormality (tumor, congenital anomaly, vascular malformation or vasculopathy). For patients with objective pulsatile tinnitus, the most common imaging study is contrast-enhanced temporal bone or brain CT scan. If a dural vascular malformation is suspected, conventional angiography may be indicated. In case of a dissecting carotid aneurysm, magnetic resonance images of the neck or CT angiography or MR angiography is essential.

A correct diagnosis protocol for pulsatile tinnitus consists in a detailed and carefully conducted anamnesis and imaging studies.

## REFERENCES

- Schleuning A.J. 2<sup>nd</sup> - Management of the patient with tinnitus. *Med Clin North Am*, 1991; 75:1225-37.
- Sanchez T.G., Santoro P.P., Torres de Medeiros I.R., et al. - Magnetic resonance angiography in pulsatile tinnitus: role of normal variations. *Int J Tinnitus*, 1998; 4:122-6.
- van de Hynning P., Class J., Brooks J., et al. - Surgical management of hearing impairment in audiological medicine. *Textbook of Audiological Medicine*, London, Martin Dunitz, 2003;603-641.
- Sismanis, A. - Pulsatile Tinnitus. *Am J Otol*, 1998; 19:472-477.
- Thie A., Goossens-Merkel H., Freitag J., Spitzer K., Zeumer H., Kunze K. - Pulsatile tinnitus: clinical and angiological evaluation. *Cerebrovasc Dis*, 1993; 3:160-167.
- Applebaum E.L., Valvassori G.E. - Auditory and vestibular system findings in patients with vascular loops in the internal auditory canal. *Ann Otol Rhinol Laryngol Suppl*, 1984; 112:63-70.
- McCabe B.F., Harker L.A. - Vascular loop as a cause of vertigo. *Ann Otol Rhinol Laryngol*, 1983; 92:542-543.
- De Monti M., Ghilardi G., Cavemi L., et al. - Multidetector helical angio CT oblique reconstructions orthogonal to internal carotid artery for preoperative evaluation of stenosis: a prospective study of comparison with color Doppler US, digital subtraction angiography and intraoperative data. *Minerva Cardioangiolog*, 2003; 51:373-385.
- Jayaraman M.V., Mayo-Smith W.W. - Multi-detector CT angiography of the intracranial circulation: normal anatomy and pathology with angiographic correlation. *Clin Radiol*, 2004; 59:690-698.
- Sanelli P.C., Mifsud M.J., Stieg P.E. - Role of CT angiography in guiding management decisions of newly diagnosed and residual arteriovenous malformations. *AJR Am J Roentgenol*, 2004; 183:1123-1126.
- Karamessini M.T., Kagadis G.C., Petsas T., et al. - CT angiography with three-dimensional techniques for the early diagnosis of intracranial aneurysms: comparison with intra-arteria DSA and the surgical findings. *Eur J Radiol*, 2004; 49:212-223.
- Weissman J.L., Hirsch B.E. - Beyond the promontory: the multifocal origin of glomus tympanicum tumors. *AJNR Am J Neuroradiol*, 1998; 19:119-122.
- Hasso A.N. - Imaging of pulsatile tinnitus: basic examination versus comprehensive examination package. *AJNR Am J Neuroradiol*, 1994;15:890-892.
- Koenigsberg R.A. - Spontaneous pulsatile tinnitus secondary to a dural malformation not visualized by magnetic resonance angiography. *Clin Imaging*, 1996;20:95-98.
- Levine S.B., Snow Jr J.B. - Pulsatile tinnitus. *Laryngoscope*, 1987; 97:401-406.
- Osborn A.G. - Diagnostic neuroradiology. St.Louis, Mo: Mosby-Year Book, 1994; 301-306.
- Roy D., Lavigne F., Raymond J. - Pulsatile tinnitus and dural arteriovenous fistula of the transverse sinus. *J Otolaryngol*, 1993; 22:409-412.
- Schuknecht H.F. - Pathology of the Ear. Philadelphia: Lea & Febiger; 1993;672.
- Hernández Valencia G., Solís Rábago L., González González L., Cano Bonilla A. - Arteria carótida aberrante en oído medio. *Acta de Pediatr Mex.*, 2004;25: 262-8.
- Lo W.W.M., Solti-Bohman L.G., McElveen J.T. - Aberrant carotid artery: radiologic diagnosis with emphasis on high-resolution computed tomography. *RadioGraphics*, 1985; 5:985-993.
- Schuknecht H.R. - Pathology of the ear. 2nd ed. Philadelphia, Pa: Lea and Febiger, 1993.
- Guinto F.C., Garrabrant E.C., Radcliffe W.B. - Radiology of the persistent stapedial artery. *Radiology*, 1972; 105:365-369.
- Hasso A.N., Casselman J.W., Broadwell R.A. - Temporal bone congenital anomalies. In: Som P.M., Curtin H.D., eds. - Head and neck imaging. 3rd ed. St Louis, Mo: Mosby-Year Book, 1997; 1351-1390.
- Sismanis A., Stamm M.A., Sobel M. - Objective tinnitus in patients with atherosclerotic carotid artery disease. *Am J Otol*, 1994; 15:404-407.
- Sismanis A., Smoker W.R.K. - Pulsatile tinnitus: recent advances in diagnosis. *Laryngoscope*, 1994;104:681-688.
- Jannetta P.J. - Neurovascular compression in cranial nerve and systemic disease. *Ann Surg*, 1980; 192:518-525.
- Moller M.B., Moller A.R., Jannetta P.J., Jho H.D. - Vascular decompression surgery for severe tinnitus: selection criteria and results. *Laryngoscope*, 1993;103:421-427.
- Ahlskog J.E., O'Neill B.P. - Pseudotumor cerebri. *Ann Intern Med*, 1982; 97:249-256.
- Sismanis A. - Pulsatile tinnitus: a 15 year experience. *Am J Otol*, 1998; 19:472-477.
- Fukui M.B., Weissman J.L., Curtin H.D., Kanal E. - T2-weighted MR characteristics of internal auditory canal masses. *AJNR Am J Neuroradiol*, 1996; 17:1211-1218.
- Chan S.W.Y., Reade P.C. - Tinnitus and temporomandibular pain-dysfunction disorder. *Clin Otolaryngol*, 1994;19:370-380.
- Parker W.S., Chole R.A. - Tinnitus, vertigo, and temporomandibular disorders. *Am J Orthod Dentofacial Orthop*, 1995;107:153-158.
- Weber P.C., Adkins W.Y. - The differential diagnosis of Meniere's disease. *Otolaryngol Clin North Am*, 1997;30:977-986.
- Weber P.C., Cass S.P. - Neuro-otologic manifestations of Arnold-Chiari malformation. *Otolaryngol Head Neck Surg*, 1993; 109:853-860.
- Hernández Valencia G., Solís Rábago L., González González L., Cano Bonilla A. - Arteria carótida aberrante en oído medio. *Acta de Pediatr Mex.*, 2004;25: 262-8.
- Figuerola E., Gómez E., Teruel J., Sánchez J.M., Llano A., Rosell R. - Carótida interna aberrante en oído medio. *Acta Otorrinolaring Esp.*, 1989; 40:47-50.
- Billier J.A., Linthicum F.H. Jr. - Aberrant carotid artery. *Otology and Neurotology*, 2002; 23:407-8.
- Rando T.A., Fishman R.A. - Spontaneous intracranial hypotension: report of two cases and review of the literature. *Neurology*, 1992;42:481-487.
- Mukherji S.K., Albernaz V., Lo W.W., et al. - Papillary endolymphatic sac tumors: CT, MR imaging, and angiographic findings in 20 cases. *Radiology*, 1997; 202:801-808.
- Jürgen G., Fradis M., Schipper J. - Aberrant internal carotid artery in the middle ear. *The Annals of Otolaryngology & Laryngology*, 2001; Sep:110-9.
- Phelps P., Lloyd G. - Vascular masses in the middle ear. *Clin Radiol*, 1986;37:359-64.
- Selesnick S.H., Lessow A.S. - Aberrant internal carotid artery. *Am J Otolaryngol*, 1999; 20:403-404.
- Hasso A., Broadwell R. - Anomalías congénitas. In: Som P., Bergeron R., editors. - Radiología de cabeza y cuello. Madrid: Mosby; 1993; 976-8.
- Schuknecht H.F. - Pathology of the Ear. Philadelphia: Lea & Febiger; 1993; 672.
- Teruel J., Gómez E., Figuerola E., Castañer F., Ferrer J., Pont J., et al. - Diagnóstico mediante tomografía computarizada de masas vasculares de oído medio. *Radiología*, 1990;32:407-11.
- Ridder G.J. - Aberrant internal carotid artery in the middle ear. *Annals of Otolaryngology & Laryngology*, 2001; 110:892-4.

47. Lapayowker M.S., Liebman E.P., Ronis M.L., Saber J.N. - Presentation of the internal carotid artery as a tumor in the middle ear. *Radiology*, 1971; 98:293-7.
48. Saito H., Chikamory Y., Yanagihara N. - Aberrant carotid artery in the middle ear. *Arch Oto Rhino Laryngol*, 1975; 209:83-87.
49. Campbell G., Renner G., Estrem S.A. - Bilateral aberrant internal carotid arteries. *Otolaryng Head Neck Surg*, 1992; 107:124-128.
50. Goodman R.S., Cohen N.L. - Aberrant internal carotid in the middle ear. *Ann Otol*, 1981;90:67-9.
51. Dietz R., Davis W.L., Harnsberger H.R., Jacobs J.M., Blatter D.D. - TIMR imaging and MR angiography in the evaluation of pulsatile tinnitus. *Am J Neuroradiol*, 1994;15(5):879-89.
52. Levine S.B., Snow Jr J.B. - Pulsatile tinnitus. *Laryngoscope*, 1987; 97:401-406.
53. Roy D., Lavigne F., Raymond J. - Pulsatile tinnitus and dural arteriovenous fistula of the transverse sinus. *J Otolaryngol*, 1993; 22:409-412.
54. Glasscock M.E., Seshul M., Seshul M.B. - Bilateral aberrant internal carotid artery case presentation. *Arch Otolaryngol Head Neck Surg*, 1993; 119:335-339.
55. Ashikaga R., Araki Y., Ishida O. - Bilateral aberrant internal carotid arteries. *Neuroradiology*, 1995; 37:655-657.
56. Benton C., Bellet P.S. - Imaging of congenital anomalies of the temporal bone. *Neuroimaging Clin N Am*, 2000; 10:35-53.
57. Shin E.J., Lalwani A.K., Dowd C.F. - Role of Angiography in the Evaluation of Patients with Pulsatile Tinnitus. *Laryngoscope*, 2000; 110:1916-1920.
58. Makins A.E., Nikolopolous T.P., Ludman C., O'Donoghue G.M. - Is there a correlation between vascular loops and unilateral auditory symptoms? *Laryngoscope*, 1998; 108(11Pt1):1739-42.
59. Sirikci A., Bayazit Y., Ozer E. - Magnetic resonance imaging based classification of anatomic relationship between the cochleovestibular nerve and anterior inferior cerebellar 10 - Kircher artery in patients with non-specific neuro-otologic symptoms. *Surg Radiol Anat*, 2005; 27(6):531-5.
60. Presutti L., Laudadio P. - Jugular bulb diverticula. *ORL J Otorhinolaryngol Relat Spec*, 1991; 53(1):57-60.
61. Bilgen C., Kirazli T., Ogut F., Total S. - Jugular bulb diverticula: clinical and radiologic aspects. *Otolaryngol Head Neck Surg*, 2003; 128(3):382-6.
62. López-Escámez J.A., Gamero C., Castillo J.L., Amador J.M. - Pulsatile tinnitus associated with a high jugular bulb and slow venous blood flow. *Acta Otorrinolaringol Esp*, 1997;48(7):557-60.
63. Weissman J.L., Hirsch B.E. - Imaging of Tinnitus: A Review. *Radiology*, 2000; 216:342-349.
64. Arenberg I.K., McCreary H.S. - Objective tinnitus aurium and dural arteriovenous malformations of the posterior fossa. *Ann Otol Rhinol Laryngol*, 1972; 80:111-120.
65. Waldvogel D., Mattle H.P., Sturzenegger M., Schroth G. - Pulsatile tinnitus—a review of 84 patients. *J Neurol*, 1998; 245:137-142.
66. Sismanis A. - Pulsatile tinnitus: a 15-year experience. *Am J Otol*, 1998;19:472-477.
67. Levine S.B., Snow J.B., Jr. - Pulsatile tinnitus. *Laryngoscope*, 1987;97:401-406.
68. Dufour J.J., Lavigne F., Plante R., et al. - Pulsatile tinnitus and fibromuscular dysplasia of the internal carotid. *J Otolaryngol*, 1985; 14:293-295.
69. Saeed S.R., Hinton A.E., Ramsden R.T., et al. - Spontaneous dissection of the intrapetrous internal carotid artery. *J Laryngol Otol*, 1990; 104:491-493.
70. Sismanis A., Stamm M.A., Sobel M. - Objective tinnitus in patients with atherosclerotic disease. *Am J Otol*, 1994;15:404-407.
71. Steffan T.N. - Vascular anomalies of the middle ear. *Laryngoscope*, 1968;78:171-197.
72. Lesinski S.G., Chambers A.A., Komray R., et al. - Why not the eighth nerve neurovascular compression: probable cause for pulsatile tinnitus. *Otolaryngol Head Neck Surg* 1979;87:89-94.
73. Adler J.R., Ropper A.H. - Self-audible venous bruits and high jugular bulb. *Arch Neurol*, 1986; 43:257-259.
74. Marion M., Hinojosa R., Kahn A.A. - Persistence of the stapedia artery: a histopathologic study. *Otolaryngol Head Neck Surg*, 1985; 93:298-312.
75. Sismanis A. - Otologic manifestations of benign intracranial hypertension syndrome: diagnosis and management. *Laryngoscope*, 1987; 97(Suppl 42):1-17.
76. Lamberg P., Cantrell R. - Objective tinnitus in association with abnormal posterior condylar emissary vein. *Am J Otolaryngol*, 1986; 7:204-207.
77. Bonafe A., Joomye H., Jaeger P., Fraysse B., Manelfe C. - Histiocytosis X of the petrous bone in the adult: MRI. *Neuroradiology*, 1994; 36:330-333.
78. Gibson R. - Tinnitus in Paget's disease with external carotid ligation. *J Laryngol Otol*, 1973;87:299-301.
79. Taber J.R. - Cavernous hemangioma of the middle ear and mastoid. *Laryngoscope*, 1965; 75:673-677.
80. Spector G.J., Ciralsky R.H., Ogura J.H. - Glomus tumors in the head and neck, III: analysis of clinical manifestations. *Ann Otol Rhinol Laryngol*, 1975; 84:73-79.
81. Cochran J.H., Kosmicki P.W. - Tinnitus as a presenting symptom of pernicious anemia. *Ann Otol Rhinol Laryngol* 1979;88:297.
82. Shah S.B., Lalwani A.K., Dowd C.F. - Transverse/sigmoid sinus dural arteriovenous fistulas presenting as pulsatile tinnitus. *Laryngoscope*, 1999; 109:54-58.
83. Koeningberg R.A. - Spontaneous pulsatile tinnitus secondary to a dural malformation not visualized by magnetic resonance angiography. *Clin Imaging*, 1996; 20:95-98.
84. Russell E.J., De Michaelis B.J., Wiet R., Meyer J. - Objective pulse-synchronous 'essential' tinnitus due to narrowing of the transverse dural venous sinus. *Int Tinnitus J*, 1995;1:127-137.
85. Buckwalter J.A., Sasaki C.T., Virapongse C., et al. - Pulsatile tinnitus arising from jugular megabulb deformity: a treatment rationale. *Laryngoscope*, 1983; 93:1534-1539.
86. Silbergleit R., Quint D.J., Mehta B.A., Patel S.C., Metes J.J., Noujaim S.E. - The persistent stapedia artery. *AJNR Am J Neuroradiol*, 2000; 21:572-577.
87. Govaerts P.J., Marquet T.F., Cremers C.W.R.J., Offeciers F.E. - Persistent stapedia artery: does it prevent successful surgery? *Ann Otol Rhinol Laryngol*, 1993; 102:724-728.
88. Lasjaunias P., Berenstein A., Ter Brugge K.G. - Surgical Neuroangiography, *Clinical Vascular Anatomy and Variations*. 2nd ed. New York: Springer-Verlag; 2001.
89. Padgett D.H. - The development of the cranial arteries in the human embryo. *Contrib Embryol*, 1948; 32:205-261.
90. Congdod E.D. - Transformation of the aortic-arch system during the development of the human embryo. *Contrib Embryol*, 1922; 14:47-110.
91. Steffen T.H. - Vascular anomalies of the middle ear. *Laryngoscope*, 1968; 78:171-197.
92. Lapayowker M.S., Liebman E.P., Ronis M.L., Safer J.N. - Presentation of the internal carotid artery as a tumor of the middle ear. *Radiology*, 1971; 98:293-297.
93. Swartz J.D., Buzarnic M.L., Naidich T.P., Lowry L.D., Doan H.T. - Aberrant internal carotid artery lying within the middle ear. *Neuroradiology*, 1985; 27:322-326.
94. Lo W.W.M., Solti-Bohman L.G., McElveen J.T. - Aberrant Carotid artery: radiologic diagnosis with emphasis on high-resolution computed tomography. *Radiographics*, 1985;5:985-993.
95. McElveen J.T., Lo W.W.M., El Gabri T.H., Nigri P. - Aberrant internal carotid artery: classic findings on computed tomography. *Otolaryngol Head Neck Surg*, 1986;94:616-621.
96. Davis W.L., Harnsberger H.R. - MR Angiography of an aberrant internal carotid artery. *AJNR Am J Neuroradiol*, 1991; 12:1225.
97. Ginsberg L.E., Pruett S.W., Chen M.Y.M., Elster A.D. - Skull-based foramina of the middle cranial fossa: reassessment of normal variation with high-resolution CT. *AJNR Am J Neuroradiol*, 1994; 15:283-291.
98. Thiers F.A., Sukai O., Poe D.S., Curtin H.D. - Persistent stapedia artery: CT findings. *AJNR Am J Neuroradiol*, 2000; 21:1551-1554.
99. Moreano E.H., Puparella M.M., Zelterman D., Goycoolea M.V. - Prevalence of facial canal dehiscence and of persistent stapedia artery in the human middle ear: a report of 1000 temporal bones. *Laryngoscope*, 1994; 104:309-320.
100. Guinto F.C., Garrabrant E.C., Radcliffe W.B. - Radiology of the persistent stapedia artery. *Radiology*, 1972; 105:365-369.
101. Lasjaunias P., Moret J., Manelfe C., The'ron J., Hasso T., Seeger J. - Arterial anomalies at the base of the skull. *Neuroradiology*, 1977; 13:267-272.
102. Goldman N.C., Singleton G.T., Holly E.H. - Aberrant internal carotid artery. *Arch Otolaryngol*, 1971; 94:269-273.