

LITERATURE REVIEW

Revision surgery in chronic rhinosinusitis - a point of view

Codrut Sarafoleanu

"Carol Davila" University of Medicine and Pharmacy, Bucharest, Romania

ABSTRACT

Revision sinus surgery in chronic rhinosinusitis has to be indicated when the previous surgical procedure failed to relieve patients' symptoms. There seems to be four reasons why choosing revision endoscopic sinus surgery: incomplete previous surgery, complications of previous surgery, recurrent or persistent sinus disease and histological evidence of unexpected neoplasia. Also, environmental and local factors play an important role. In each particular case, the surgeon should take into account details about patient medical history, the disease itself, previous surgery type and the CT/MRI scans. Keeping all these in mind, the author tried to emphasize the most important aspects of revision surgery in patients with chronic rhinosinusitis.

KEYWORDS: revision endoscopic sinus surgery, chronic rhinosinusitis, ethmoidectomy, antrostomy

INTRODUCTION

Revision surgery in chronic rhinosinusitis (CRS) is indicated when the previous surgical procedure failed to relieve patients' symptoms. The rate of revision surgery in CRS without nasal polyposis is, according to EPOS 2012, 10-15% and with a higher percentage in patients with CRS with nasal polyps¹.

There are two important principles we have to follow when recommending revision sinus surgery: **think about revision endonasal surgery – only if maximal medical treatment is ineffective, and keep in mind that complication rates and the risk of recurrence are higher than after primary surgery².**

REVISION ENDOSCOPIC SINUS SURGERY

According to Kountakis, there are four reasons which can lead to revision endoscopic sinus surgery (ESS): incomplete previous surgery, complications of previous surgery, recurrent or persistent sinus disease and histological evidence of unexpected neoplasia^{2,3}. From our point of view we have to look at the disease itself, the host and the environmental factors, the most important ones being smoking (one of the most significant), inhalant exposure, moulds and emotional stress⁴.

The general host factors that are significantly cited in the literature are: immunodeficiency, Samter's triad, reactive airways disease, genetic factors, asthma and age. If we consider the local host factors they belong to the disease itself (symptoms severity and the CT score, persistent or recurrent polyposis and the extent of the disease outside the original surgical field).

The so-called iatrogenic disease (scarring, adhesions, blocked ostia, mucus recirculation, etc.) appears due to existence of the inflammation in previously non-operated sinuses, poor surgical technique, inadequate local management or poor postoperative care².

We have to emphasize that there are well-known problematic cases, such as patients with nasal polyps and NSAID intolerance, extensive disease, allergic fungal rhinosinusitis and underlying problems like cilia abnormalities, immunodeficiency or cystic fibrosis².

When analyzing a case suitable for revision endoscopic sinus surgery, we have to take into consideration the following aspects: the type of previous surgery, the CT-scan and MRI details before and after the first operation and the patient's past medical history. The first step should consist in preoperative medical treatment according to the cultures from the sinuses, local aspect at the nasal endoscopy and to the host comorbidities such as allergy, extra esophageal reflux, etc. Finally, the technical approach should be pre-

pared using the planning in at least two, preferably three, CT scan planes (axial, sagittal and coronal) in order to be able to identify the problematic areas.

At the same time, the surgeon should keep in mind that clear postnasal drip with minimal mucosal disease on CT-scan is not likely to find relief with revision surgery, so dealing with patients' expectations is a critical part in the revision surgery process⁵.

The patient's past medical history should include details in order to identify the real pathology involving the sinuses, the osteitis and the inconsistent medical treatment or poor technical approach, according to the extension of the disease.

It is very important to know some information about the type of the previous surgery: if it was an external or endoscopic approach and maybe some details from the surgical procedure (usually it is difficult to have these details). According to many authors, one can discover the following pathologic findings in patients with revision surgery⁶:

- Incomplete anterior and/or posterior ethmoidectomy
- Middle turbinate lateralization
- Failure of fronto-nasal connection
- Remnant of uncinata and middle meatal antrostomy stenosis
- Recurrence of the nasal polyps
- Residual Haller cells
- Concha Bullosa

The most common identified diseased areas in revision surgery are as it follows^{3,7}: remnant uncinata process (mucus recirculation) (Figure 1), ethmoid bony partitions attached to the medial orbital wall or skull base (nidus for persistent mucosal inflammation) (Figure 2), osteitic foci, remnant infraorbital cells obstructing the natural maxillary ostium (Figure 3), lateralized middle turbinate (scars) (Figure 4), residual Onodi cell or posterior ethmoid cell (Figure 5), remnant supraorbital or frontal recess cells and neo-osteogenesis of the skull base and frontal recess.

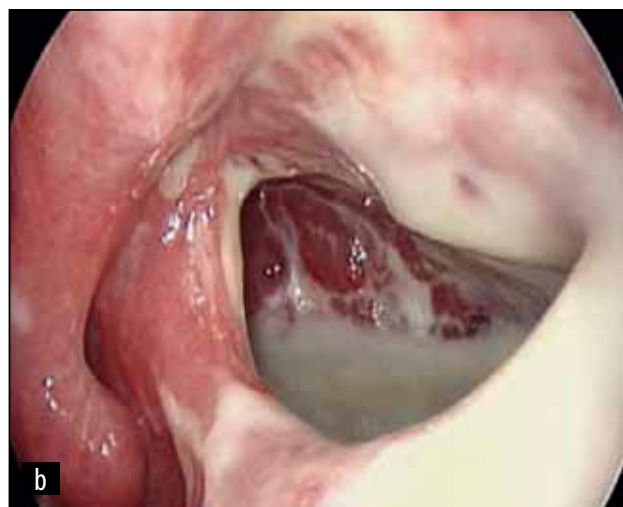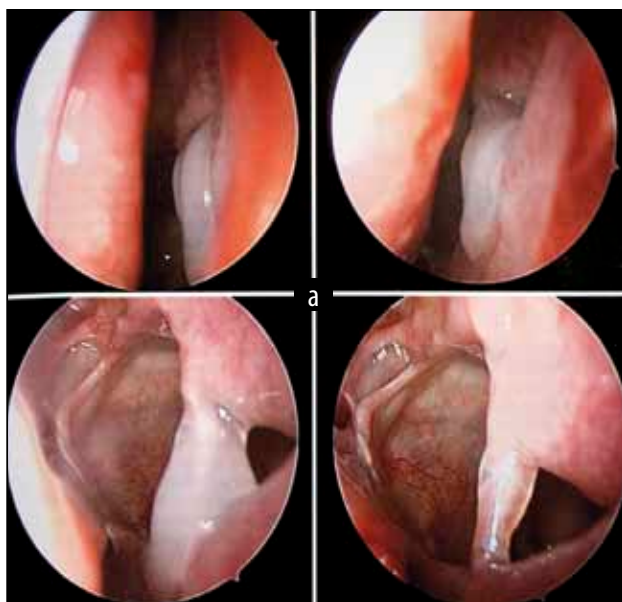


Figure 1 Remnant uncinata process: a) mucus recirculation; b) purulent secretions in the maxillary sinus – posterior antrostomy or improper indication?

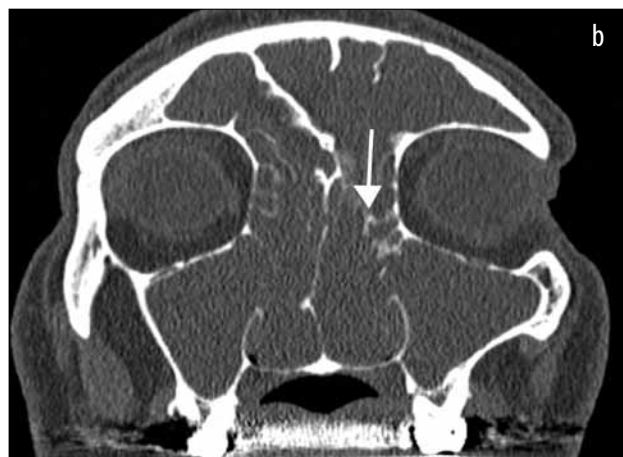
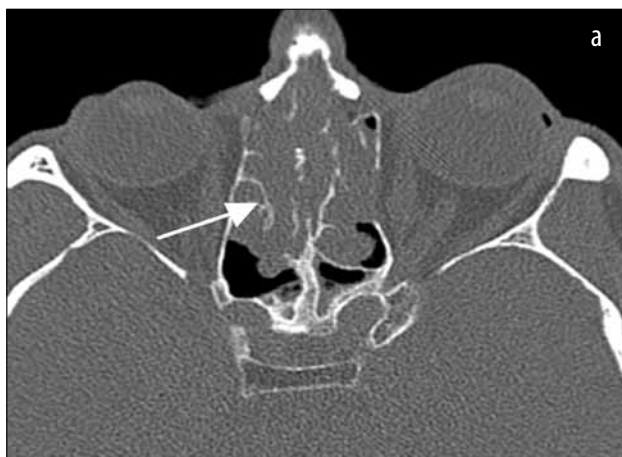
Figure 2 Cranio-facial CT scan, axial (a) and coronal (b) slices: ethmoid bony partitions – nidus for persistent mucosal inflammation.

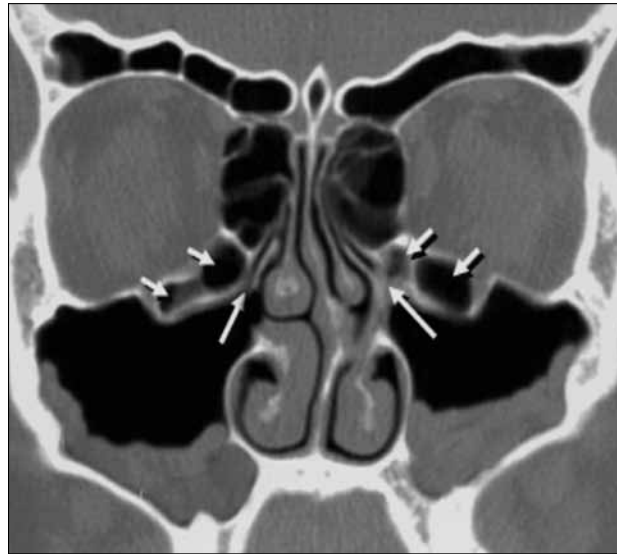

Figure 3 Cranio-facial CT scan, coronal slice - remnant infraorbital cells obstructing the natural maxillary ostium.

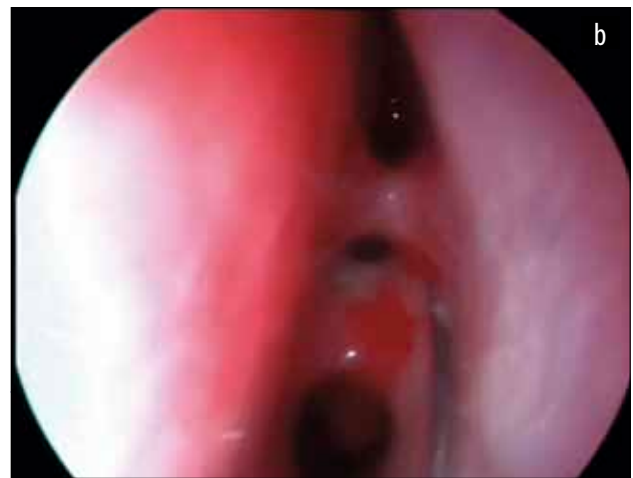
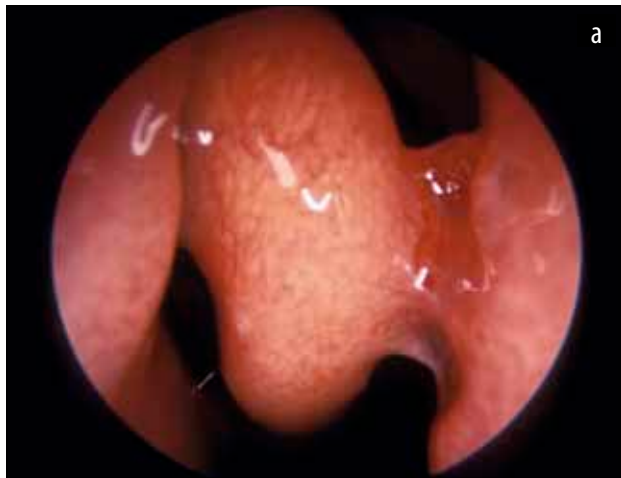
Figure 4 a, b Lateralized middle turbinate – scars (nasal endoscopic examination)

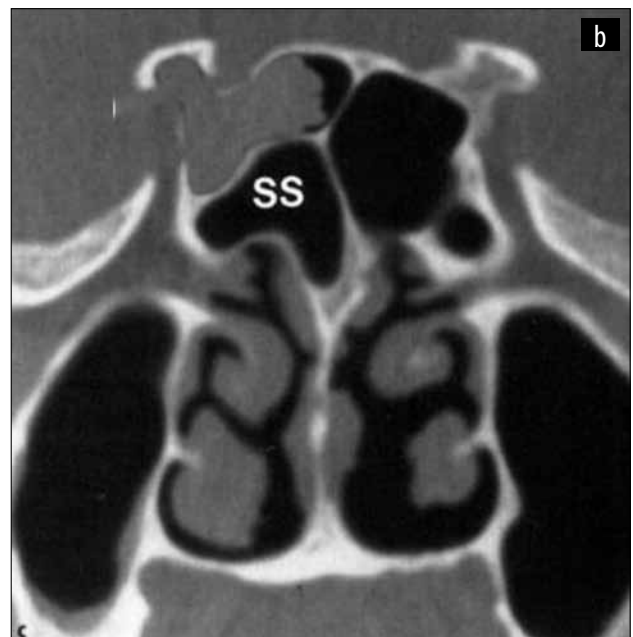
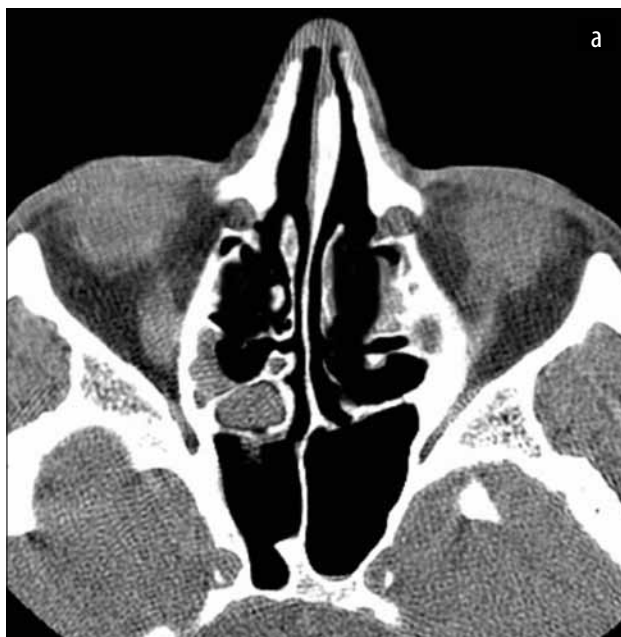

Figure 5 Cranio-facial CT scan, axial (a) and coronal (b) slices - residual Onodi cell or posterior ethmoid cell

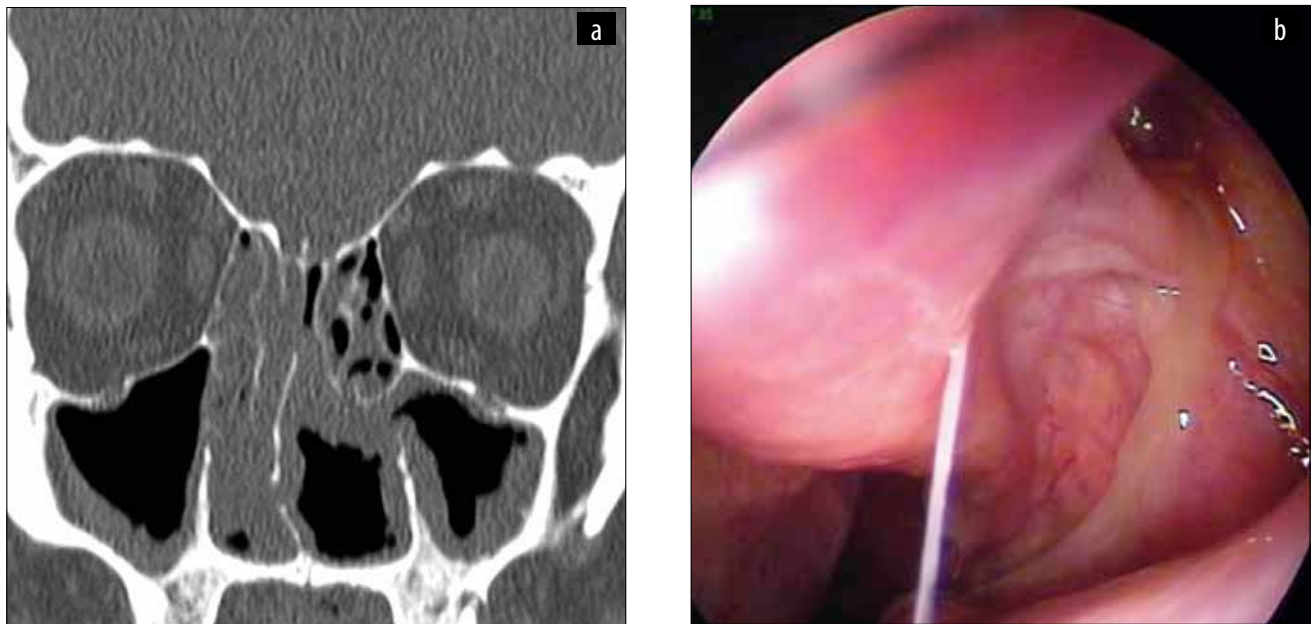


Figure 6 Incomplete ethmoidectomy – a. Cranio-facial CT scan, coronal slice; b. Nasal endoscopic examination – adherent secretion running out from the left middle meatus.

As soon as the revision endoscopic sinus surgery was decided, a proper preparation of the nasal fossa (inflammation, infection) is required: antibiotics according to the cultures and antibiogram, systemic steroids for special conditions (asthma, nasal polyposis) and the surgical planning depending on the previous operation. The access to the operative field should be taken into account. The procedure should include the following steps: revision middle meatal antrostomy, the ethmoidal revision surgery (Figure 6), the sphenoid revision surgery and, finally, if it is mandatory, the revision frontal sinus surgery, which is the most difficult.

The navigation system is very useful during revision surgery, when a lot of landmarks are missing or replaced by scars or fibrous tissue. The device helps us to plan the surgical procedure, to analyze the remnants during the surgery and, most important, to avoid serious complications.

Most authors agree that there are six friendly landmarks to be used during the revision cases:

1. the *anterior arch* (the remnant of the middle turbinate medially, the anterior ethmoids and agger nasi cells superiorly and anterolaterally, and the lamina papyracea laterally),
2. *lamina papyracea*,
3. the *maxillary antrostomy*,
4. the *ridge* formed by the border between the superior aspect of the maxillary antrostomy and the inferior edge of the lamina papyracea (it represents the level of the orbital floor),
5. the *sphenoid sinus (or its anterior wall)*,
6. the *choanal arch*^{2,8}.

We consider that the postoperative medical management after revision endoscopic sinus surgery starts

prior to the surgery. That means a proper patient selection and disease staging, the preoperative CT checklist (in 2 or 3 planes), the correct planning of the procedure and the patient's preparation for surgery (mucosal decongestion, preoperative medication, patient awareness and consent - detailed instructions about the disease and its management, description of endoscopic sinus surgery and expectations).

During surgery, there are some important aspects to keep in mind that could be summarized in a “**4 must of the revision cases**”²:

- Be as less aggressive as possible!
- Manage your complications intraoperatively!
- Do not overlook your possible mistakes!
- Be aware of your limits and limitations!

After the sinus surgery, most of the authors agree that, if it is possible, it's better not to pack the nose⁹. Also, most sinus surgeons advocate for careful, but sustained, debridement of the cavities 7-10 days after the surgery. These manoeuvres may decrease the rate of adhesions and synechia, but could be time-consuming, painful and if bleeding appears the risk of delay wound healing is increased¹⁰. A recent statement of the American Rhinologic Society maintains that four postoperative debridements in a 6-week period for routine FESS patients is reasonable and 6 times in the revision cases is fair².

The saline nasal lavage performed postoperatively remains crucial because it keeps the healing mucosa clean, moist and facilitates the aeration of the sinus cavities¹¹.

Intranasal corticosteroids, part of the preoperative maximal medical treatment, are given postoperatively too, because it appears that they do not suppress only

the inflammation, but also are capable of reducing the rate of bacterial colonisation.

Oral corticosteroids are often used for both allergic rhinitis patients, chronic rhinosinusitis with or without nasal polyps and postoperative mucosal edema¹². This is why another important aspect, mainly in revision cases, is the reduction of the postoperative oral steroids too quickly and allowing regrowth of the polyps in the surgical healing phase.

Regarding the use of antibiotic therapy in revision endoscopic surgery cases, it is well known that *Staphylococcus Aureus* colonizes chronic rhinosinusitis and postoperative patients and may play a role in progression of the mucosal inflammation. As antibiotic resistance is increasing, we usually obtain cultures and antibiograms prior to the reintervention; we recommend a maximal antibiotic therapy prior to the surgical procedure according to the antibiogram results (14 days or more) and then just perioperative antibiotics. There are authors advocating for topical delivery of antibiotics, but criticism is related to the concentration of the active substance in the solution.

The efficacy of topical antifungal medications for any type of chronic rhinosinusitis is currently unproven.

If after sinus surgery, mucociliary function is restored after 6-12 weeks, in revision cases, this interval is sometimes prolonged.

Because patients with nasal polyps are frequently associated with a higher rate of surgical failures, more vigilant surveillance and adjustments to medical therapy are required¹³.

CONCLUSIONS

In patients with rhinosinusitis symptoms and CT signs of disease, the extent of the mucosal changes might not correlate with the extent of their symptoms. CT scan has also been shown not to correlate with surgical findings, especially in revision patients.

Staging of those cases indicated for revision surgery should take into account the symptoms, the endoscopic score and histopathologic score.

The most difficult revision cases are in patients with associated comorbidities (immunodeficiency, cystic fibrosis, asthma, etc.), aggressive previous surgery with loss of usual landmarks and several previous surgeries (external and/or endoscopic approach).

Historically, success with ESS has been categorized as marked improvement in symptoms or according to patient's satisfaction with surgery.

And most important operate patients to relief symptoms, do not operate CT scans!

REFERENCES

1. Fokkens W. et al - European position paper on rhinosinusitis and nasal polyps 2012. A summary for otorhinolaryngologists, *Rhinology.*, 2012 Mar;50(1):1-12.
2. Passali D., Sarafoleanu C., Bellussi L.M., Kern E.B., Popescu F.D. – Rhinosinusal inflammation and infections: modern thinking and current treatment. Editura Academiei Romane, Bucuresti, 2013.
3. Kountakis S. - Revision endoscopic sinus surgery. Springer, 2008.
4. Kennedy D.W. - Prognostic factors, outcomes and staging in ethmoid sinus surgery, *Laryngoscope*, 1992;102:1-18.
5. Jiang R.S., Hsu C.Y. - Revision functional endoscopic sinus surgery. *Annals of Otolaryngology and Rhinology.*, 2000;111:155-9.
6. King J.M., Caldarelli D.D., Pigatto J.B. - A review of revision functional endoscopic sinus surgery. *Laryngoscope*, 1994;104:404-408.
7. Levine H.L. - Functional endoscopic sinus surgery: evaluation, surgery and follow-up of 250 patients. *Laryngoscope*, 1990;100:79-84.
8. Musy P.Y., Kountakis S.E. - Anatomic findings in patients undergoing revision endoscopic sinus surgery. *Am J Otolaryngol.* 2004;25:418-425.
9. Manea C., Sabaru I., Sanda C. - Nasal packing in endonasal surgery - a literature review. *Romanian Journal of Rhinology*, 2011;1(4):
10. Bugten V., Nordgard S., Stensvag S. - The effects of debridement after endoscopic sinus surgery. *Laryngoscope*, 2006;116:2037-2043.
11. Gross C.W., Gross W.E. - Postoperative care for functional endoscopic sinus surgery. *Ear Nose Throat*, 1994;73:476-479.
12. Mabry R. - Corticosteroids in rhinology. In: Goldman J.L., Blaugrund S.M., Shugar J.M.A. (eds) - *The principles and practice of rhinology*. John Wiley, New York, 1987;p.847-853.
13. Sarafoleanu C., Enache R., Lupoi D. - Quality of life after rhinologic surgery. *Romanian Journal of Rhinology*, 2011;1(1):