

LITERATURE REVIEW

Sinus barotrauma - a particular injury

Irina Predescu

ENT&HNS Department, "Sfanta Maria" Hospital, "Carol Davila" University of Medicine and Pharmacy, Bucharest, Romania

ABSTRACT

Sinus barotrauma is the disorder arising from the pressure variations of the ambient. This is the consequence of a pressure difference between the nasal fossae and one or more sinus cavities in the context of sinus impermeability, the most often involved sinus being the frontal sinus. The barotrauma may occur during aeronautical activities, when there is low atmospheric pressure, or while diving, when there is an increased atmospheric pressure. Correct treatment and a good prevention spare the patient from severe lesions, minimizing the risk of recurrence, and make possible the professional integration as soon as possible.

The author presents the physiopathology of this disease and the proper investigations and treatment methods.

KEYWORDS: sinus barotrauma, diving, aeronautical activities, atmospheric pressure

INTRODUCTION

Since water and aeronautical sports are practiced increasingly more, it is necessary to know the physiopathogenic mechanisms that occur in the sinuses in these extreme conditions and to initiate an appropriate treatment in the case of malfunctions.

Sinus barotrauma is the disorder arising from the pressure variations of the ambient. This is the consequence of a pressure difference between the nasal fossae and one or more sinus cavities in the context of sinus impermeability, the most often involved sinus being the frontal sinus. The barotrauma may occur during aeronautical activities, when there is low atmospheric pressure, or while diving, when there is an increased atmospheric pressure.

PHYSIOPATHOLOGY OF BAROTRAUMA

The pathology of the sinus barotrauma is strictly related to 3 laws of physics: Boyle-Mariotte law, Dalton's law and Henry's law.

Boyle-Mariotte law or the isothermal transformation law states that, at constant temperature, the volume of a gas varies inversely with increasing pressure.

Thus, while diving, pressure increases rapidly, by 1 bar for every 10 metres; according to the law described above, the gas volume reduces (if there are 1000 l at 0 m, at 10 m there will be a pressure of 2 bar and a gas volume of 500 l) and inversely, in case of return from immersion to the surface, the pressure decreases and volume increases (for example, if we have an air-filled balloon, it has 1 l at 10 m depth and, when we return to the surface, its volume will be of 2 l). An inverse mechanism occurs with increasing altitude, when the atmospheric pressure decreases by 0.1 bar for every 1000 m up to 5000 m, therefore, at 5000 m, the pressure will be 0.5 bar.

Dalton's law or the law of partial pressures states that, at constant temperature, the pressure of a gas mixture is equal to the sum of the partial pressures of its component pure gases. The air used in the oxygen tanks for immersion is made up of several components, but, with the exception of O₂ and N₂, the amount of the other gases is less than 1%, so that it is considered that air is a mixture of O₂ and N₂, consisting of 21% O₂ and 79% N₂ (so there is 0.21 O₂ and 0.79 N₂ - volume participation). As a consequence, for example at a pressure of 5 bar, there will be the O₂ pressure of 0.21 x 5 = 1.05 bar, and the N₂ pressure 0.79 x 5 = 3.95 bar.

Henry's law states that, at constant temperature, the mass of gas dissolved in a saturated liquid varies directly with the partial pressure of the gas in contact with the liquid, so that, in a mixture of gases such as the air breathed by divers, the amount of dissolved gas will be directly proportional to the partial pressure of each gas composing the mixture.

A series of specific anatomical factors make possible the appearance of this type of lesion. The face sinuses are pneumatic cavities, enclosed in bony walls, so the volume cannot vary; consequently, while descending, a relative depression is installed between the sinus and the nasal fossae, whereas in the case of ascension, there is a relative hyperpressure. The barotrauma especially occurs in cases of rapid variations of pressure and usually installs in the frontal sinus (68%), followed by the ethmoid sinus (16%), the maxillary (8%) and, more rarely, in the sphenoid sinus¹⁻³. This distribution is explained by the drainage anatomical features. Since the sinuses are lined with a respiratory-type mucosa, they require drainage in the nasal passages, which is carried out differently, through the ostium for the maxillary and sphenoid sinus, and through the frontonasal duct for the frontal sinus (the ostium of the sphenoid sinus is short – 2-4 mm, the ostium of the maxillary sinus measures 5-8 mm, and the frontonasal duct is longer – 15-20 mm, independent of the sinus size, most of the times

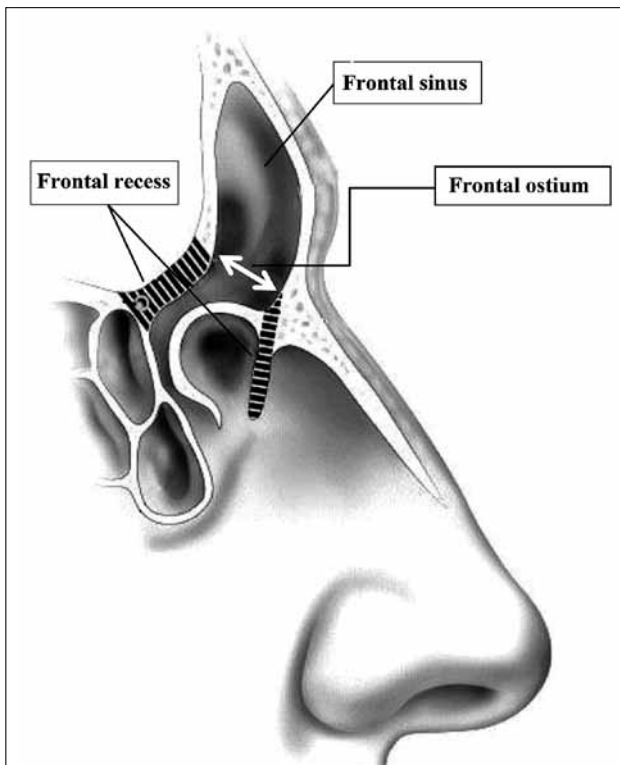


Figure 1 Sagittal section – frontal sinus highlighting the frontonasal duct (drawing).

sinuous, in a narrow anterior ethmoid) (Figure 1). Therefore, it becomes clear why the frontal sinus holds supremacy of the lesion interest, a consequence of the considerable increased length of the frontonasal duct as compared to the other two sinus cavities. If the ostium permeability is compromised, the sinuses are isolated and we have the necessary conditions to achieve a sinus barotrauma⁴⁻⁷.

In diving conditions, when pressure increases, an ostial edema or a meatal obstruction may alter pressure balance, aggravating the relative depression in relation to the atmospheric pressure and “*a vacuo*” lesions may occur (*the implosive form*)⁸.

Depending on the relationship of proportionality difference of pressure/lesional grade, there are described different stages of lesion interest⁸:

- for depression from 100-150 mmHg – edema and mucosal hyperemia through plasma extravasation-ultrafiltration;
- between 150-300 mmHg – seromucous or serohematic effusion, through the transcapillary passage of the figurative elements;
- more than 300 mmHg – interstitial hemorrhage, then submucous, even intracavitary, which can lead to hemosinus.

Moreover, a number of conditions are favourable for ostium impermeability:

- sea water temperature – for example, a temperature below 18° C is responsible for a reduction of ciliary movement;
- head position - for example, an inclined position at the time of plunging favors venous congestion;
- the degree of hypertonia of sea water – an increased hypertonia can trigger a ciliary hypokinesia.

On the other hand, we may encounter the reverse lesional mechanism; when returning to the surface, sinus pressure is increased in the absence of equipressure, especially when there is an intrasinus obstacle (polyp) which hinders air discharge - *the explosive form* (Figure 2).

Barotraumas occur in 70% of cases while diving and in 30% of the cases while returning to the surface⁹

Although sinus barotrauma occurs less frequently than those of the middle ear (three times less common), their occurrence is not negligible¹⁰; most often, they are underestimated. According to Taylor¹¹, on a group of 709 divers observed for a period of 1 year, it was observed that 53% of them suffered a barotrauma of the middle ear, 37% of the sinuses and 10% of the teeth.

In a study¹² conducted on pilots of the commercial airlines, who suffered an ordinary acute rhinitis during the flight, the ratio was 72% ear barotrauma versus 28% sinus barotrauma, the majority occurring during landing.

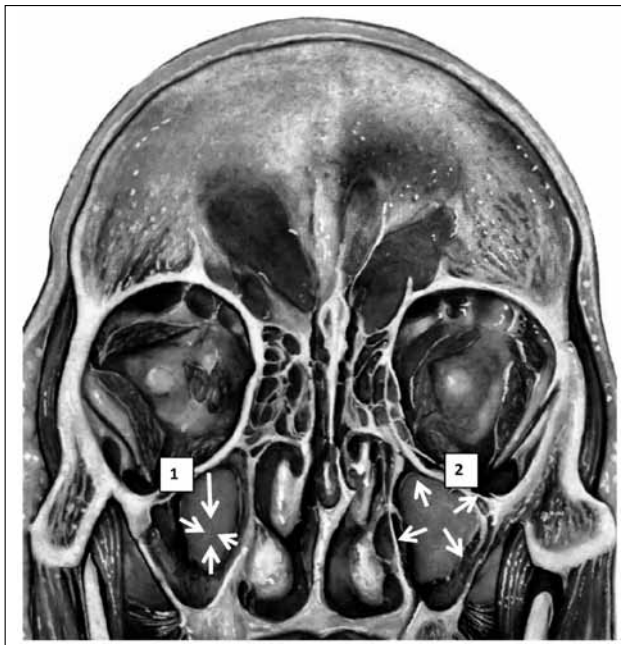


Figure 2 Types of barotrauma lesions (drawing): 1. Implosive form; 2. Explosive form.

Predisposing factors

The causes for ostium impermeability are numerous, acute or chronic: polyps, mucous cysts, tumors, septal deformities, concha bullosa, all mucosal hyperplasia during inflammatory or allergic rhinosinusitis, etc. Note that in smokers ostium permeability is reduced on average by 30%.

SYMPTOMS

Cephalalgia is the main symptom, of variable intensity, from simple discomfort to intense pain, even syncope, especially in explosive forms. It is localized in the area of the involved sinus:

- the frontal sinus - pain can be supra- or retro-orbital;
- the maxillary sinus - pain may be suborbital or frontal;
- rarely, when the sphenoid sinus is involved, occipital pain or in the vertex.

Pain intensity varies, depending on the degree of barotrauma. Thus, Weissman^{2,8,13,14} describes 3 degrees of barotrauma:

- 1st degree - moderate sinus discomfort, with edema of the mucosa and no visible changes on the X-ray;
- 2nd degree - severe pain that has lasted for about 24 hours, with changes on the X-ray (thickening of the mucosa);
- 3rd degree - severe pain that has lasted for about 24 hours, with important changes on the X-ray,

thickening of the mucosa or opacification of the affected sinus and/or submucosal hemorrhage, blood exuding, epistaxis.

A particular situation is described in the case of divers, while returning to the surface, when intrasinus pressure is increased - the explosive form, because pain can be syncope and may threaten the diver's life (same situation in the case of an airplane pilot who should avoid rapid ascension)^{2,14-18}.

Epistaxis is another common symptom, which may occur in 58% of cases¹⁹, but, usually, it is not severe and occurs in the implosive forms.

Symptomatic clinical forms are rare and occur especially in explosive forms:

- *hypoesthesia* in the infraorbital nerve territory²⁰⁻²³, the relative hyperpressure that develops in the maxillary sinus can cause reversible lesions of the infraorbital nerve in the infraorbital canal, especially if there is a dehiscence at this level, which disappears in less than 48 hours;
- exceptional rupture of the sinus wall, which may occur at the level of a dehiscence and may be spontaneous, posttraumatic or consecutive to sinus surgery; it can take the form of a *subcutaneous emphysema*, supra- or suborbital, of a *pneumo-orbit* or of a *pneumocephaly*, with or without associated meningo-encephalic infectious complications²⁴.

Associated forms. In 20% of the cases, it can associate a barotrauma of the middle ear¹⁰.

PARACLINICAL EXAMINATION

If symptoms are moderate and if it is the first episode, it is not necessary to perform other tests. Nevertheless, if the pain was intense and especially if the patient has a recurrent barotrauma, it is necessary to perform a *CT scan of the sinuses* to look for the triggering cause (concha bullosa, abnormally developed unciform cells, sinus opacity, etc.), as well as an *endoscopic examination*, with and without vasoconstrictor. In case of chronic nasal obstruction, *rhinomanometry* is of particular interest (if the CT scan of the sinuses is without abnormalities, one may suggest to the patient a septoplasty or a turbinoplasty surgery). If the balance is negative, the patient is proposed an *allergological investigation*⁸.

The old standards recommending X-ray of the anterior sinuses (Blondeau incidence) have lost ground to current imaging methods (Figure 3, Figure 4). Consequently, standard radiology remains a method of exception for low severity cases, especially for differential diagnosis or during an ordinary, nonspecific investigation phase.

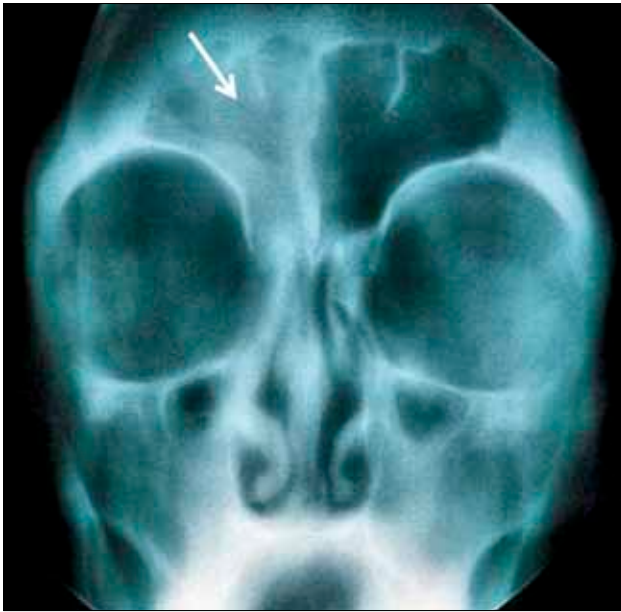

Figure 3 Standard radiology image, Blondeau incidence. Characteristic appearance of frontal sinusitis (ENT Department property).

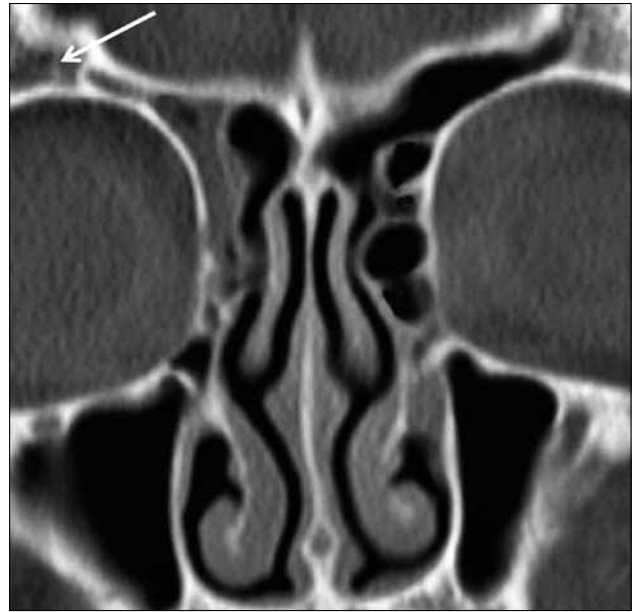


Figure 4 CT scan examination, coronal section - frontal sinusitis (ENT Department property).

DIFFERENTIAL DIAGNOSIS

In most cases, usually with minor injuries, symptoms and clinical aspects are superimposed or confounding with other ENT or dental diseases. For example, rather frequently, one may call into question a barotraumatic odontalgia, particularly while ascending to the surface, when there is either an incomplete ductal treatment or a recurrence of dental caries. In addition, facial algiae can appear (migraines, facial neuralgia, vascular algiae)²⁵, which can be soothed by oxygen inhalation or can be prevented by ergot derivatives. Epistaxis is not rare, by rupture of vessels in the septum or in the vascular patch, when there is low pressure at the level of the diving mask (in order to avoid it, the diver should breathe air from the mask through the nose); it may be associated with a subconjunctival hemorrhage or a periorbital ecchymosis.

TREATMENT

An essential component of treatment is prevention²⁶.

It is necessary to inform patients who perform an activity with risk of barotrauma to avoid these activities under the conditions of infection of the upper airways or of another pathology which may have consequences for the sinus. However, the rules in force for diving or aeronautical activities state an absolute contraindication for these activities under the conditions of a sinus pathology which may compromise the pressure balance²⁷.

It is good to use decongestants before these activities?

Nasal or general decongestants are meant to prevent the occurrence of barotrauma, especially when diving, which is less severe, but can cause barotrauma while returning to the surface, which can be dangerous particularly by the syncopal character of pain. That is why their use is prohibited, at least 12 hours before diving²⁸. The same cannot be said about the commercial flight crew. They can use an oral decongestant before the flight and a nasal vasoconstrictor before landing²⁹.

For the leisure diving activity, it is contraindicated when we have chronic sinus pathology with ostium dysfunction (the data from the literature mention a relative contraindication in people with nasal polyposis).

If we have an isolated episode of sinus barotrauma, it occurs most commonly during an acute rhinitis and then treatment is symptomatic (the background treatment of rhinitis and antialgic treatment)³. When the cephalalgia is very intense, especially that which occurs while returning to the surface, if it does not succumb to the usual painkillers, it is necessary to restore sinus permeability in order to achieve pressure equalization (older techniques, such as frontal sinus trepanation and installing a drain of Lemoyne type or, more rarely, maxillary sinus puncture with the installation of an Albertini drain, or newer, endoscopic techniques). Also, one may prescribe local or general decongestants, aerosols, antibiotics per os (preferred antibiotics are those of the amoxicillin type - clavulanic acid or second-generation cephalosporin) – in case of associated purulent rhinorrhea. Corticosteroids per os are widely used, especially to reduce the edema responsible for the ostium dysfunction.

In case of recurrent episodes, it is necessary to investigate the cause. To do this, a complete clinical and radiological balance is performed, as well as an endoscopic nasosinusal balance, a CT scan of the sinuses, a rhinomanometry examination.

If the sinus CT scan is normal:

- the chronic rhinitis is treated with drugs – nasal lavage with physiological serum, intranasal corticosteroid, antihistamines;
- the turbinate hypertrophy which has not been improved by medication can be reduced by various methods: Laser, radiofrequency, cautery;
- structural abnormalities can be surgically treated (septoplasty, concha bullosa, turbinectomy).

If the sinus CT scan reveals chronic rhinosinusal pathology medical treatment with an intranasal corticosteroid is carried out. In case of functional failure, the surgical treatment is recommended – for example, middle meatotomy for the maxillary sinus, for the frontal sinus – re-permeabilization of the naso-frontal duct; in case of unilateral ethmoid-frontal pathology, it is envisaged anterior ethmoidectomy and re-permeabilization of the frontal sinus. For the re-permeabilization of the frontal sinus, newer techniques suppose the installation of a balloon catheter sinuplasty³⁰, especially for the pathology limited to the naso-frontal duct (dilation of the frontonasal duct by installation of a ballonet, after locating the sinus ostium by means of a catheter guided by fluoroscopy or by transillumination)³¹ (Figure 5). This new technique gives compara-

ble results to conventional surgery, but failures have also been reported³²⁻³⁵.

In case of bilateral nasal polyposis, polypectomy and middle meatotomy are proposed, and in case of failure, bilateral ethmoidectomy with sphenoidotomy.

A good medical treatment allows recovery and resumption of activity in most of the cases (50%)³⁶. In case of failure of the medical treatment, surgical treatment provides a better rate of recovery (92% according to Parson)³⁷. These data are valid especially for the flying personnel; for those who perform diving, the environment being more hostile than for professional pilots, results are less good.

MEDICO-LEGAL ASPECTS

For professional divers, the activity is contraindicated when there is chronic sinus pathology with ostium dysfunction, particularly if they had had a history of sinus barotrauma.

Military standards for the aviation flight crew impose: nasal fossae must be permeable; septal deviations, turbinate hypertrophy, acute or chronic infections of the upper airways constitute grounds for temporary or permanent incapacitation, until resolution of the cause.

Civil standards for the aviation flight crew are the same, with limitation of the activity until proper functioning of the sinuses.

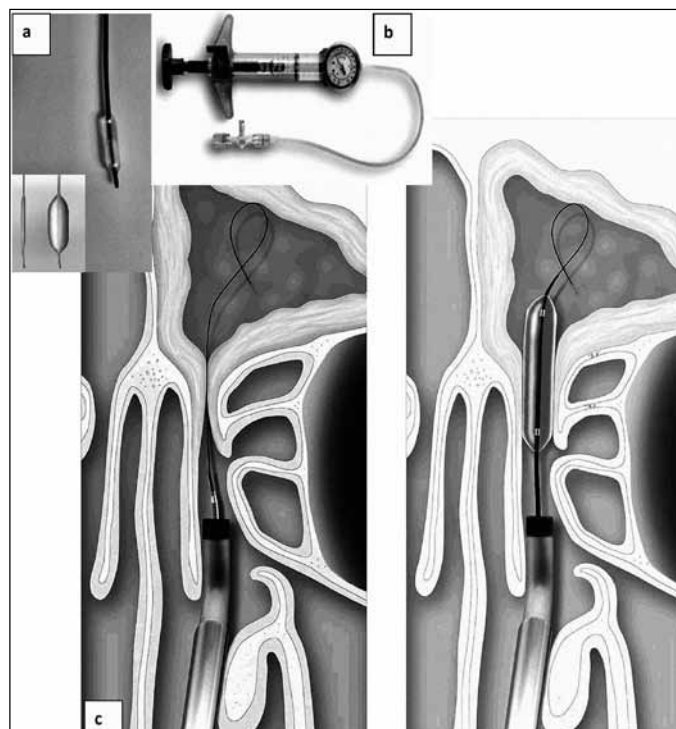


Figure 5 Surgical technique. a and b) Instruments for sinuplasty – balloon catheter and pump for ostium permeabilization; c) detail of the technique – dilation of the naso-frontal duct.

For those belonging to the groups with occupational risk, it is worth mentioning the impact on the resumption of activity in safety conditions. Therefore, in case of accidental 1st degree barotrauma, a cessation of activity for a week is necessary, while for the 2nd and 3rd degree ones, a cessation for a month, with tomographic control of the sinus integrity⁸.

CONCLUSIONS

In conclusion, barotrauma is a lesion more common than suspected, especially in the conditions of sports, professional and recreational activities, which are practiced increasingly more. Basically, the practitioner will encounter two distinct situations involving a therapeutic amendment. Sinus barotrauma occurring accidentally and which, usually, implies a clinical diagnosis without requiring additional investigation for diagnostic purposes. From a therapeutic point of view, it requires short-duration treatment. However, a particular problem is raised by the recurrent barotrauma, often imposing a clinical investigation, endoscopy and computerized tomography in order to detect the triggering cause and treat it accordingly. For the recurrent ones, it is required to treat the cause and then perform the CT verification.

Correct treatment and a good prevention spare the patient from severe lesions, minimizing the risk of recurrence, and make possible the professional integration as soon as possible.

REFERENCES

- Bourolias C., Gkotsis A. - Sphenoid sinus barotrauma after free diving. *Am J Otolaryngol.*, 2011;32:159-61.
- Weissman B., Green R.S., Roberts P.T. - Frontal sinus barotrauma. *Laryngoscope*, 1972;82(12):2160-8.
- Becker G.D., Parel G.J. - Barotrauma of the ears and sinuses after scuba. *Eur Arch Otolaryngol.*, 2001;258:159-63.
- US Navy Diving Manual. 6th revision. United States: US Naval Sea Systems Command. 2006. Retrieved 2008-07-19.
- Brubakk A.O., Neuman T.S. - Bennett and Elliott's physiology and medicine of diving, 5th Rev ed. United States: Saunders Ltd., 2003;p.800.
- Dehart R.L., Davis J.R. - Fundamentals Of Aerospace Medicine: Translating Research Into Clinical Applications, 3rd Rev Ed. United States: Lippincott Williams And Wilkins, 2002;p.720.
- Fitzpatrick D.T., Franck B.A., Mason K.T., Shannon S.G. (1999). Risk factors for symptomatic otic and sinus barotrauma in multiplace hyperbaric chambers. *Undersea Hyperb Med.*, 1999;26(4):243-7. Retrieved 2008-07-19.
- Verdalle P., Morvan J.B. - Barotraumatismes sinusiens. *EMC, Elsevier Masson, Issy-les-Moulineaux, Oto-rhino-laryngologie*, 2013;8(1) (art 20-466-A-10).
- Uzum C. - Paranasal sinus barotrauma in sports self contained underwater breathing apparatus divers. *J Laryngol Otol.*, 2009;123:80-4.
- Broussolle B., Meliet J.L., Coulange M. - Physiologie et Medecine de la plongee. Paris: Ellipses, 2006.
- Taylor D.M., O'Toole K.S., Ryan C.M. - Experienced scuba divers in Australia and the United States suffer considerable injury and morbidity. *Wild Environ Med.*, 2003;14:83-8.
- Rosznkvits L., Klopper M., Katholm M. - Upper respiratory infections and barotrauma in commercial pilots: a retrospective survey. *Aviat Space Environ Med.*, 2008;70:960-3.
- Green R.S., Weissman B. - Frontal sinus hematomas in aerospace medicine. *Aerosp Med.*, 1973;44(2):205-9.
- Campbell P.A. - Aerosinusitis. *Arch Otolaryngol.*, 1942;35:107-114.
- Fagan P., McKenzie B., Edmonds C. - Sinus barotrauma in divers. *Ann Otol Rhinol Laryngol.*, 1976;85:61-4.
- Fitzpatrick D.T., Franck B.A., Mason K.T., Shannon S.G. - Risk factors for symptomatic otic and sinus barotrauma in a multiplace hyperbaric chamber. *Undersea Hyperb Med.*, 1999;26:243-7.
- Salvinelli F., Rinaldi V., D'Ascanio L. - Paranasal sinus barotrauma in general anesthesia: special attention. *J Clin Anest.*, 2005;17:323.
- Weitzel E.K., McMains K.C., Rajapaksa S., Wormald P.J. (January 2008). Aerosinusitis: pathophysiology, prophylaxis and management in passengers and aircrew. *Aviat Space Environ Med.*, 2008;79(1):50-3. Retrieved 2008-07-19.
- Hunter S.E., Farmer J.C. - Ear and sinus problems in diving. In: Bove A.A., Davis J.C., editors - *Diving Medicine*. Philadelphia: WB Saunders, 2004;p.431-59
- Butler F.K., Bove A.A. - Infraorbital hypesthesia after maxillary sinus barotrauma. *Undersea Hyperb Med.*, 1999; 6:257-9.
- Zadik Y., Chapnik L., Goldstein L. - In flight barodontalgia: analysis of 29 cases in military aircrew. *Aviat Space Environ Med.*, 2007;78(6):593-6. Retrieved 2008-07-16.
- Zadik Y. - Barodontalgia. *J Endod.*, 2009;35(4):481-5. Retrieved 2009-06-01.
- Zadik Y. - Aviation dentistry current concepts and practice. *British Dental Journal*, 2009;206(1):11-6. Retrieved 2009-01-26.
- Parel G., Becker G. - Neurological consequences of scuba diving with chronic sinusitis. *Laryngoscope*, 2000;110:1358-60.
- Zhao JM, Schaaning J, Sjaastad O. Cluster headache: the effect of low oxygen saturation. *Headache* 1999;30:656-9.
- Roydhouse N. - The squeeze, the ear and prevention. *South Pacific Underwater Medicine Society Journal*, 1978;8(1). Retrieved 2008-07-19.
- Green R.S., Weissman B. - Frontal sinus hematomas in aerospace medicine. *Aerosp Med.*, 1973;44(2):205-9.
- Klingmann C., Baumann I., Bruckner T., Praetorius M., Plinkert P.K. - Otolaryngological disorders and divers accidents: an analysis of 306 divers. *Eur Arch Otolaryngol.*, 2007;264:1243-51.
- Weitzel E., McMains K., Rajapaksa S., Wormald P. - Aerosinusitis: pathophysiology, prophylaxis and management in passengers and aircrew. *Aviat Space Environ Med.*, 2008;79:50-3.
- Welch K., Stankiewicz J. - Application of minimally invasive endoscopic sinus surgery techniques. *Otolaryngol Clin N Am.*, 2010;43:565-78.
- Bara S., Ryan M., Sindwani R., Marle B. - Balloon catheter technology in rhinology: reviewing the evidence. *Laryngoscope*, 2011;121:226-31.
- Brown C.L., et al. - Safety and Feasibility of Balloon Catheter Dilatation of Paranasal Sinus Ostia: A Preliminary Investigation. *Annals of Otolaryngology et Laryngology*, 2006;115(4):293-299.
- Bolger W.E., et al - Catheter Based Dilatation of the sinus Ostia: Initial Safety and Feasibility Analysis in a Cadaver Model. *American Journal of Rhynology*, 2006;20(3):290-294.
- Karanfilov B., et al. - Office-based balloon sinus dilatation; a prospective, multicenter study of 203 patients. *Int Forum Allergy Rhinol.*, 2013;3:404-411.
- Weiss R.L., et al - Long-term outcome analysis of balloon catheter sinusotomy: two-year follow up. *Otolaryngol Head Neck Surg.*, 2008;139:S38-S46.
- Skevas T., Baumann I., Bruckner T., Clifton N., Plinkert P.K., Klingmann C. - Medical and surgical treatment in divers with chronic rhinosinusitis and paranasal sinus barotrauma. *Eur Arch Otolaryngol.*, 2012;269:853-60.
- Parsons D.S., Chambers D.W., Boyd E.M. - Long term follow-up of aviators after functional endoscopic sinus surgery for sinus barotrauma. *Aviat Space Environ Med.*, 1997;68:1029-34.