

CASE REPORT

An unusual combined parotideal and neck abscess - Case report

Ricardo de Hoyos¹, Michele Loglisci², Hugo Anibal Rodriguez³, Desiderio Passali²

¹ENT Department, Hospital Zambrano Hellion Tec Salud, San Pedro Garza García, Nuevo León, México

²ENT Department, University of Siena, Siena, Italy

³Department of Otorhinolaryngology, Hospital de Pediatría S.A.M.I.C. "Prof. Dr. Juan P. Garrahan", Buenos Aires, Argentina

ABSTRACT

Cervical and parotideal abscess is a rare finding in all populations and even more so in the paediatric population. The antibiotic resistance of the bacteria that cause these diseases can make it very dangerous. We present a paediatric case in which there is a combined left-cervical and parotideal abscess in a female 3-month-old baby who presented fever, pain and cervical swelling.

KEYWORDS: cervical abscess, parotideal abscess, paediatric otorhinolaryngology, cervical surgery

INTRODUCTION

Combined abscesses in the paediatric population are relatively uncommon. However, they carry the potential for serious morbidity and mortality. Life threatening complications can develop rapidly and include airway compromise, dissemination of infection and spread into contiguous potential spaces that communicate with the mediastinum¹⁻⁵.

An early diagnosis followed by appropriate treatment is crucial. Predominant clinical features include trismus, dysphagia, neck pain, torticollis, painful neck mass, odynophagia, irritability and fever.

Acute neck swellings in the paediatric population are often treated with antibiotics, proceeding to incision and drainage if an abscess is suspected. A variety of investigations are available and the causative organism can vary.

A retrospective study analysing trends in microbiology, antibiotic sensitivity, clinical evaluation and management of a child presenting with an acute cervical abscess of four-week duration or less was performed. The role of investigations and the available treatment options are discussed.

CASE REPORT

A 3-month-old baby came to our hospital with fever for 3 days, volume increased and redness of the left

side of her neck. This mass had quickly increased in size over a period of 24 hours. Despite antibiotic therapy with cephalosporin (that was started when fever began), she did not show any improvement. She showed temperature of 39° C, pulse rate of 157 beats per minute; respiratory rate of 26 breaths per minute and oxygen saturation of 97% on room air. The laboratory work-up performed before admission revealed polymorphonuclear neutrophils: $18 \times 10^9/L$, the erythrocyte sedimentation rate was 96 mm/hour and C-reactive protein was 200 mg/L. Physical examination on admission revealed a very large, painful, fluctuating, inflammatory mass on the mandibular angle and upper part of the left side of her neck (Figure 1).

A computed tomography of the neck was performed (Figure 2). It revealed a combined left-cervical and parotideal abscess.

The baby was transferred to the operating room where a needle aspiration was performed under general anaesthesia (Figure 3). It drained more than 10 mL of pus (Figure 4), which was sent for bacteriological examination. Aspiration rapidly relieved the swelling. After that, the surgical treatment was performed (Figure 5).

At the end of surgery, a drainage tube was inserted to facilitate the removal of blood and residual secretions (Figure 6).

The pus drained during surgery was sent to the laboratory and examined. The presence of penicillin-resistant *Staphylococcus aureus* was confirmed. Fortu-

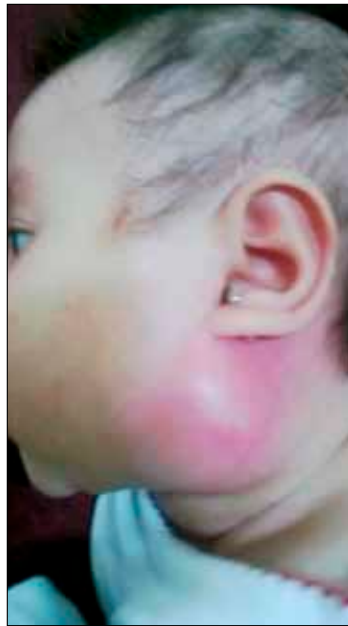

Figure 1 Physical examination

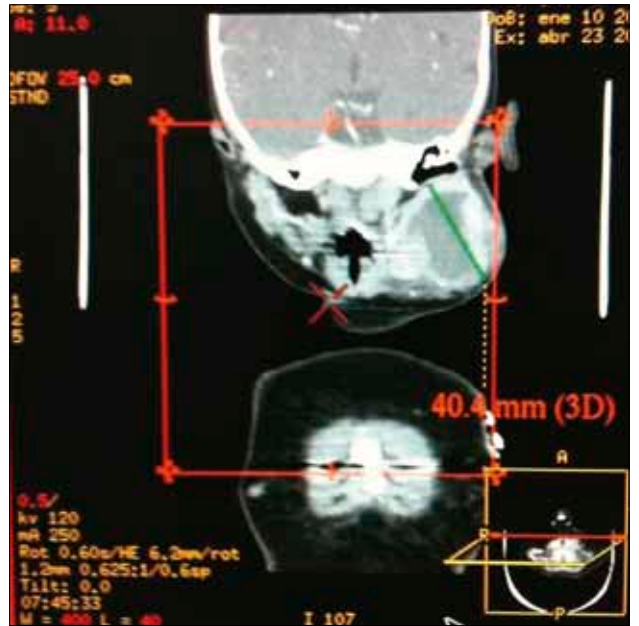


Figure 2 A coronal CT scan showed a 40.4 mm neck abscess

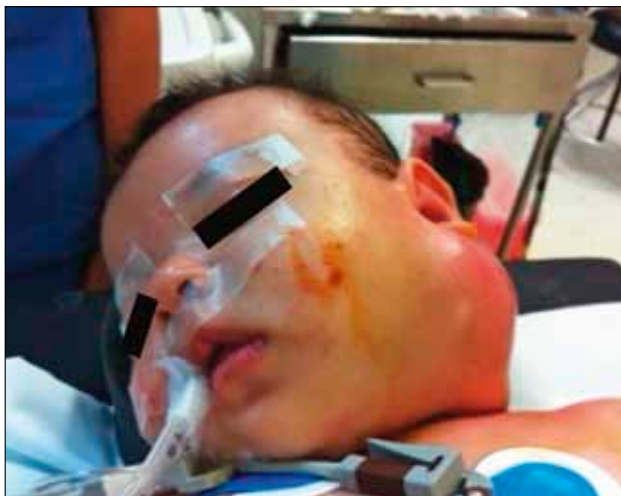

Figure 3 The little baby was intubated for general anaesthesia

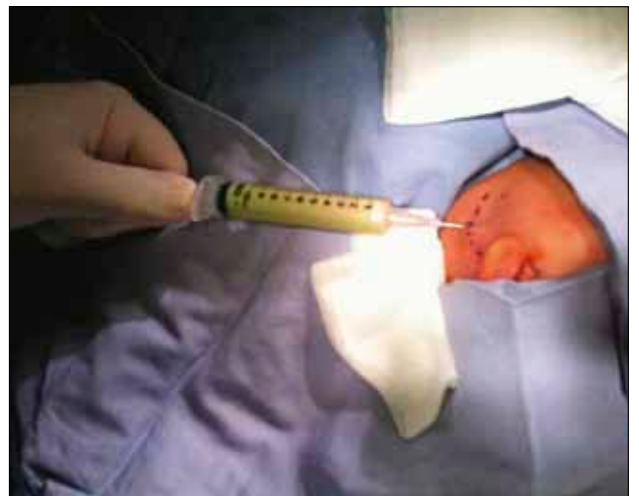


Figure 4 A needle aspiration drained more than 10 mL of pus

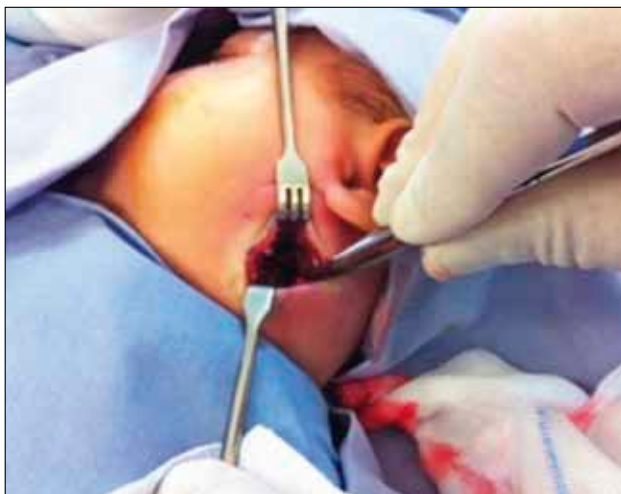

Figure 5 Intraoperative view

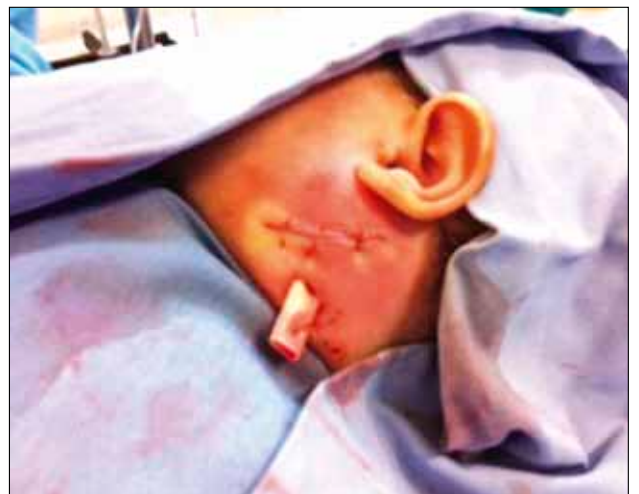

Figure 6 The little baby at the end of the surgery

Sexo:	FEMENINO	Cuarto:	25-A
Médico:		Fecha impresión:	05/05/2014 18:50
Departamento:	CIRUGIA	Hora de toma:	
Orden Lab.:	42321073	Sol. Hosp.:	203704
EXAMEN	RESULTADO	UNIDADES	VALOR DE REFEREN
MICROBIOLOGIA			
CULTIVO ORDINARIO (CUALQUIER SITIO)			
CULTIVO ORDINARIO			
ESECTENES	ABSCESO EN OJELLO		
GRAM	MODERADOS COCOS GRAM POSITIVO		
	ABUNDANTES LEUCOCITOS		
TIEMPO DE INCUBACION	60 HORAS		
DESARROLLO MICROBIANO	PRESENTE		
Staphylococcus aureus			
Antibiótico	MIC (mcg/ml)	INTERPRETACION	
Ciprofloxacina	<=0.5	Sensible	
Clindamicina	<=0.25	Sensible	
Eritromicina	<=0.25	Sensible	
Gentamicina	<=0.5	Sensible	
Levofloxacina	0.25	Sensible	
Linezolid	2	Sensible	
Moxifloxacina	<=0.25	Sensible	
Nitrofurantoina	32	Sensible	
Oxacilina	<=0.25	Sensible	
Penicilina	>=0.5	Resistente	
Ritampicina	<=0.5	Sensible	
Tetraciclina	<=1	Sensible	
Tigeciclina	<=0.12	Sensible	
Trimetoprim / Sulfametoxazol	<=10	Sensible	
Vancomicina	<=0.5	Sensible	
<small>MIC = Concentración mínima inhibidora TR = Inhibitor de betalactamasas R* = Resistencia inducida a betalactamasas de espectro amplio SBR = Betalactamasas de espectro amplio SBR* = Betalactamasas positivas</small>			

Figure 7 The antibiogram result

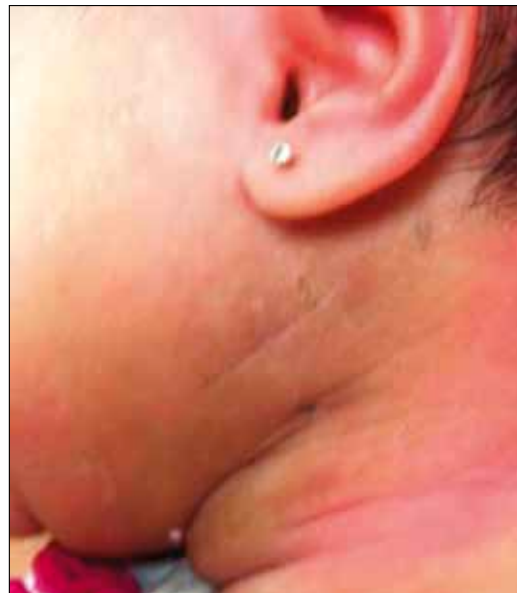

Figure 7 The little baby 2 weeks after the surgery

nately, sensitivity testing showed great sensitivity of the bacterium to the most common antibiotics (Figure 7).

Ten days after surgery the stitches were removed.

The patient had an excellent evolution with complete recovery and all blood tests returned to normality within two weeks after surgery (Figure 8).

CONCLUSIONS

This particular case shows us that this kind of diseases are possible at any age and often the bacteria are multi-drug resistant enough to lead to very dangerous consequences. In such cases, a proper physical examination and a rapid diagnosis through laboratory tests and radiological examinations are essential to bring the patient in the operating room as soon as possible, to drain quickly the abscess, because it can rapidly develop into deep neck or mediastinal abscess.

Conflicts of interests: The authors declare having no conflict of interest.

Contribution of authors: All authors have equally contributed to this work.

REFERENCES

1. Cabrera C.E., Deutsch E.S., Eppes S., Lawless S., Cook S., O'Reilly R.C., Reilly J.S. - Increased incidence of head and neck abscesses in children. *Otolaryngol Head Neck Surg.*, 2007;136(2):176-181.
2. Pelaz A.C., Allende A.V., Llorente Pendas J.L., Nieto C.S. - Conservative treatment of retropharyngeal and parapharyngeal abscess in children. *J Craniofac Surg.*, 2009;20(4):1178-1181. doi: 10.1097/SCS.0b013e3181acde45.
3. Craig F.W., Schunk J.E. - Retropharyngeal abscess in children: clinical presentation, utility of imaging, and current management. *Pediatrics*, 2003;111(6 Pt 1):1394-1398.
4. Raffaldi I., Le Serre D., Garazzino S., Scolfaro C., Bertaina C., Mignone F., Peradotto F., Tavormina P., Tovo P.A. - Diagnosis and management of deep neck infections in children: the experience of an Italian paediatric centre. *J Infect Chemother.*, 2015;21(2):110-113. doi: 10.1016/j.jiac.2014.10.011. Epub 2014 Nov 20.
5. Carbone P.N., Capra G.G., Brigger M.T. - Antibiotic therapy for pediatric deep neck abscesses: a systematic review. *Int J Pediatr Otorhinolaryngol.*, 2012;76(11):1647-1653. doi: 10.1016/j.ijporl.2012.07.038. Epub 2012 Aug 23.