

ORIGINAL STUDY

Diode-laser versus radiofrequency turbinoplasty outcomes in patients with chronic hypertrophic rhinitis

Mihai Saulescu^{1,2}, George Mincu Radulescu^{2,3}, Codrut Sarafoleanu^{2,3}

¹ENT&HNS Department, Sanador Clinical Hospital, Bucharest, Romania

²“Carol Davila” University of Medicine and Pharmacy, Bucharest, Romania

³ENT&HNS Department, “Sfanta Maria” Hospital, Bucharest, Romania

ABSTRACT

BACKGROUND. Chronic rhinitis is defined as the inflammation of the nasal mucosa and it can be characterized by one of the following symptoms: nasal obstruction, sneezing, nasal itching or rhinorrhea. Quality of life studies have demonstrated that the burden of rhinitis is not only sinonasal, but this pathology can be also associated with sleep disturbances, daytime sleepiness, concentration problems or increased irritability. The management strategies for chronic hypertrophic rhinitis include medical and/or surgical therapy.

OBJECTIVE. Subjective evaluation of the impact of radiofrequency and diode laser turbinate reduction upon the quality of life of patients with non-allergic chronic hypertrophic rhinitis.

MATERIAL AND METHODS. The present prospective study was performed on 32 adult patients with chronic hypertrophic rhinitis, who presented no real improvement after three months of medical treatment. In all cases surgery was performed – 22 cases diode-laser turbinoplasty and in 10 cases radiofrequency turbinoplasty. Each surgery type efficacy was evaluated by comparing a visual analogue scale (VAS) filled in by the patients at their first visit and the ones completed at 10 days and 3 months after surgery. The parameters evaluated were: nasal obstruction, rhinorrhea and sneezing.

RESULTS. In the first group, diode-laser turbinoplasty group, 45.46% of the patients pointed a good improvement of the overall symptoms (VAS = 2 -3 points) at 10 days after surgery, while 40% of the radiofrequency turbinoplasty group revealed a good overall improvement of the symptoms. According to the VAS mean values obtained at 10-days and 3 months after surgery most of the patients from both groups experienced great improvement of their symptoms ($p < 0.05$).

CONCLUSION. Clinical benefits obtained with the laser and radiofrequency turbinate reduction are not limited only to nasal obstruction but extending also to other symptoms of chronic rhinitis. Both treatment modalities seem to be well tolerated by the patients and effective in those cases of rhinitis unresponsive to pharmacotherapy.

KEYWORDS: diode-laser turbinoplasty, radiofrequency turbinoplasty, chronic hypertrophic rhinitis.

INTRODUCTION

Chronic rhinitis is defined as “the inflammation of the nasal mucosa and it is characterized by one of the following symptoms: nasal obstruction, sneezing, nasal itching or rhinorrhea”^{1,2}. In the same time the eyes, ears, sinuses and pharynx can also be involved. Studies performed on patient’s quality of life demonstrated that burden of rhinitis is not simply sinonasal, but it may be associated with

sleep disturbances, daytime sleepiness, concentration problems or increased irritability³.

In the literature, there are described different types of chronic rhinitis. The most frequent ones are represented by allergic and non-allergic rhinitis. Nonallergic rhinitis is a distinct disease classification including infectious rhinitis, vasomotor rhinitis, occupational rhinitis, hormonal rhinitis, drug-induced rhinitis or nonallergic rhinitis with eosinophilia syndrome^{4,5}.

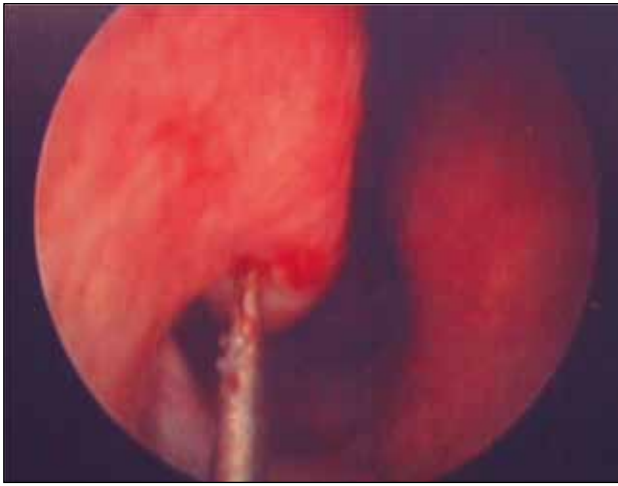


Figure 1 Radiofrequency turbinoplasty

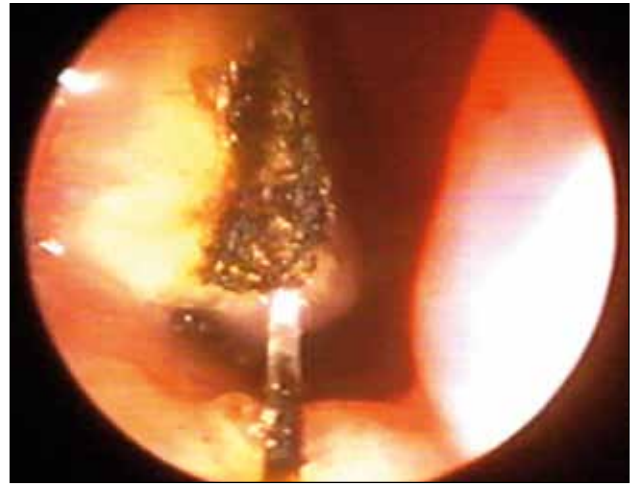


Figure 2 Diode-laser turbinoplasty

Table 1
Patients' demographic data

Number of cases	Males	Females
	23	9
Age	20-60 years	9
Mean age	41.9 years	25-56 years
Age group	< 30 years	5
	30-40 years	4
	40-50 years	7
	50-60 years	7

Although it is not a life-threatening condition, chronic rhinitis can have a great impact upon patients' quality of life^{6,7} and this is why an adequate treatment should be rapidly established.

Inferior turbinate hypertrophy is a frequent cause of nasal obstruction. Medical treatment, such as topical corticosteroid sprays, saline nasal sprays or antihistamines, is usually the first line therapy. However, these treatment modalities may be inadequate in achieving significant resolution of nasal obstruction. Patients whose condition is refractory to medical therapy may seek additional treatment. Surgical reduction

of the hypertrophic inferior turbinate has been advocated after failure of medical therapy⁸.

The surgical techniques usually involve partial or total turbinoplasty. Turbinate reduction is a surgical procedure made to obtain a volumetric reduction of inferior turbinate and thereby decreasing airway resistance and improving nasal breathing.

There have been developed many surgical techniques to reduce the volume of the inferior turbinates. The aim of this study was to evaluate the subjective outcomes in patients with chronic hypertrophic rhinitis after diode laser and radiofrequency turbinoplasty.

MATERIAL AND METHODS

A prospective clinical study was performed on 32 adult patients, aged between 20 and 60 years, with medically refractory nasal obstruction due to chronic hypertrophic rhinitis. 23 patients were males (mean age 41.9 years) and 9 were female (mean age 39.4 years) (Table 1).

All patients included in the study were diagnosed with non-allergic hypertrophic rhinitis. The clinical evaluation consisted in anterior and posterior rhinoscopy, nasal endoscopic examination and imaging evaluation. The previous medical treatment consisted in topic nasal corticosteroids, H₁-antihistamines and systemic anti-inflammatory drugs for at least 3 months.

0	10
Symptoms intensity: Mild: 0-3 cm Moderate: 4-7 cm Severe: 8-10 cm	Overall improvement: No improvement: 1 point Moderate: 2-3 points Good: 4-5 points Excellent: > 6 points

Chart 1 Visual Analogue Scale model evaluation

Table 2
First evaluation parameters intensity

Symptoms	Mild		Moderate		Severe	
	No.	%	No.	%	1	1
Nasal obstruction	-	-	5	15.63	27	84.37
Rhinorrhea	-	-	20	62.5	12	37.5
Sneezing	10	31.25	22	68.75	-	-

Table 3
Overall symptoms improvement according to the type of the surgery 10-days-postoperative

Type of surgery	No improvement		Moderate		Good		Excellent	
	No.	%	No.	%	No.	%	No.	%
DLT	0	0	12	54.54	10	45.46	0	0
RFT	0	0	6	60	4	40	0	0

Study exclusion criteria:

- ✓ pregnancy, cardio-vascular pathology, pulmonary diseases;
- ✓ prior nasal surgery;
- ✓ patients with nasal septal deviation, nasal polypsis, chronic rhinosinusitis, allergic rhinitis;
- ✓ un-cooperative patients.

All patients gave their written informed consent to be included in this study and also for the surgery.

We randomly divided our study patients in two groups:

- 22 patients underwent diode-laser turbinoplasty;
- 10 patients underwent inferior turbinate volume reduction using radiofrequency.

Surgery was made as an outpatient procedure, under local anesthesia. The nasal cavity was sequentially anesthetized, first with lidocaine 10% nasal spray followed by cotton pledget soaked in lidocaine/naphazoline mixture placed in both nostrils for 15 minutes.

Radiofrequency turbinoplasty was performed with Radiofrequency System Celon Ag Olympus, a monopolar electrode. We applied 3 points each nostril, 6 – 10 seconds each at 15W power, in the submucosal area, tale, anterior and middle portion of the inferior turbinate (Figure 1).

The diode -laser turbinate volume reduction was performed with “Velas 60” high power medical diode laser system, a class 4 laser, with a wavelength of 940nm and fiber core diameter of 400µm. Using a continue laser emission at 12W power we performed the vaporization of the entire surface of the inferior turbinate mucosa (Figure 2).

After surgery the nasal cavities were left unpacked. Patients were advised not to blow their nose for 24 hours to prevent a nasal bleeding. Also all patients

were informed to expect approximately 7 – 10 days of increased nasal congestion and rhinorrhea due to intranasal mucosa swelling.

A subjective evaluation of nasal obstruction and associated symptoms (rhinorrhea and sneezing) was done by using a 10-cm visual analogue scale (VAS). The evaluation was performed preoperatory, at 10 days and 3 months after surgery, ranging from 0 (no bothersome) to 10 (very severe symptoms). Improvement was scaled as no improvement – 1 point, moderate 2-3 points, good 4-5 points and excellent more than 6 points (Chart 1).

RESULTS

Patients' evaluation performed at their first medical visit revealed, according to VAS results a severe, nasal obstruction in 84.37% of the cases (27 patients) and a moderate one in 5 patients, representing 15.63%. Regarding the rhinorrhea, severe complaints were related by 12 patients, representing 37.5% (Table 2).

Another parameter evaluated in our study was “sneezing” which was found in 22 patients as being of moderate intensity and mild in 10 patients.

The first evaluation of the patients from both study groups was performed at 10 days after surgery and then after 3 months.

In the first group, diode -laser turbinoplasty (DLT) group, 54.54% of the patients (representing 12 patients) pointed a moderate improvement of the overall symptoms (VAS = 2-3 points) at 10 days after surgery and 10 patients (45.46%) a good one (Table 3). The score from the radiofrequency turbinoplasty

(RFT) group revealed a good overall improvement of the symptoms in 40% of the patients (Chart 2).

The values obtained at 3 months after surgery show that most of the patients from both groups experienced great improvement of their symptoms (Chart 2).

The descriptive statistics of the VAS results for each symptom were evaluated for both groups at 10-days and 3 months after surgery. The preoperative values were almost similar for both groups. The mean visual analogue scale scores for nasal obstruction presented a significant decrease at 3 and 6 months postoperative evaluation comparing to the preoperative status (Table 4, Chart 3).

Regarding the "sneezing" parameter we can see that the mean values for VAS scores preoperatory are almost similar for both groups and its intensity of severity has a statistically significant decrease at 3 months after surgery (Chart 4).

Chart 5 shows that in the RFT group rhinorrhea was more bothersome than in the DLT group, with a VAS mean score higher than the first evaluation. At 3 months after surgery the evaluation revealed a great improvement in both groups, with a significant decrease of VAS mean scores.

DISCUSSIONS

Nasal obstruction due to chronic hypertrophic rhinitis remains one of the most frequent symptoms in rhinology. Even if, there have been developed many surgical techniques to reduce the volume of the inferior turbinates (submucosal diathermy, radical turbinectomy⁹, partial turbinectomy¹⁰, outfracturing¹¹, cryotherapy¹², laser reduction¹³, radiofrequency reduction¹⁴, powered turbinate reduction¹⁵, etc.) the best method is not yet established. The aim of all surgery techniques is

to re-establish the normal nasal airflow, to preserve the nasal physiology and to avoid any complication.

In the present study we compare the efficacy of laser diode and radiofrequency volume reduction of the inferior turbinates. Laser diode reduction uses high power laser beam for vaporization, incision or coagulation of the tissues⁴. The flexible fiber can accurately deliver the beam, in this way producing minimal damage to nearby area. Several studies showed that laser turbinoplasty can be a useful, time saving procedure with very good results and minor side effects¹⁶. Histopathologic studies showed a reduction in the number and function of glandular cells¹⁷, with a decrease of the vessels number and nasal glands^{18,19}. Because of these effects the secretory reflex is changed, the result being a reduction of the rhinorrhea²⁰. Also sneezing, itching or nasal obstruction were found to be reduced after treatment^{16,21}.

We also used radiofrequency (RF) for the volumetric reduction of the inferior turbinate mucosa. It is a method that uses radiofrequency energy to produce submucosal tissue destruction, without damaging the surface²²⁻²⁴. Hytonen et al.²³ showed the great effect that RF can have upon nasal obstruction. Harsten²⁵ reported that 85% of the 158 patients included in his study experienced a complete relief in their nasal obstruction. Also, there are studies who report up to 80 – 100% improvement in symptoms like sneezing, itchy nose or rhinorrhea^{22,26-28}, with favorable short and long term results^{14,21,29}.

Both techniques used in this study proved to be safe, with no major postoperative complications. However, the patients from DLT group related a higher nasal congestion than those patients from RFT group in the first week after surgery with more intense rhinorrhea in the second group, effects also related in other clinical studies^{26-28,30-33}.

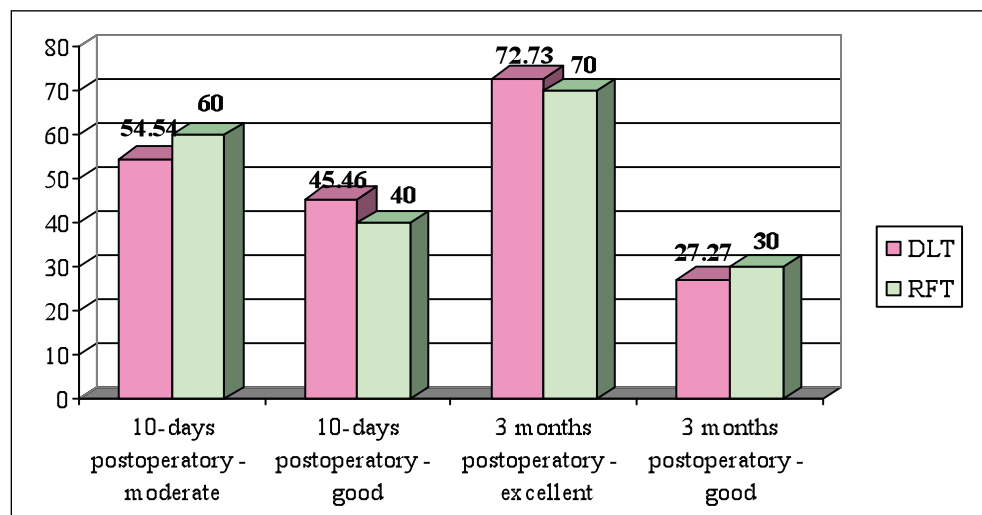


Chart 2 Overall symptoms improvement according to the type of the surgery 10-days and 3 months postoperative

Table 4
Descriptive statistics of the VAS results (mean value) for “nasal obstruction” parameter preoperatory, at 10-days and 3 months after surgery

Surgery Type	preoperatory	10-days postoperatory	3 months postoperatory	p-value
DLT	8.7	5.3	2.6	<0.05
RFT	8.9	5.5	2.8	<0.05

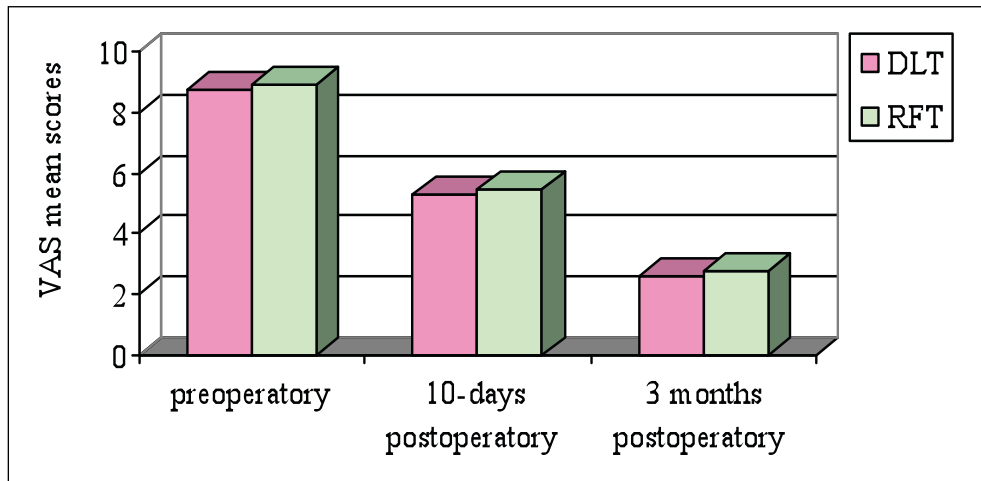


Chart 3 VAS scores mean values for “nasal obstruction” parameter, preoperatory, 10-days postoperatory and 3 months postoperatory

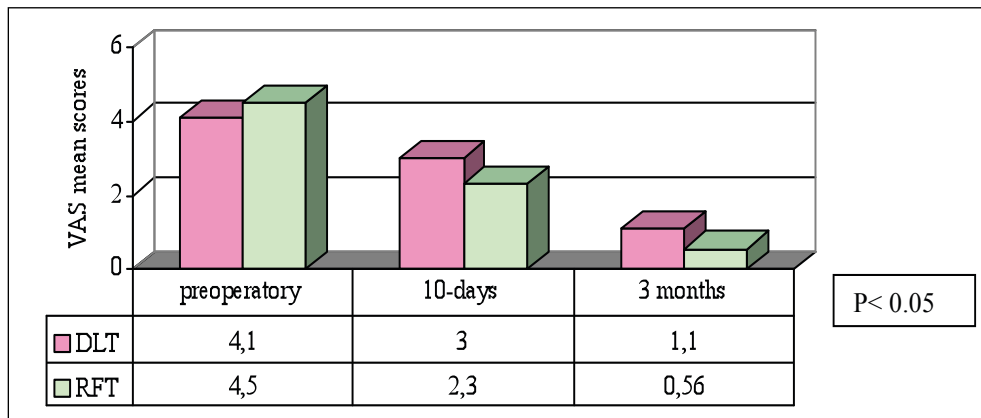


Chart 4 VAS scores mean values for “sneezing” parameter, preoperatory, 10-days postoperatory and 3 months postoperatory

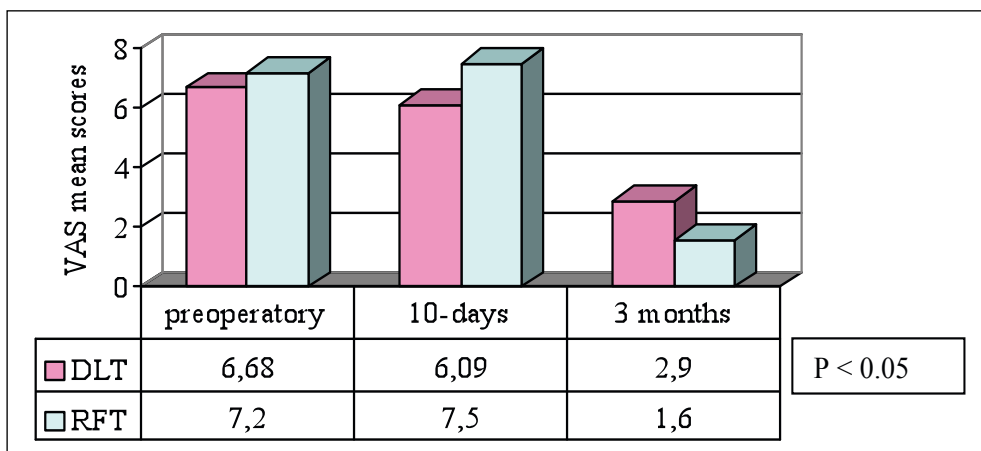


Chart 5 VAS scores mean values for “rhinorrhea” parameter, preoperatory, 10-days postoperatory and 3 months postoperatory

CONCLUSIONS

Clinical benefits obtained with laser and radiofrequency inferior turbinate reduction are not limited only to nasal obstruction but extending also to other symptoms of chronic rhinitis. Both treatment modalities seem to be well tolerated by the patients and effective in those cases of rhinitis unresponsive to pharmacotherapy.

Even if both methods have the same mechanism of action, differences may be attributed to the damage done to the tissue. The subjective evaluation related very good improvement in all symptoms for both surgical techniques. Even if the weakness of the study is the small number of the patients, the study is still in progress and we think that we can rely on the present results.

REFERENCES

1. Togias A.G. – Systemic immunologic and inflammatory aspects of allergic rhinitis. *Allergy Clin Immunol.*, 2000;106(5Suppl):S247-50.
2. Druce H.M. – Allergic and nonallergic rhinitis. In: Middleton E.M. Jr, Reed C.E., Ellis E.F., Adkinson N.F. Jr, Yunginger J.W., Busse W.W., eds. - *Allergy: Principles and Practice*. 5th ed. St. Louis, Mo: Mosby, Year-Book, 1998;p.1005-16.
3. Hellgren J. – Quality of life in non allergic rhinitis. *Cil Allergy Immunol.*, 2007;19:383-7.
4. Mabry R.L. - Surgery of the inferior turbinates: how much and when?. *Otolaryngol. Head Neck Surg*, 1984;92(5):571-6.
5. Sarafoleanu C. – *Rinologie*. Ed. Medicala, Bucuresti, 2003.
6. Thompson A.K., Juniper E., Meltzer E.O. - Quality of life in patients with allergic rhinitis. *Ann. Allergy. Asthma Immunol.*, 2000;85(5):338-348.
7. Blaiss M.S. - Quality of life in allergic rhinitis. *Ann. Allergy. Asthma Immunol.*, 1999;83(5):449-54.
8. Ophir D., Shapira A., Marshak G. - Total inferior turbinectomy for nasal airway obstruction. *Arch Otolaryngol. Head Neck Surg.*, 1985;111(2):93-95.
9. Wight R.G., Jones A.S. - Radical trimming of the inferior turbinates and its effect on nasal resistance to airflow. *J Laryngol Otol*, 1988;102:694-696.
10. Fanous N. - Anterior turbinectomy. A new surgical approach to turbinate hypertrophy: a review of 220 cases. *Arch Otolaryngol Head Neck Surg*, 1986;112:850-852.
11. Goode R.L. - Surgery of the turbinates. *J Otolaryngol*, 1978;7:262-268.
12. Ozenberger J.M. - Cryosurgery in chronic rhinitis. *Laryngoscope*, 1970;80:723-734.
13. Janda P., Sroka R., Baumgartner R., Grevers G., Leunig A. – Laser treatment of hyperplastic inferior nasal turbinates. *Lasers Surg Med*, 2001;28:404-413.
14. Li K.K., Powell N.B., Riley R.W., Troell R.J., Guilleminault C. - Radiofrequency volumetric tissue reduction for treatment of turbinate hypertrophy: a pilot study. *Otolaryngol Head Neck Surg*, 1998;119:569-573.
15. Joniau S., Wong I., Rajapaksa S., Carney S.A., Wormald P.J. – Long term comparison between submucosal cauterisation and powered reduction of the inferior turbinates. *Laryngoscope*, 2006;116:1612-1616.
16. Willatt D. – The evidence for reducing inferior turbinates. *Rhinology*, 2009;47:227-236.
17. Elwany S., Abel Salaam S. - Laser surgery for allergic rhinitis: the effect on seromucinous glands. *Otolaryngol Head Neck Surg*, 1999;120:742-744.
18. Mori S., Fujieda S., Igarashi M., Fan G.K., Saito H. - Submucous turbinate reduction decreases not only nasal stiffness but also sneezing and rhinorrhea in patients with perennial allergic rhinitis. *Clin Exp Allergy*, 1999;29:1542-1548.
19. Schmidt J., Zalewski P., Olszewski J., Olszewska-Ziaber A. - Histopathological verification of clinical indications to partial inferior turbinectomy. *Rhinology*, 2001;39:147-150.
20. Kim D., Baraniuk J.N. - Neural aspects of allergic rhinitis. *Curr Opin Otolaryngol Head Neck Surg*, 2007;15:268-273.
21. Supiyaphun P., Aramwatanapong P., Kerekhanjanarong V., Sastarasadhit V. - KTP laser inferior turbinoplasty: an alternative procedure to treat the nasal obstruction. *Auris Nasus Larynx*, 2003;30:59-64.
22. Cavaliere M., Mottola G., Iemma M. - Comparison of the effectiveness and safety of radiofrequency turbinoplasty and traditional surgical technique in treatment of inferior turbinate hypertrophy. *Otolaryngol Head Neck Surg*, 2005;133:972-978.
23. Hytönen M.L., Bäck L.J.J., Malmivaara A.V., Roine R.P. - Radiofrequency thermal ablation for patients with nasal symptoms: a systematic review of effectiveness and complications. *Eur Arch Otorhinolaryngol*, 2009;266:1257-1266.
24. Gindros G., Kantas I., Balatsouras D.G., Kaidoglou A., Kandiloros D. – Comparison of ultrasound turbinate reduction, radiofrequency tissue ablation and submucosal cauterization of inferior turbinate hypertrophy. *Eur Arch Otorhinolaryngol.*, 2012;267:1727-1733.
25. Harsten G. - How we do it: radiofrequency-turbinectomy for nasal obstruction symptoms. *Clin Otolaryngol*, 2005;30:64-66.
26. Luczaj J., Rogowski M. - Submucosal bipolar radiofrequency therapy for treatment of turbinate hypertrophy. *Otolaryngol Pol*, 2007;61(3):290-4.
27. Garzaro M., Pezzoli M., Pecorari G., Landolfo V., Defilippi S., Giordano C. - Radiofrequency inferior turbinate reduction: an evaluation of olfactory and respiratory function. *Otolaryngol Head Neck Surg*, 2010;143(3):348-52.
28. Lin H.C., Lin P.W., Friedman M., Chang H.W. Long-term results of radiofrequency turbinoplasty for allergic rhinitis refractory to medical therapy. *Arch Otolaryngol Head Neck Surg*, 2010;136(9):892-5.
29. Smith T.L., Correa A.J., Kuo T., Reinisch L. - Radiofrequency tissue ablation of the inferior turbinates using a thermocouple feedback electrode. *Laryngoscope*, 1999;109:1760-1765.
30. Saki N., Akhlagh S.N., Hekmat-Shoar M., Jafari N.S. – Efficacy of radiofrequency turbinoplasty for treatment of inferior turbinate hypertrophy. *Iranian Journal of Otorhinolaryngology*, 2011;23(3):27-32.
31. Sapci T., Usta C., Evcimik M.F., Bozkurt Z., Aygun E., Karavus A., et al. - Evaluation of radiofrequency thermal ablation results in inferior turbinate hypertrophies by magnetic resonance imaging. *Laryngoscope*, 2007;117(4):623-7.
32. Back L.J., Liukko T., Sinkkonen S.T., Ylikoski J., Mäkitie A.A. - Complication rates of radiofrequency surgery in the upper airways: a single institution experience. *Acta Otolaryngol*, 2009;129(12):1469-73.
33. OConnor-Reina C., Garcia-Iriarte M.T., Angel D.G., Morente J.C., Rodríguez-Díaz A. - Radiofrequency volumetric tissue reduction for treatment of turbinate hypertrophy in children. *Int J Pediatr Otorhinolaryngol*, 2007;71(4):597-601.