

LITERATURE REVIEW

Surgery for nasal obstruction in inferior turbinate hypertrophy

Mihai Saulescu^{1,2}, Codrut Sarafoleanu^{2,3}

¹ENT&HNS Department, Sanador Clinical Hospital, Bucharest, Romania

²“Carol Davila” University of Medicine and Pharmacy, Bucharest, Romania

³“Sfanta Maria” Hospital, Bucharest, Romania

ABSTRACT

In the international literature, there is no consensus on patient selection for turbinate surgery. Surgery is usually indicated to the patients on the basis of subjective complaint of nasal obstruction and surgeon’s clinical examination. Although most surgical techniques demonstrate a subjective and objective improvement in postoperative nasal airflow and subjective scores, it is hard to say which technique is best suited for treating inferior turbinate enlargement. Inferior turbinate reduction for nasal obstructive symptoms caused by enlarged turbinates is a useful procedure and is reserved for patients who are not responding to medical treatment or in whom the medical management is contraindicated.

KEYWORDS: turbinate hypertrophy, nasal obstruction, radiofrequency, laser, turbinectomy

INTRODUCTION

Chronic nasal airway obstruction is one of the most frequent symptoms encountered by the otorhinolaryngologist. The majority of these patients suffer from hypertrophied inferior turbinates¹. It is well established that nasal turbinates represent the primary controller of nasal airflow. They have a significant role in maintaining the normal health of the respiratory system and this is made primarily by its mucosa. This important anatomical part of the nose contributes to air filtration, air humidification and also to the warming of inspired air². Although it is not a life-threatening condition, chronic rhinitis can have a great impact upon patients’ quality of life and this is why an adequate treatment should be rapidly established^{3,4}. Physicians dispose of many techniques in order to cure enlarged turbinates⁵. The nasal mucosa of the turbinates swells as part of the nasal cycle, but this physiological swelling can be aggravated by inhaled allergens, infection, airborne irritants⁶. Medical treatments such as saline nasal sprays, topical corticosteroid sprays, antihistamines, sympathomimetic agents, anticholinergic drugs, silver nitrate solution,

various immunostimulants and capsaicin are usually the first-line therapy⁷. However, these treatments might be inadequate in achieving a significant resolution of nasal obstruction. This is why patients whose condition is refractory to medical therapy may seek additional treatment. In these cases, surgical reduction of the hypertrophic inferior turbinate has been advocated after failure of medical therapy⁸. Turbinate reduction is a surgical procedure made to obtain a volumetric reduction of the inferior turbinate and, thereby, decreasing airway resistance and improving nasal breathing.

Both the osseous and mucosal portion of the turbinate can be hypertrophic. Generally, patients with allergic rhinitis associate a swelling of the mucosa. On the other hand, unilateral enlargement of the bony structure is observed in patients with severe septal deviation⁹. This is why it is very important to find the real cause of the nasal obstruction, in order for the surgeon to choose the proper surgical techniques¹⁰.

Reduction of the enlarged inferior turbinates can be achieved with a multitude of different surgical techniques⁷, such as turbinoplasty (submucous resection, outfracture), radiofrequency ablation (RFA), extra-

mucosal or submucosal electrocautery, turbinectomy, laser-assisted resection or ablation, cryotherapy, ultrasound reduction^{7,11}. The goal of all these different techniques is represented by the maintaining of a normal physiology of the local mucosa. In order to achieve this, it is important to eliminate as much of the inferior turbinate bulk, but keeping most of the turbinate mucosa¹⁰.

RELEVANT ANATOMY AND HISTOLOGICAL NOTIONS

There are three paired turbinates - superior, middle and inferior - located on the lateral nasal wall. These bones are small, thin and have a shell-like shape. They are structured as follows: the superior and middle turbinates are part of the ethmoid bone, while the inferior turbinates form a separate one. Between the turbinates and the lateral nasal wall, there is a space called meatus. The superior turbinate, which is covered by both the respiratory and olfactory epithelium, can be found high in the nasal vault and usually grows from the cribriform plate of the ethmoid bone. The middle turbinate, a bony extension of the ethmoid, is characterized by a wide variation in origin, in some cases arising from the cribriform plate, the lamina papyracea or the uncinata process. The inferior turbinate bone has its origin on the inferior portion of the lateral nasal wall. The bone itself is penetrated heavily by vascular channels, which supply the overlying respiratory epithelium. The lacrimal duct exits into the nose below the inferior- anterior portion of this structure¹². The inferior turbinate is formed by a central layer of bone covered, on each side, with a mucosal layer.

Turbinate enlargement is commonly attributed to dilatation of the submucosal venous sinuses due to engorgement with blood¹³. The terms "hypertrophy" and "hyperplasia" have been interchangeably used for the description of turbinate enlargement. However, "hypertrophy" should be used for the enlargement of the turbinate resulting from an increase in size of its cells, whereas "hyperplasia" is an enlargement due to an increase in the number of cells¹³.

In chronic hypertrophic rhinitis (Figure 1), preoperative observations revealed severe metaplasia of the nasal epithelium, evident stratification in the epithelium and hyperplasia, degeneration of epithelial cells, loss of cilia and disruption of intercellular connections. Additionally, increased basilar membrane thickness, edema, nasal mucus overproduction and inflammatory infiltration in the lamina propria were observed. Increased number of goblet cells and submucosal glands was also found and the number of gland openings was increased¹⁴.

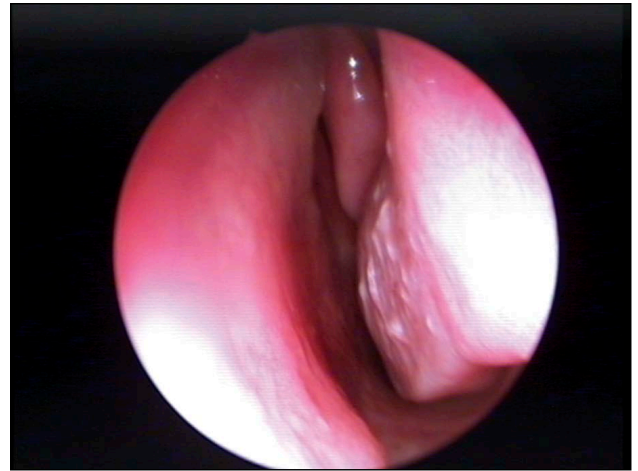

Figure 1 Hypertrophy of the inferior turbinate mucosa – nasal endoscopic examination

TURBINATE SURGERY

Despite the popularity of turbinate surgery, otolaryngologists do not have a uniform, standardized way to define turbinate hypertrophy or to select a patient for turbinate surgery. Additionally, no standardized way to select the type of turbinate surgery needed exists. It is still a clinical judgement based on the patient's symptoms, the ENT examination, the rhinomanometric and nasal endoscopic findings.

SURGICAL TECHNIQUES

Turbinectomy

Turbinectomy is a surgical manoeuvre that consists in the partial or complete resection of the inferior turbinate, performed with the scissors or the microdebrider. This type of procedure can be performed with and without the use of a nasal endoscope and it consists in removing the soft tissue from the lateral aspect of the inferior turbinate and the underlying bone, when bony hypertrophy is also involved^{7,15}. As a result of the partial or total turbinectomy, an important improvement of the nasal breathing can be observed, the recurrence being exceptional⁷. Some side effects can be observed after this procedure. The exposed raw mucosal edges and bone may lead to nasal crusting with need for postoperative debridement. Despite the electrocautery control, the mucosal edges may continue to bleed and nasal packing may be required for hemostasis¹⁰. Sometimes, postoperative pain is very important. Atrophic rhinitis is also a threat to the patients submitted to these procedures^{16,17}. Some evidence exists that turbinectomy may lead to a high incidence of empty nose syndrome, an iatrogenic syndrome of chronic nasal impairment due to extended

nasal surgery¹⁸. Excessive resection generates atrophy, crusting, bleeding. Paradoxically, the nasal breathing is impaired and the patient's quality of life is affected⁷.

Turbinoplasty

Two different procedures can be placed in the category of turbinoplasty: submucous resection and inferior turbinate outfracture¹⁰. In case of a submucous resection technique, an incision is performed at the head of the turbinate. Some of the turbinate tissue is excised with the help of a microdebrider and blunt dissector, allowing the mucosa to recover on a smaller turbinate bone. If a perforation is made in the mucosal flap or the surgeon has an imprecise approximation of the cut, crusts, synechia and bleeding may result¹⁹.

Outfracturing is another surgical technique, perhaps the simplest way to perform surgery for nasal obstruction. It consists in fracturing the bone of the inferior turbinate and pushing it laterally, subsequently maintaining this position with the aid of a nasal packing²⁰.

After multiple studies comparing different types of turbinate reduction, results have shown that the highest degree of normal nasal function with restoration of mucociliary clearance and IgA secretion was obtained after the submucosal resection, the results being still the best after 6 years. The outfracturing of the inferior turbinate performed after the submucous resection of the turbinate proved to improve the long-term results².

Electrocauterization

In the past, the electrocauterization of the inferior turbinate has been the most frequent procedure performed in order to reduce the volume of the inferior turbinate. Superficial or the submucosal thermal ablation produces scarring, fibrosis and obliteration of the venous sinuses. The classical concept states the fact

that the electrocauterization will be effective if the inferior turbinate is capable of decongestion²¹. The studies showed good results in 78% of the cases at 2 weeks postoperatively and in 76% of the cases at 2 months after the procedure²². In their study, Fradis et al. concluded that, two months postoperatively, 70.3% of patients experienced subjective improvement in nasal breathing, whereas 80.2% had good nasal breathing as indicated with the Gertner-Podoshin plate²³. An important advantage of the submucosal diathermy is represented by the fact that it can be done under local anaesthesia as an office procedure, being safe and effective both on a short-term and long-term basis.

Postoperative histopathological analysis of the nasal mucosa revealed a decrease of intercellular edema. However, regeneration of cilia in turbinate mucosal surface was not observed. A slight reduction of mucus and overproduction of collagen were also observed and the respiratory epithelium was degenerated to flattened stratified¹⁴.

Laser

Various laser systems have been tested for turbinate reduction, but most experience has been gained with the carbon dioxide (CO₂), argon, diode, neodymium-yttrium aluminum garnet (Nd:YAG), potassium-titanyl-phosphate (KTP), holmium:yttrium-aluminum-garnet (Ho:YAG) laser, magnet laser. Different types of lasers can be used in a contact or a non-contact mode^{1,7}.

The main advantage in using a laser beam for the reductive surgery of the inferior turbinate resides in the fact that the laser produces no damages to the surrounding tissues, apart from the area requiring treatment⁷. For example, the use of the Nd:YAG and diode Laser (Figure 2) is indicated if mucosal swelling affects the entire turbinate. With a flexible laser fiber, guided

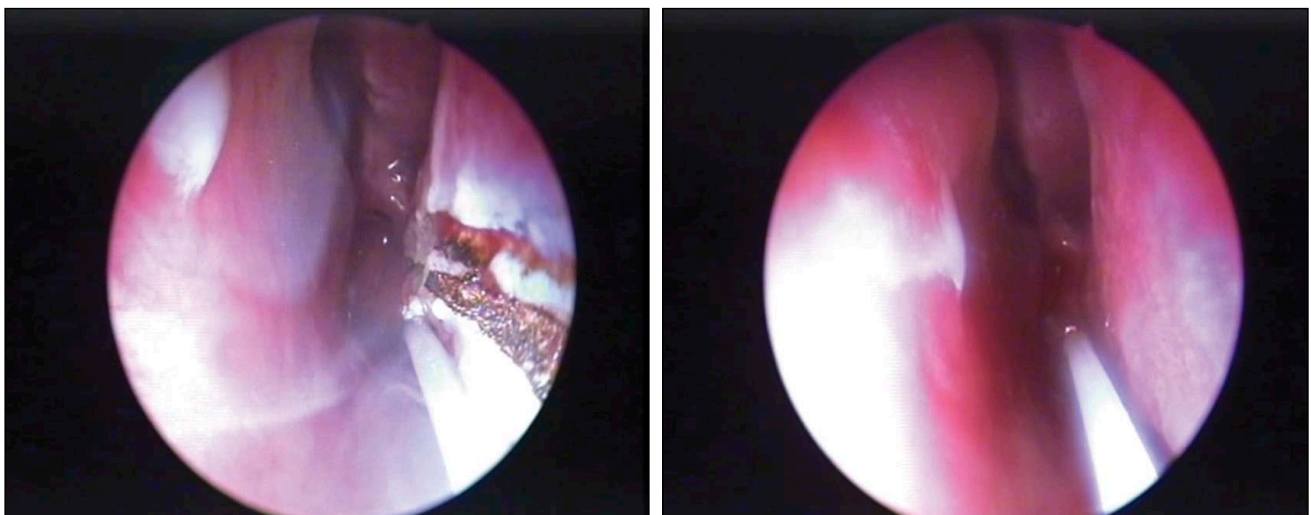


Figure 2 Intraoperative view – diode LASER reduction of the inferior turbinate mucosa

by a laser rhinoscope, even the posterior part of the inferior turbinate can be treated. In contrast, because of its straight beam, the CO₂ Laser is especially suitable for reducing the hyperplastic tip of the turbinate.

Various techniques for reducing the turbinates with a Laser have been described. Investigations have shown the single-spot technique to be the most suitable for the CO₂ Laser. In this technique, the swollen turbinate tip is treated with single laser spots, inducing shrinkage of the mucosa with subsequent scarring. A small carbonization and necrosis zone develops after laser light application at reduced power and focus. The result is represented by limited tissue traumatization and a rapid reepithelialization. In contrast to the CO₂ Laser, turbinate treatment with another type of lasers, such as diode, Nd:YAG, is carried out by applying a contact or non-contact technique. The immediate effect of the laser light should be barely recognizable as a tiny spot showing paling of the mucosa. The laser light penetrates the tissues to a depth of 10 mm and is absorbed in the cavernous body of the submucosal vascular network of the turbinate. This leads to vasculitis followed by protracted scarring with secondary shrinkage and reduction of the turbinates' potential for swelling¹. Surgery is made as an outpatient procedure, under local anaesthesia. The nasal cavity is sequentially anesthetized, first with lidocaine 10% nasal spray, followed by cotton pledges soaked in lidocaine /naphazoline mixture placed in both nostrils for 15 minutes. After surgery, the nasal cavities are left unpacked. Patients are advised not to blow their nose for 24 hours to prevent a nasal bleeding. Also, all patients are informed to expect approximately 7-10 days of increased nasal congestion and rhinorrhea due to intranasal mucosa swelling. Thus, the clearly beneficial effect on nasal breathing is usually not evident until several weeks after. This can be explained by the

gradual regression of the reactive mucosal edema and the slowly commencing submucosal scarring process, which takes about 4-6 months to be complete. Also, the fibrinous incrustations, which can be very pronounced in some cases, necessitate regular follow-up care for several weeks. Histopathologic studies showed a reduction in the number and function of glandular cells²⁴, with a decrease of the vessels number and nasal glands^{25,26}. Because of these effects, the secretor reflex is changed, the result being a reduction of the rhinorrhea²⁷. Also, sneezing, itching or nasal obstruction were found to be reduced after the treatment^{28,29}. The minus point for this kind of procedure is the poor long-time results on a long-term survey³⁰.

Radiofrequency surgery

Radiofrequency (RF) is a surgical method that can be safely used for the inferior turbinate reduction⁷. RF energy is used in order to determine a submucosal tissue injury, leading to the reduction of tissue volume³¹. The thermal probe used in this particular technique is introduced into the inferior turbinate and the radioenergy released contributes to cutting some of the tissue¹⁰. This method, first described by Li and colleagues in 1998, is based on the formation of a submucosal scar. This is the result of using an alternating electric current⁷. A positive aspect of this procedure is the fact that it can be performed as an out-hospital procedure, only with local anaesthesia³². The treatment starts with a topical anaesthetic applied to the inferior turbinate for 1-5 minutes, followed by a local anaesthetic injection. The RF needle electrode is then inserted submucosally at 1 to 4 different sites of the inferior turbinate up to the bone turbinate (Figure 3). It is important not to harm the mucosa posterior to the puncture site. After this procedure, there is no need for local treatment, but only for pressing for a few minutes a cotton

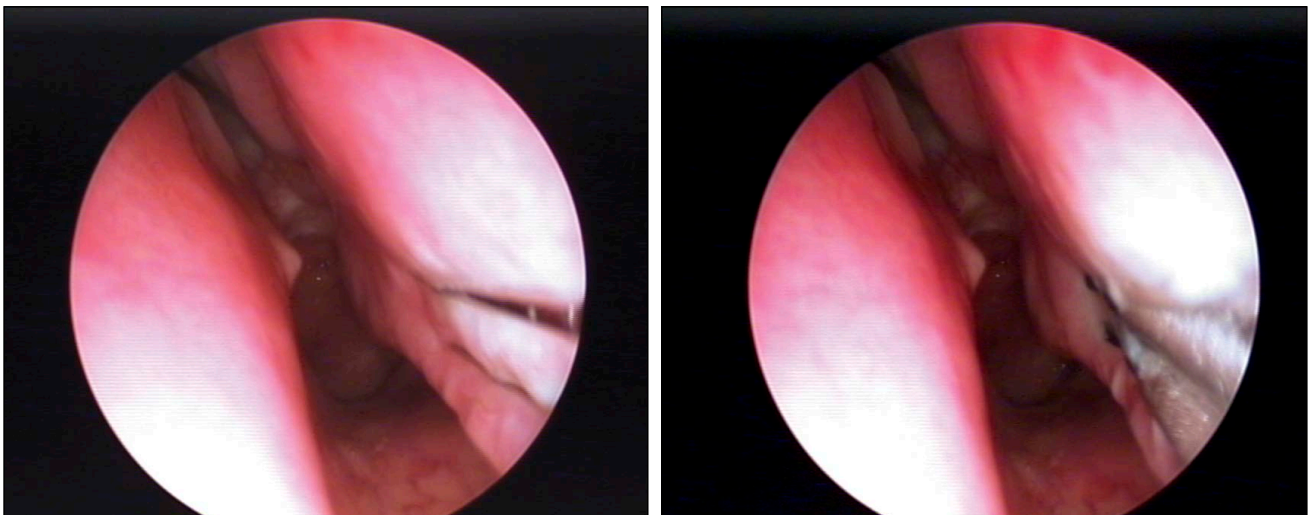


Figure 3 Inferior turbinate mucosa reduction with radiofrequency – intraoperative view

ball at the puncture site. Then, the patient is capable of returning to his normal daily living. If the pain occurs, it is well managed with any analgesics³¹.

Postoperative scarring and fibrosis reduce the volume of the inferior turbinate. Although fibrotic tissue replaces the glands and venous plexuses, the nasal mucociliary function remains preserved³³. From the histological point of view, lack of cilia regeneration in conjunction with profuse submucosal collagen production is observed. Metaplastic epithelium combined with islands of increased gland secretion can also be found¹⁴. Many studies advocate the effectiveness of radiofrequency treatment for the inferior turbinate³⁴⁻³⁶. Hytönen et al. showed in a literature review the great effect RF can have upon chronic nasal obstruction, especially in those cases that failed to respond to medical treatment³⁷. Harsten reported that 85% of the 158 patients included in his study experienced a complete relief in their nasal obstruction³⁸. Also, there are studies that report up to 80-100% improvement in symptoms like sneezing, itchy nose or rhinorrhea³⁹⁻⁴¹, with favourable short- and long-term results^{29,42,43}. This type of surgery can be used for those patients with minor inferior turbinate obstruction, being usually a simple procedure⁴⁴.

Ultrasound turbinate reduction

Ultrasound turbinate tissue volume reduction has been introduced since the beginning of the 1960s and widely used in general surgery. This method is efficient for the reduction of enlarged nasal turbinates, because the affected tissues are exposed to ultrasonic disintegration, by means of a submucous low-frequency fluctuation of an ultrasonic nasal probe. This results in destruction of the cavernous and connecting tissues, with subsequent reduction of the turbinates volume as a result of infraturbinate scarring. Fast restoration of the nasal respiratory function may thus be obtained.

After this intervention, decrease of mucus secretion and interstitial edema was observed. Profuse presence of fibroblast bundles and collagen fibers was found in the chorium. Sparse islands with normally organized stratified epithelium of columnar cells and sparse goblet cells were evident, combined with islands of metaplastic epithelium. The islands of regenerated epithelium contained cells with sparse short cilia on their surface¹⁴.

Other surgical techniques less used are: chemocautery, cryosurgery, vidian neurectomy. When cryotherapy is used for treatment of chronic vasomotor rhinitis, better results are obtained with longer freeze duration and also larger area of administration. Obstructive symptoms, evaluated from an objective, but also subjective point of view, disappeared in 92% of cases and were significantly improved in the remaining 8%, as some study has already showed⁴⁵.

The application of phenol to the turbinate mucosa has been used in the past, but is no longer used because of toxicity issues¹². Vidian neurectomy practically produces a parasympathetic denervation of the nasal mucosa leading to the improvement of both rhinorrhea and nasal obstruction. The complications of this surgical treatment consist in nasal crusting, dry eyes and facial numbness⁴⁶.

Surgical therapy will continue to be reserved for patients whose conditions are refractory to medical treatment. The major controversies surrounding turbinate surgery continue to be centred on the best management techniques. Avoidance of aggressive therapies and control of the underlying disease states are paramount to disease management. When performed for the appropriate reasons, turbinate reduction surgery is very successful in reducing symptoms of congestion, as nasal obstruction and rhinorrhea. Because no surgical procedure cures the underlying condition, further medical therapy may be necessary¹².

CONCLUSIONS

Inferior turbinate reduction is a simple, minimally invasive alternative to address nasal obstruction secondary to enlarged inferior turbinates. This type of surgical operation is not a complex procedure and can be done under local anaesthesia with minimal postoperative morbidity. This operation has the purpose to improve the quality of life, as well to enhance longevity and to reduce the risk of medical morbidity. Before any kind of intervention, the surgeon has to be familiar with the rationale and indications for each surgery technique. A systematic review of the patient will aid in identification of regions of obstruction and minimize the risk and potential complications. The target of this intervention is to maintain nasal airflow patency and to reduce mouth breathing.

There is no unique procedure that can be applied to all the patients. Due to this reason, it is very important for the surgeon to know a large variety of techniques in order to choose the right one for a specific patient.

REFERENCES

1. Steiner W., Werner A.J. - Lasers in otorhinolaryngology, head and neck surgery. Endo-Press, Tuttlingen, 2006.
2. Leong S.C., Eccles R. - Inferior turbinate surgery and nasal airflow: evidenced-based management. *Curr Opin Otolaryngol Head Neck Surg.*, Feb. 2010;18(1):54-9.
3. Thompson A.K., Juniper E., Meltzer E.O. - Quality of life in patients with allergic rhinitis. *Ann Allergy Asthma Immunol.*, 2000;85(5):338-348.
4. Blaiss M.S. - Quality of life in allergic rhinitis. *Ann Allergy Asthma Immunol.*, 1999;83(5):449-54.

5. Hol M.K., Huizing E.H. - Treatment of inferior turbinate pathology: a review and critical evaluation of the different techniques. *Rhinology*, Dec 2000;38(4):157-66.
6. Hanif J., Jawad S.S., Eccles R. - The nasal cycle in health and disease. *Clin Otolaryngol Allied Sci.*, Dec 2000;25(6):461-7.
7. Passali D., Bellussi L.M., Kern E.B., Sarafoleanu C., Popescu F.D. - Rhinosinusal Inflammation And Infections: Modern Thinking And Current Treatment. Ed. Academiei Romane, Bucharest, 2013.
8. Passali D., Passali F.M., Damiani V., Passali G.C., Bellusi L. - Treatment of inferior turbinate hypertrophy: a randomized clinical trial. *Ann Otol Rhinol Laryngol.*, 2003;112:683-688.
9. Mucci S., Sismanis A. - Inferior partial turbinectomy: an effective procedure for chronic rhinitis. *Ear Nose Throat J.*, 1994;73:405-457.
10. Zapanta P.E., DeVries G.M., Khoury T. - Turbinectomy. *Medscape*, 2014. <http://emedicine.medscape.com/article/2051775-overview>.
11. Bhandarkar N.D., Smith T.L. - Outcomes of surgery for inferior turbinate hypertrophy. *Curr Opin Otolaryngol Head Neck Surg.*, Feb. 2010;18(1):49-53.
12. Archer S.M., Meyers A.D. - Turbinate dysfunction. *Medscape*, 2014. <http://emedicine.medscape.com/article/877872-overview>.
13. Farmer S.E., Eccles R. - Chronic inferior turbinate enlargement and the implications for surgical intervention. *Rhinology*, 2006;44:234-238.
14. Gindros G., Kantas I., Balatsouras D.G., et al. - Mucosal changes in chronic hypertrophic rhinitis after surgical turbinate reduction. *Eur Arch Otorhinolaryngol.*, 2009;266:1409-1416.
15. Ozcan K.M., Gedikli Y., Ozcan I., Pasaoglu L., Dere H. - Microdebrider for reduction of inferior turbinate: evaluation of effectiveness by computed tomography. *J Otolaryngol Head Neck Surg.*, Aug 2008;37(4):463-8.
16. Wight R.G., Jones A.S., Buckingham E. - Trimming of the inferior turbinates: a prospective long-term study. *Clin Otolaryngol.*, 1990;15:347-350.
17. Ophir D., Shapira A., Marshak G. - Total inferior turbinectomy for nasal airway obstruction. *Arch Otolaryngol Head Neck Surg.*, 1985;111:93-95.
18. Chhabra N., Houser S.M. - The diagnosis and management of empty nose syndrome. *Otolaryngol Clin North Am.*, Apr 2009;42(2):311-30, ix. doi: 10.1016/j.otc.2009.02.001
19. Batra P.S., Seiden A.M., Smith T.L. - Surgical management of adult inferior turbinate hypertrophy: a systematic review of the evidence. *Laryngoscope*, Sep 2009;119(9):1819-27.
20. Goode R.L. - Surgery of the turbinates. *J Otolaryngol.*, 1978;7:262-268.
21. Jones A.S., Wight R.G., Kabil Y., Buckingham E. - Predicting the outcome of submucosal diathermy to the inferior turbinates. *Clin Otolaryngol.*, 1989;14:41-44.
22. Fradis M., Goltz A., Danino J., et al. - Inferior turbinectomy versus submucosal diathermy for inferior turbinate hypertrophy. *Ann Otol Rhinol Laryngol.*, 2000 Nov;109(11):1040-5.
23. Fradis M., Malatsky S., Magamsa I., Goltz A. - Effect of submucosal diathermy in chronic nasal obstruction due to turbinate enlargement. *Am J Otolaryngol.*, 2002 Nov-Dec;23(6):332-6.
24. Elwany S., Abel Salaam S. - Laser surgery for allergic rhinitis: the effect on seromucinous glands. *Otolaryngol Head Neck Surg.*, 1999;120:742-744.
25. Mori S., Fujieda S., Igarashi M., Fan G.K., Saito H. - Submucous turbinectomy decreases not only nasal stiffness but also sneezing and rhinorrhea in patients with perennial allergic rhinitis. *Clin Exp Allergy*, 1999;29:1542-1548.
26. Schmidt J., Zalewski P., Olszewski J., Olszewska-Ziaber A. - Histopathological verification of clinical indications to partial inferior turbinectomy. *Rhinology*, 2001;39:147-150.
27. Kim D., Baraniuc J.N. - Neural aspects of allergic rhinitis. *Curr Opin Otolaryngol Head Neck Surg.*, 2007;15:268-273.
28. Willatt D. - The evidence for reducing inferior turbinates. *Rhinology*, 2009;47:227-236.
29. Supiyaphun P., Aramwatanapong P., Kerekhanjanarong V., Sastarasadhith V. - KTP laser inferior turbinoplasty: an alternative procedure to treat the nasal obstruction. *Auris Nasus Larynx*, 2003;30:59-64.
30. Janda P., Sroka R., Baumgartner R., Grevers G., Leunig A. - Laser treatment of hyperplastic inferior nasal turbinates. *Lasers Surg Med.*, 2001;28:404-413.
31. Friedman M., et al. - Sleep Apnea and Snoring, Surgical and Non-Surgical Therapy. Ed. Saunders Elsevier, 2009.
32. Schumacher M.J. - Nasal dyspnea: the place of rhinomanometry in its objective assessment. *Am J Rhinol.*, Jan-Feb 2004;18(1):41-6.
33. Garzaro M., Pezzoli M., Landolfo V., Defilippi S., Giordano C., Pecorari G. - Radiofrequency Inferior Turbinate Reduction: Long-Term Olfactory and Functional Outcomes. *Otolaryngol Head Neck Surg.*, 2012 Jan;146(1):146-50. doi: 10.1177/0194599811423008. Epub 2011 Sept 20.
34. Nease C.J., Kreml G.A. - Radiofrequency treatment of turbinate hypertrophy: a randomized, blinded, placebo-controlled clinical trial. *Otolaryngol Head Neck Surg.*, 2004;130:291-299.
35. Barbieri M., Salami A., Mora F., Barbieri A., Cordone M.P., et al. - High frequency surgery in the treatment of turbinate hypertrophy: 11 years experience. *Acta Otorhinolaryngol Ital.*, 2003;23:436-439.
36. Porter M.W., Hales N.W., Nease C.J., Kreml G.A. - Long-term results of inferior turbinate hypertrophy with radiofrequency treatment: a new standard of care? *Laryngoscope*, 2006;116:554-557.
37. Hytönen M.L., Bäck L.J.J., Malmivaara A.V., Roine R.P. - Radiofrequency thermal ablation for patients with nasal symptoms: a systematic review of effectiveness and complications. *Eur Arch Otorhinolaryngol.*, 2009;266:1257-1266.
38. Harsten G. - How we do it: radiofrequency turbinectomy for nasal obstruction symptoms. *Clin Otolaryngol.*, 2005;30:64-66.
39. Cavaliere M., Mottola G., Iemma M. - Comparison of the effectiveness and safety of radiofrequency turbinoplasty and traditional surgical technique in treatment of inferior turbinate hypertrophy. *Otolaryngol Head Neck Surg.*, 2005;133:972-978.
40. Luczaj J., Rogowski M. - Submucosal bipolar radiofrequency therapy for treatment of turbinate hypertrophy. *Otolaryngol Pol.*, 2007;61(3):290-4.
41. Lin H.C., Lin P.W., Friedman M., Chang H.W. - Long-term results of radiofrequency turbinoplasty for allergic rhinitis refractory to medical therapy. *Arch Otolaryngol Head Neck Surg.*, 2010;136(9):892-5.
42. Li K.K., Powell N.B., Riley R.W., Troell R.J., Guilleminault C. - Radiofrequency volumetric tissue reduction for treatment of turbinate hypertrophy: a pilot study. *Otolaryngol Head Neck Surg.*, 1998;119:569-573.
43. Smith T.L., Correa A.J., Kuo T., Reinisch L. - Radiofrequency tissue ablation of the inferior turbinates using a thermocouple feedback electrode. *Laryngoscope*, 1999;109:1760-1765.
44. Eccles R., Jawad M.S., Jawad S.S., Angello J.T., Druce H.M. - Efficacy and safety of single and multiple doses of pseudoephedrine in the treatment of nasal congestion associated with common cold. *Am J Rhinol.*, Jan-Feb 2005;19(1):25-31.
45. Bumsted R.M. - Cryotherapy for chronic vasomotor rhinitis: technique and patient selection for improved results. *Laryngoscope*, 1984;94:539-544.
46. Lee J.C., Lin Y.S. - Endoscopic vidian neurectomy: update on techniques and evidence. *Curr Opin Otolaryngol Head Neck Surg.*, Feb 2012;20(1):66-72.

