

CASE REPORT

Fourth mandibular molar in a pediatric patient – Case report

Atanas Vlaykov¹, Dian Sharlanov¹, Dilyana Vicheva²

¹Department of Otorhinolaryngology, University Hospital, Stara Zagora, Bulgaria

²Department of Otorhinolaryngology, Medical University, Plovdiv, Bulgaria

ABSTRACT

BACKGROUND. Supernumerary teeth are described as an excess of the normal teeth number of 20 deciduous and 32 permanent teeth and can occur in any dental region.

MATERIAL AND METHODS. The authors present the case of a 12-year-old female child with a paramolar in the maxilla, discovered accidentally during an orthopantomogram, emphasising the treatment modality and the complications that can appear.

CONCLUSION. Supernumerary teeth can be present in any region of the oral cavity. Both practitioners and clinicians should be aware of the various types of paramolars and make a treatment plan after an accurate clinical and radiographic examination.

KEYWORDS: supernumerary teeth, fourth retromolar, orthopantomogram, surgery

INTRODUCTION

Supernumerary teeth are described as an excess of the normal teeth number of 20 deciduous and 32 permanent teeth. They may occur in any dental region, and are more frequently observed in the maxilla¹.

The supernumerary teeth can be classified, according to the location, into mesiodens, paramolar and distomolar. Mesiodens represents a conical supernumerary tooth which is located between the maxillary central incisors. The paramolar is situated buccally or palatally, adjacent to one of the maxillary molars, or in the interproximal buccal space between the 2nd and the 3rd molars. The distomolar type can be found distally to the 3rd molar². Referring to their shape, the supernumerary teeth can be classified as supplemental, presenting a normal morphology, and rudimentary, with some anomalies³.

The exact etiology of this entity is not completely understood, but a combination of genetic and environmental factors are most frequently discussed⁴. In most cases, the origin is considered to be the hyperactivity or horizontal proliferation of the permanent or deciduous dental lamina⁵.

The incidence rate of supernumerary teeth is 2.1% in permanent dentition and 0.8% in deciduous denti-

tion⁶. 90% of all supernumerary teeth are found in the anterior medial region of the maxillary jaw. Rarely, they can be identified in the mandibular area. They can also be located in the superior and inferior distomolar area, superior premolar, superior canine or inferior incisor zone. In the maxilla, supernumerary teeth are found mostly between the central incisors, the occurrence in the molar region being extremely rare⁷. Paramolars are more common in males than females, in a ratio of 2:1⁸.

CASE REPORT

We present the case of a 12-year-old female child with a paramolar in the maxilla. The patient presented to a dentofacial orthopaedic accusing a dental deformity. The orthopantomogram performed revealed a shadow with cystic cavity characteristics in the right retromolar space, filled with a rounded mass resembling a tooth germ (the 48th tooth) (Figure 1).

For the future success of the orthodontic treatment, the orthodontist referred the patient to an oral surgeon (ENT Clinic of the University Hospital, Stara Zagora) for the extraction of the 48th tooth together with the cystic mass.

The surgical procedure was performed under local anaesthesia. The first step consisted in a linear incision in the right retromolar space, preserving a muco-periosteal flap. The trepanation of the mandibular cortical part revealed a pea-sized cystic mass, contain-

ing the crown of the 48th accessory tooth (Figure 2). The germ of the tooth, located medially, was removed by performing a dental germectomy (Figure 3).

The postoperative evolution was favourable, the sutures being removed seven days after surgery (Figure 4).

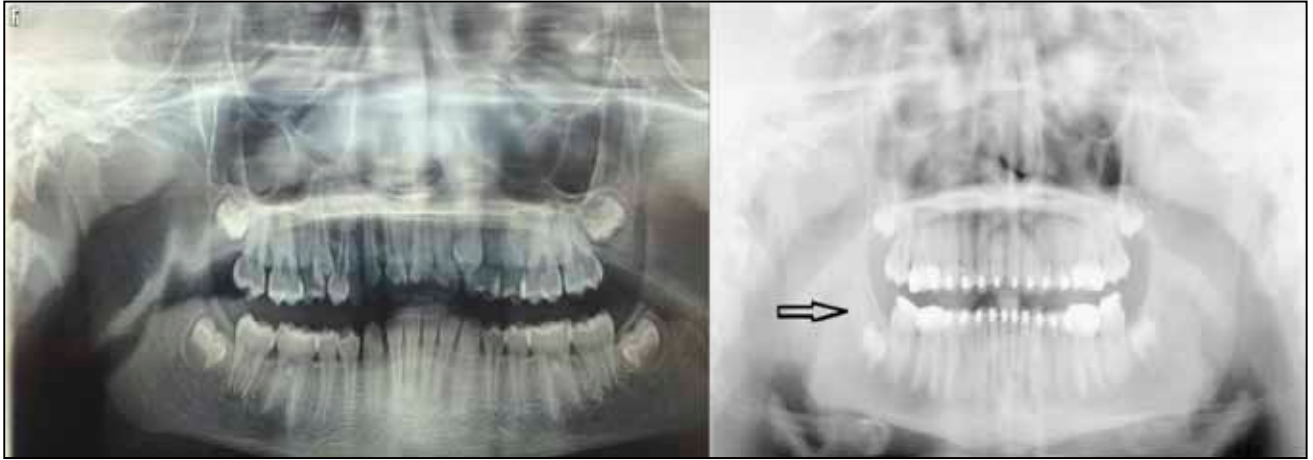


Figure 1 Orthopantomogram - a rounded shadow situated in the right retromolar space, with characteristics of a cystic cavity, filled with rounded mass resembling a tooth germ

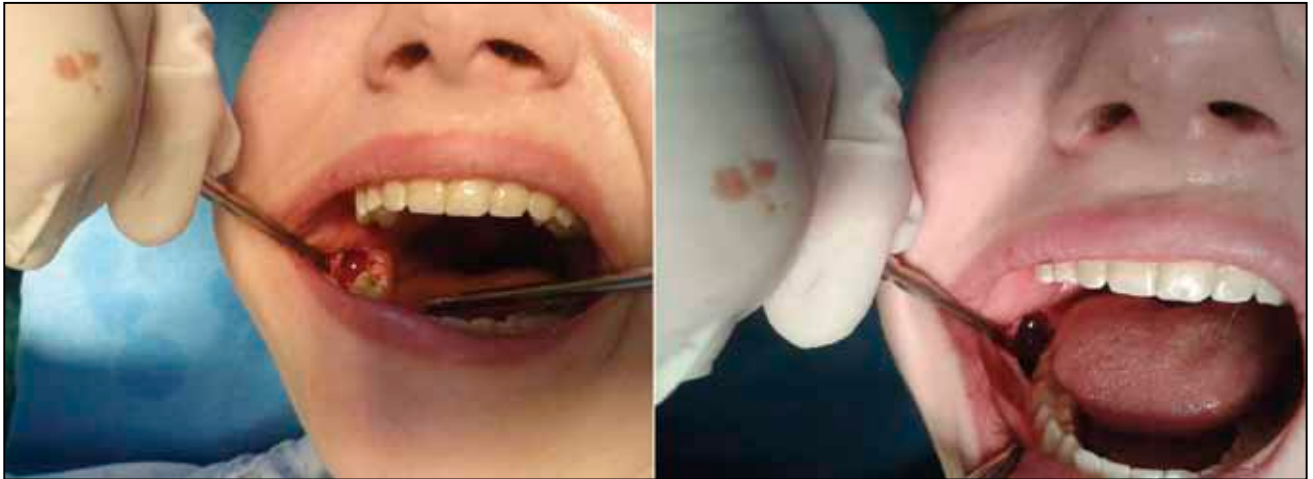

Figure 2 Intraoperative view - incision performed in the right retromolar space; trepanation of the mandibular cortical part revealing a cystic mass containing the crown of the 48th accessory tooth

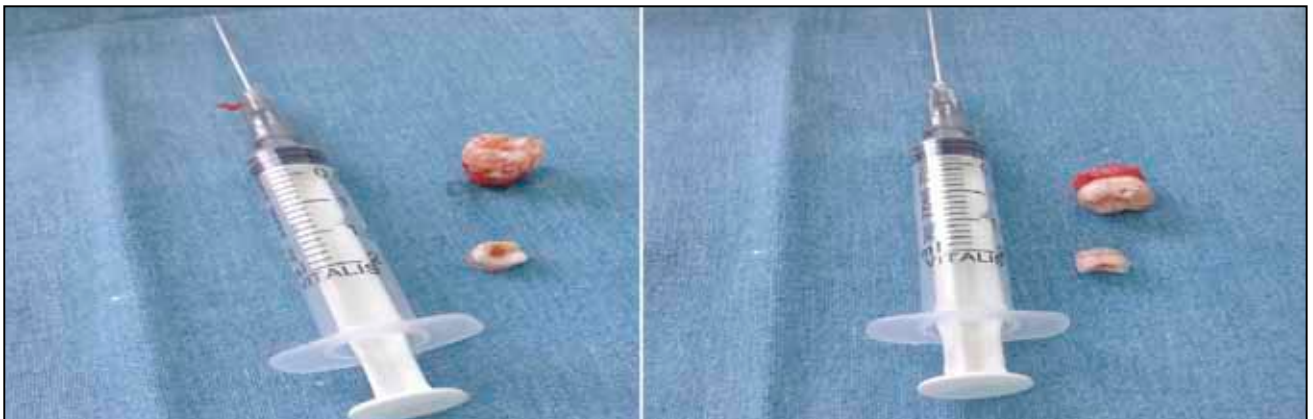

Figure 3 Operatory samples – the third and the fourth molar

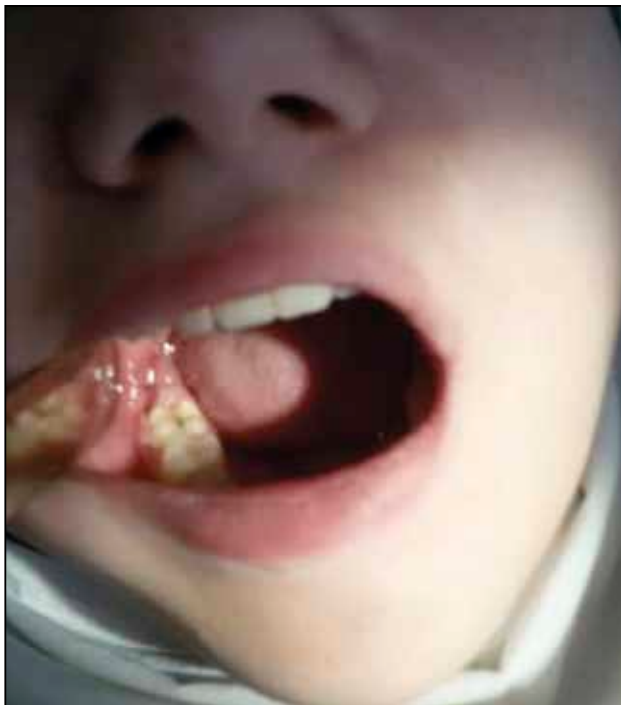

Figure 4 Seven-day follow-up

DISCUSSIONS

The extra molars located beside the third molar are called paramolar teeth. The paramolar is a relatively uncommon dental finding. There are multiple etiologies that can lead to the appearance of this developmental anomaly, but the exact determining factors are still unknown.

The prevalence of these teeth has been reported to be of 1.5-3.5% in the permanent dentition and of 0.2-0.8% in deciduous dentition⁹.

The paramolars can present as erupted or unerupted. The first entity is usually discovered accidentally, during radiographic examination for a different pathology. More frequently, the fourth molars do not erupt into the oral cavity¹⁰.

The presence of supernumerary teeth can lead to different clinical disturbances, as follows¹¹:

- Malocclusion, due to the diminution of the dental arch space;
- Traumatic laceration of the buccal mucosa;
- Retention or ectopic eruptions;
- Follicular cysts;
- Pain in the molar area, trigeminal neuralgia;
- Periodontal disease and caries;
- Pulp necrosis or root resorption of the adjacent teeth, because of the pressure that can be exerted by the paramolar tooth.

There are two main treatment modalities for the unerupted supernumerary teeth - a wait and watch approach, if the tooth is asymptomatic and accidentally

found during an X-ray examination, or immediate extraction if it causes any complaints. They must be extracted when their presence is responsible for the failure of eruption of other teeth or if they provoke some complications¹².

Some authors suggest the extraction even for those paramolars without clinical manifestations, in order to prevent the complications¹³.

In our case, we preferred to extract the third and the fourth molar in a single surgical procedure, considering the need for a future orthodontic treatment.

CONCLUSIONS

Supernumerary teeth can be present in any region of the oral cavity. Both practitioners and clinicians should be aware of the various types of paramolars and make a treatment plan after an accurate clinical and radiographic examination.

Conflicts of interests: None.

Contribution of authors: All authors have equally contributed to this work.

REFERENCES

1. Schulze C. - Developmental abnormalities of the teeth and jaws. In: Gorlin R.J., Goldman H.M. - Thoma's oral pathology. 6th edn. C.V. Mosby Co., St Louis, 1970;p.96-183.
2. Dubuk A.N., Selvig K.A., Tellefsen G., Wikesjö U.M. - Atypically located paramolar. Report of a rare case. *Eur J Oral Sci.*, 1996;104(2 (Pt 1)):138-140.
3. Primosch R.E. - Anterior supernumerary teeth – assessment and surgical intervention in children. *Pediatr Dent.*, 1981;3(2):204-215.
4. Brook A.H. - A unifying aetiological explanation for anomalies of human tooth number and size. *Archs Oral Biol.*, 1984;29(5):373-378.
5. Stellzig A., Basdra E.K., Komposch G. - Mesiodentes: incidence, morphology, etiology. *J Orofac Orthop.*, 1997;58(3):144-153.
6. Purkait S.K. - Essentials of Oral Pathology 3rd ed. Jaypee Brothers Medical Pub., 2011;p.36-39.
7. Leco Berrocal M.I., Martín Morales J.F., Martínez González J.M. - An observational study of the frequency of supernumerary teeth in a population of 2000 patients. *Med Oral Patol Oral Cir Bucal.*, 2007;12(2):E134-138.
8. Munshi A., Munshi A.K. - Midline space closure in the mixed dentition: a case report. *J Indian Soc Pedod Prev Dent.*, 2001;19(2):57-60.
9. Winter G.B. - Anomalies of tooth formation and eruption. In: Welbury R.R., editor - *Paediatric Dentistry*, ed 2. Oxford, UK: Oxford University Press, 2001;p.255-256.
10. Raley L.L., Reichert E. - Four impacted fourth molars. *Oral Surg Oral Med Oral Pathol.*, 1975;40:564-565.
11. Vennarini S.A., Venezia A., Mori G., Casa DE' Martinis L. - Quarto molare eziopatogenesi ed epidemiologia. *Casi clinici. Dental Cadmos*, 1993;11:38-45.
12. Piattelli A., Tete S. - Bilateral maxillary and mandibular fourth molars. Report of a case. *Acta Stomatol Belg.*, 1992;89:57-60.
13. Ferreira-Junior O., de Ávila L.D., da Silva Sampieri M.B., Dias-Ribeiro E., Chen W.L., Fan S. - Impacted lower third molar fused with a supernumerary tooth: Diagnosis and treatment planning using cone-beam computed tomography. *Int J Oral Sci.*, 2009;1(4):224-228.