

ORIGINAL STUDY

Stent technique for endoscopic dacryocystorhinostomy – Our expertise

Vlad Budu¹, Tatiana Decuseara¹, Bogdan Mocanu², Raluca Baican¹, Mihai Tusaliu¹,
Diana Cojocar¹, Ion Bulescu³

¹“Prof. Dr. Dorin Hociota” Institute of Phono-Audiology and Functional ENT Surgery, Bucharest, Romania

²Monza Hospital, Bucharest, Romania

³Department of Morphology, “Carol Davila” University of Medicine and Pharmacy, Bucharest, Romania

ABSTRACT

BACKGROUND. Endoscopic dacryocystorhinostomy is known to be the ideal treatment for saccal and postsaccal stenosis of the lacrimal apparatus. Following this surgery, an important inconvenient would be the stenosis of the created ostium with consecutive epiphora.

MATERIAL AND METHODS. 20 patients with chronic unilateral lacrimal duct obstruction were operated in “Prof. Dr. D. Hociota” Institute of Phono-Audiology and Functional ENT Surgery, Department I, between January 2015 and July 2015. After creating the dacryocystorhinostoma, a stent was inserted transnasally to the bottom edge of the lacrimal sac and positioned to the bony margin of the ostium. Stents used varied in size from 1 to 3 mm in diameter. We followed-up our patients at 2 weeks and 1, 3, 6 months, assessing the symptoms of the lacrimal apparatus, especially the epiphora.

RESULTS. The mean age of patients varied between 31 and 65. Most of our patients were women (n=14). In a total number of 16 patients epiphora disappeared, it decreased in 2 patients, and persisted in 2 patients. There were two patients with no changes who have spontaneously eliminated the stent 2 or 3 days after the surgery. The most widely used stent size was 3 mm diameter, with a success rate of 90%.

CONCLUSION. The endoscopic approach may be an effective procedure in patients with pathologies of the lacrimal apparatus. In order to achieve an efficient result, both a preoperative rigorous preparation and also postoperative medical care are necessary. In conclusion, ostium stenting represents a better way to ensure a longer period of maintaining the permeability of the lacrimal apparatus.

KEYWORDS: dacryocystorhinostomy, lacrimal apparatus stent, chronic dacryocystitis

INTRODUCTION

Dacryocystorhinostomy, better known as DCR, is the surgical bypass of the lacrimal sac and duct for the treatment of epiphora, a condition in which tears accumulate to the point that they drain down the face. The two main categories of lacrimal obstruction are anatomic and functional. *Anatomic obstructions* are complete blockages, most commonly observed be-

tween the lacrimal sac and nasal cavity (Figure 1). *Functional obstructions* are caused either by critical narrowing within the lacrimal system that delay normal lacrimal flow or by a failure of the proximal pumping mechanism. Anatomic obstructions are more common than functional obstructions by a ratio of 70% to 30%. Both anatomic and functional obstructions may be managed with endoscopic DCR; however, anatomic obstructions are noted to have superior outcomes¹.

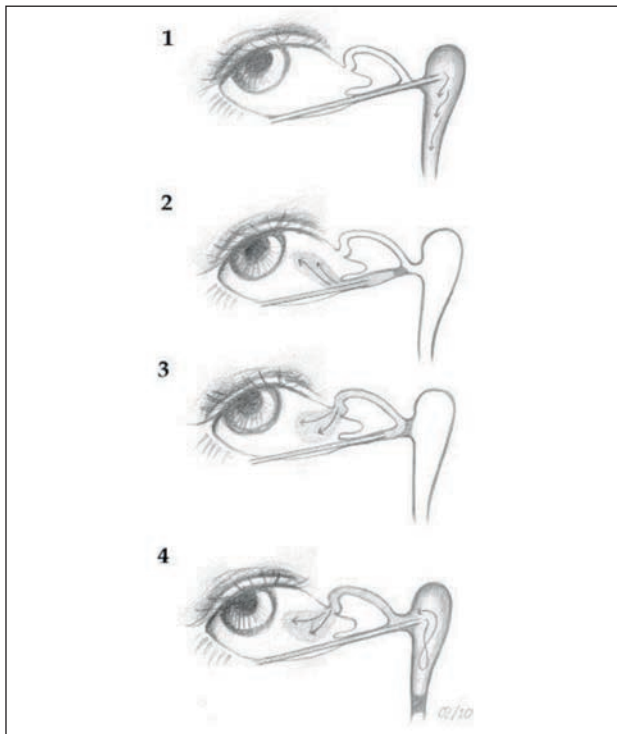


Figure 1 Location of obstruction: 1, no obstruction; 2, presaccal obstruction (stenosis of the inferior canaliculus); 3, presaccal obstruction (stenosis of the common canaliculus); 4, saccal or postsaccal obstruction (stenosis in the lower lacrimal pathway)

First endoscopic techniques used were described in 1986 by Draf (microscopic dacryocystorhinostomy), followed by Metson in 1990 who performed the first endoscopic laser DCR², and in 1991 Massaro opened for the first time the lacrimal sac using a drill. The most frequent causes of nasal lacrimal duct obstruction are: repeated inflammations of the lacrimal apparatus, repeated stenting, cranio-facial trauma, post radiation fibrosis, nasal tumors, disjunction of the lacrimal duct after endoscopic surgery, lesions of the lacrimal duct after rhinoplasty. Lacrimal clearance (i.e. the elimination of tears from the conjunctival cul-de-sac) relies on several factors, such as gravity, capillary attraction forces, evaporation, absorption by the conjunctival surface, residual (Krehbiel) flow and the lacrimal “pump”. Although some controversy exists concerning the exact mechanism of the latter, most studies agree that it relies on the action of the orbicularis oculi muscle³.

MATERIAL AND METHODS

Twenty patients with unilateral chronic obstruction of the lacrimal apparatus have been admitted in “Prof. Dr. D. Hociota” Institute of Phono-Audiology and Functional ENT Surgery – Department I, between January 2015 and July 2015, and underwent surgery – endoscopic DCR with stomal stent positioning. Two main

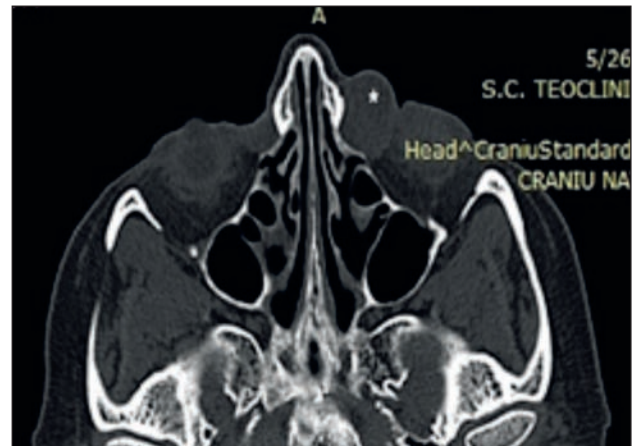


Figure 2 Cranio-facial CT scan for the left lacrimal sac

components are included into the diagnostic evaluation of the patient who comes to medical attention with epiphora: physical and radiologic examinations.

The most commonly used imaging techniques are computed tomography, dacryocystography, radionuclide dacryoscintigraphy, magnetic resonance imaging and dynamic magnetic resonance dacryocystography (Figure 2).

The greatest challenge to achieve excellent DCR outcomes is the complete extirpation of bone from the medial aspect of the lacrimal sac. Firstly, it is of utmost importance that the tip of the Bowman cannula should lie in the lacrimal sac. Secondly, the area has to be visualized with a 0⁰ endoscope, and a vertical incision in the mucosa is made in front of the lacrimal ridge (Figure 3); this should correspond to a point on the agger nasi approximately 6 mm anterior to the junction of the middle turbinate with the lateral wall. The mucoperiosteum is elevated off the bone and a portion of the lacrimal bone is resected using a drill. The window in the bone has to be of 3-4 mm in diameter. A sickle knife is used to cut down the lacrimal sac and make room for the stent to be placed⁴.

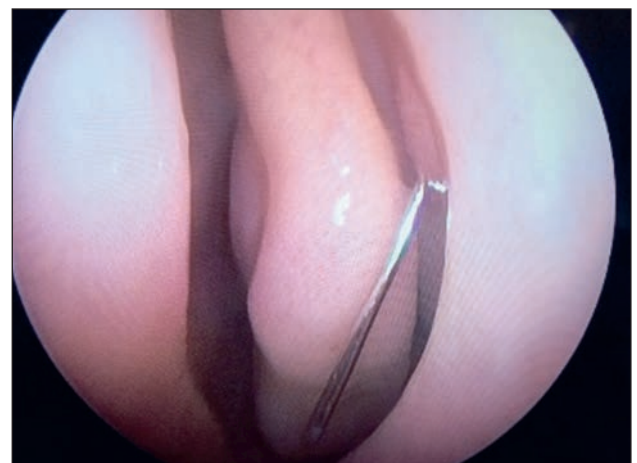

Figure 3 Left lacrimal ridge

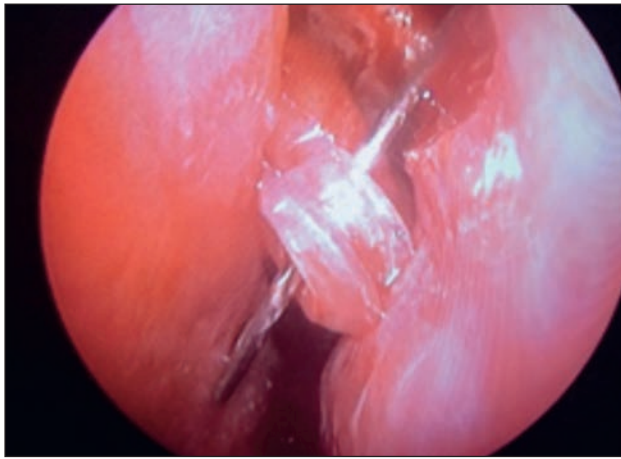


Figure 4 Intraoperative view - 3 mm stent insertion

To achieve haemostasis and prevent scar formation, various materials, such as topical haemostatic sealants, dissolvable foam and non resorbable packs, have been placed in the middle meatus after endoscopic nasal surgery. However, no controlled studies have been performed that demonstrate the superiority of a particular technique (endoscopic DCR, ophthalmologic silicone stents, T-tube for dacryocystorhinostomy) or the effect of these procedures on scar formation⁵. Dimensions of the stent used varied between 1 – 4 mm and it was left in place for several weeks (Figure 4). The success rate was 90%. It is indisputable that postoperative care has a major influence on the healing process and plays an important role in the success or failure of dacryocystorhinostomy. Postoperative care options include the administration of systemic antibiotics or a combination of antibiotic-steroid eye drops, local irrigation of the rhinostomy site with a saline solution nasal spray, intranasal steroids and debridement of the intranasal wound.⁶

Guidelines of the Royal College of Ophthalmologists indicate that the follow-up time for patients with silicone stenting should be at least 3 months. Tubes used by ophthalmologists have a diameter between 1-1.5 mm, whereas tubes used in this study varied between 1 and 4 mm diameter. The outcome of dacryocystorhinostomy may decline in long-term follow-up⁷. In this prospective study, the patients underwent four follow-up visits, in which epiphora has been assessed: at 2 weeks, and at 1, 3 and 6 months after the operation. The results of this study indicated that scar formation was a slow process, and, thus, a long-term follow-up even beyond 6 months after dacryocystorhinostomy may be necessary to detect late complications. Stents used may be a great alternative method for silicone stents⁸ (Figure 5).

RESULTS

The age of the patients varied between 31 and 65 years old. There was a significant difference in sex-ratio (14 women and 6 men), but there were no differences between the two sides (11 stenosis on the left side and 9 on the right). In a number of 16 patients epiphora has disappeared, with complete recovery, in 2 patients it has diminished and in 2 patients there has been no modification. Blockage of the nasolacrimal duct can be treated by creating a direct opening from the lacrimal sac into the nasal cavity. The novelty relies in trying to keep the ostium open as long as possible. Therefore, a stent can be positioned either in the lacrimal sac or next to the bony margin of the ostium (Figure 6).

Dacryocystorhinostomy was performed in a total of 20 patients, applying a stent of various sizes. 16 patients eliminated the stent 2-3 months after the surgery. 2 patients had the stent removed spontaneously

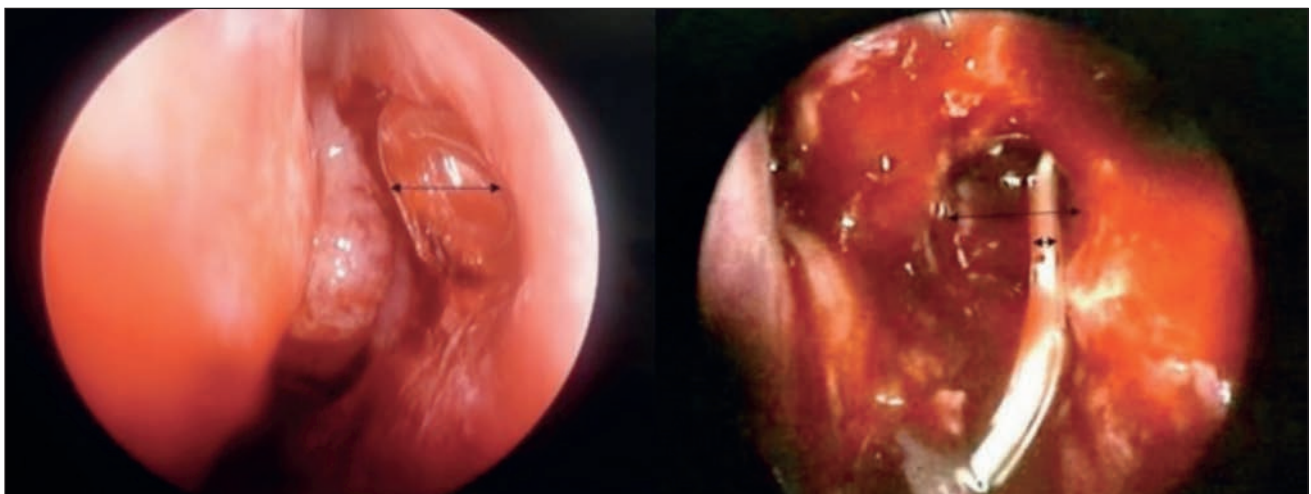


Figure 5 Difference between stents – intraoperative view

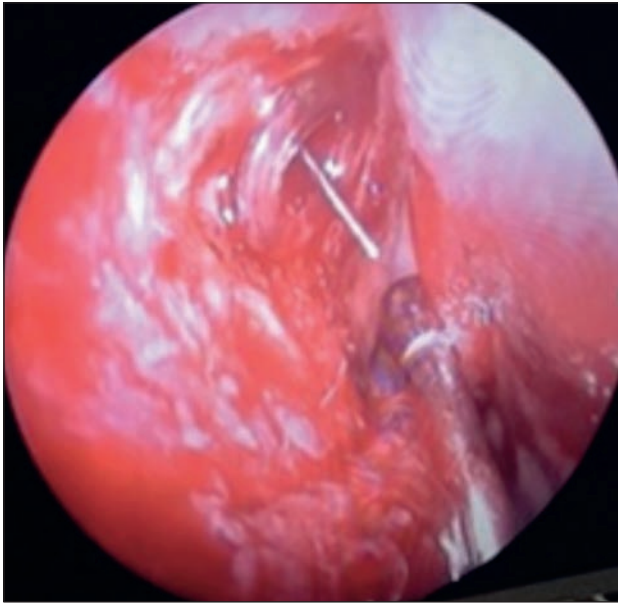


Figure 6 Lacrimal cannula and stent in position

6 weeks after endoscopic DCR with narrowing of the new created ostium. In 2 patients the stent was removed and restenosis appeared in the first 2 weeks after surgery. These last 2 patients suffered a new intervention in the first month and two stents with a larger size were applied, with better results. The most frequently used stent size was the 3 mm diameter (Figure 7).

DISCUSSIONS

In the lacrimal pathway stenosis (mostly inflammatory), the endoscopic DCR is the gold standard for saccal and postsaccal stenosis. The key point of the surgical success is to create an appropriate stoma between the lacrimal sac and the nasal cavity and to assure its patency. In our series, the surgical technique was to place a two-edged stent in the new created dacryocystorhinostomy in order to maintain a physiological lacrimal flow.

It is important to maintain the stent into the ostium at least six weeks, whilst a fibrous annulus is formed at the bottom of the lacrimal sac, so the possibility of restenosis decreases. Thus, the 16 patients who eliminated the stent 2-3 months later had regular check-ups at 1-3-6-8 weeks. The formation of a fibrous annulus correlated with a favourable outcome after surgery.

It should be mentioned that the two patients with complete restenosis had a special situation before the surgery: one patient suffered facial trauma involving the lacrimal apparatus, and the other one underwent a resection surgery of the lacrimal sac. Fitting a larger stent (3 mm) has been successfully completed. According to certain studies, the question is whether it

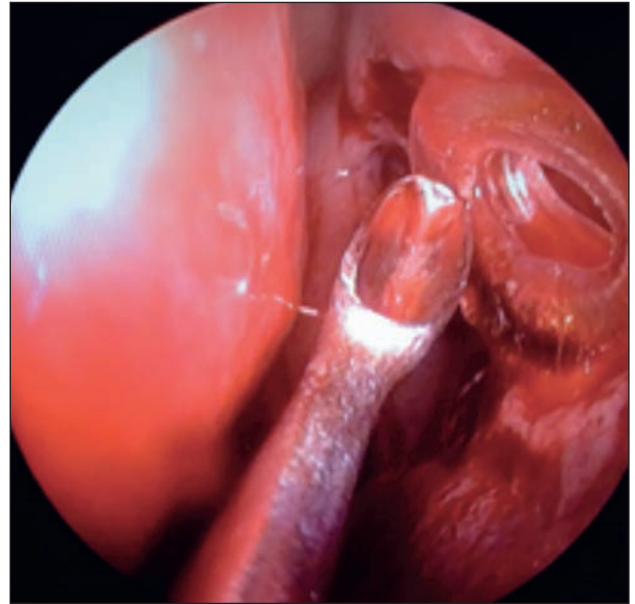


Figure 7 Final position for the stent

requires a local therapy with mitomycin C to maintain the ostium open for a longer time⁹.

While maintaining this ostium wide open, the problem of the colonization of the lacrimal canal with various pathogens of the nose (coagulase-negative staphylococcus, *Staphylococcus aureus*) appears. Some authors affirm the presence of postoperative infections one year after the surgery¹⁰.

Future studies should be directed at research projects related to wound healing and regulation of inflammation and fibrosis in the nasal mucosa, which might reveal novel predictors of outcomes for surgeries in the nasal cavity. These studies are needed to clarify whether these predictors have any implications for operative techniques and for preoperative and postoperative treatments in patients with nasal lacrimal duct obstruction¹¹.

CONCLUSIONS

Endoscopic dacryocystorhinostomy may be an effective minimum invasive procedure in patients with saccal and postsaccal obstructions of the lacrimal pathway, with a rate of success of 90%. This new stenting technique may represent the key to a long-term ostium breach. It is easily understood and accepted by the patient; it can also be performed under local anaesthesia and has no major complications.

In the future, it is necessary to establish the best material for the stent and set a standard stent dimension for an adult in order to have a minimum risk of stenosis. There is also a definite need to create generally accepted and cost-effective clinical treatment protocols for patients with nasal lacrimal duct obstruction.

Acknowledgements: This paper is conducted during a private funding research programme entitled “Biotechnological methods of preserving dacryorhinostomy in the lacrimal apparatus stenosis”.

Conflict of interest: The authors have no conflict of interest.

Contribution of authors: All authors have equally contributed to this work.

REFERENCES

1. Flint P.W., Hughey B.H. - Cummings Otolaryngology: Head and Neck Surgery, Elsevier, Philadelphia, 2015;p.816.
2. Metson R., Wooq J.J., Puliafito C.A. - Endoscopic laser dacryocystorhinostomy. Laryngoscope, 1994;104(3 Pt 1):269-274.
3. Detorakis E.T., Zissimopoulos A., Ioannakis K., Kozobolis V.P. - Lacrimal Outflow Mechanisms and the Role of Scintigraphy: Current Trends. World J Nucl Med., 2014;13(1):16-21. doi: 10.4103/1450-1147.138569.
4. Budu V., Schnaider A., Bulescu I. - Endoscopic DCRS – indications, surgery and potential complications. Archives of the Balkan Medical Union, 2014;49(4):548-550.
5. Erkan A.N., Yilmazer C., Altan – Yaycioglu R. - Otolgic T-tube in endonasal dacryocystorhinostomy: a new approach. Acta Otolaryngol., 2007;127(12):1316-1320.
6. Penttila E., Smirnov G., Tuomilehto H., Kaarniranta K., Seppa J. - Endoscopic dacryocystorhinostomy as treatment for lower lacrimal pathway obstructions in adults: Review article. Allergy Rhinol (Providence), 2015;6(1):e12–e19.
7. Penttila E., Smirnov G., Seppa J., et al. - Validation of a symptom-score questionnaire and long term results of endoscopic dacryocystorhinostomy. Rhinology, 2014;52:84–89.
8. Erkan A.N., Yilmazer C., Altan – Yaycioglu R., Akkuzu B., Aktaş L. - Bicanalicular silicone tubes versus otologic T-tubes in endonasal dacryocystorhinostomy. B-ENT., 2008;4(3):135-139.
9. Kao C.S., Liao C.L., Tseng J.H., Chen M.S., Hou P.K. - Dacryocystorhinostomy with intraoperative mitomycin C. Ophthalmology, 1997;104(1):86–91.
10. Başal Y., Güleç G., Ertuğrul B., Eryilmaz A., Günel C., Başak S. - Changes in nasal flora one year after endoscopic dacryocystorhinostomy. B-ENT., 2015;11(2):129-34.
11. Xue K., Mellington F.E., Norris J.H. - Meta-analysis of the adjunctive use of mitomycin C in primary and revision, external and endonasal dacryocystorhinostomy. Orbit, 2014;33:239–244.

© 2016 Vlad Budu, Tatiana Decuseara, Bogdan Mocanu, Raluca Baican, Mihai Tusaliu, Diana Cojocaru, Ion Bulescu, published by Romanian Rhinologic Society



This is an open access article published under the terms and conditions of the Creative Commons Attribution-NonCommercial-NoDerivatives 4.0 International (CC BY-NC-ND 4.0) License (<https://creativecommons.org/licenses/by-nc-nd/4.0/>). CC BY-NC-ND 4.0 license requires that reusers give credit to the creator by citing or quoting the original work. It allows reusers to copy, share, read, download, print, redistribute the material in any medium or format, or to link to the full texts of the articles, for non-commercial purposes only. If others remix, adapt, or build upon the material, they may not distribute the modified material.