

CASE REPORT**Odontogenic myxoma invading the maxillary sinus –
Case presentation****Dan Cristian Gheorghe¹, Adina Zamfir-Chiru-Anton²**¹ENT Department, “M.S. Curie” Children Hospital, “Carol Davila” University of Medicine and Pharmacy, Bucharest, Romania²ENT Department, “G. Alexandrescu” Emergency Hospital for Children, Bucharest, Romania**ABSTRACT**

Tumors of the maxillary sinus pose difficult challenges in a young patient. Our paper presents a very rare case of an odontogenic myxoma extended to the maxillary sinus, in a 14-year-old girl. The clinical picture suggested a malignancy or a local infection. The surgical removal was complete and the diagnosis was confirmed by immunohistochemistry. Discussions are made from the perspective of already published cases. A review of the disease is performed.

CONCLUSION. Myxoma is a benign but aggressive tumor, needing complete surgical excision for a good long-term outcome.

KEYWORDS: osteogenic myxoma, maxillary sinus, children

INTRODUCTION

Myxoma arising in the facial bones is a rare tumor. Its incidence is reported at 0,07/1,000,000/year¹. The second and third decades of life are mostly affected and most studies report a slightly female predilection². The clinical picture can go from asymptomatic to malignant evolution cases³. The differential diagnosis includes fibrous dysplasia, odontogenic cysts, fibromas and giant cell tumors¹. Treatment options are scarce, but almost all authors suggest surgery¹, although long-time prognosis is unknown, recurrences being rather common⁴.

CASE REPORT

A 14-year-old girl without any previous history of sinus disease presented with a maxillary swelling on her right face, without nasal complaints. Clinical ex-

amination revealed a moderate congestion of the ipsilateral infraorbital region, with pain elicited by compression. No cystic sensation on palpation was noted. Both upper right premolar teeth presented abnormal mobility. No ocular symptoms were noted.

The cranio-facial CT scan of the child showed a right maxillary sinus completely occupied by a soft tissue mass, with irregular density easily noticed in all images. No MRI has been performed. Abnormal position of some teeth could be observed and also the destruction of the anterior, medial and inferior walls of the maxillary sinus (Figure 1).

Under general anaesthesia, the Caldwell-Luc incision was used to access the right maxillary tumor. The anterior bony part of the maxilla was absent and the sinus cavity was filled with a white cartilaginous-like tissue, shaped like columns separated by fine residual sheets of bone. The entire sinus cavity was heavily packed with tumor tissue. Apparently, we managed to remove all of it, guarding the integrity of the poste-

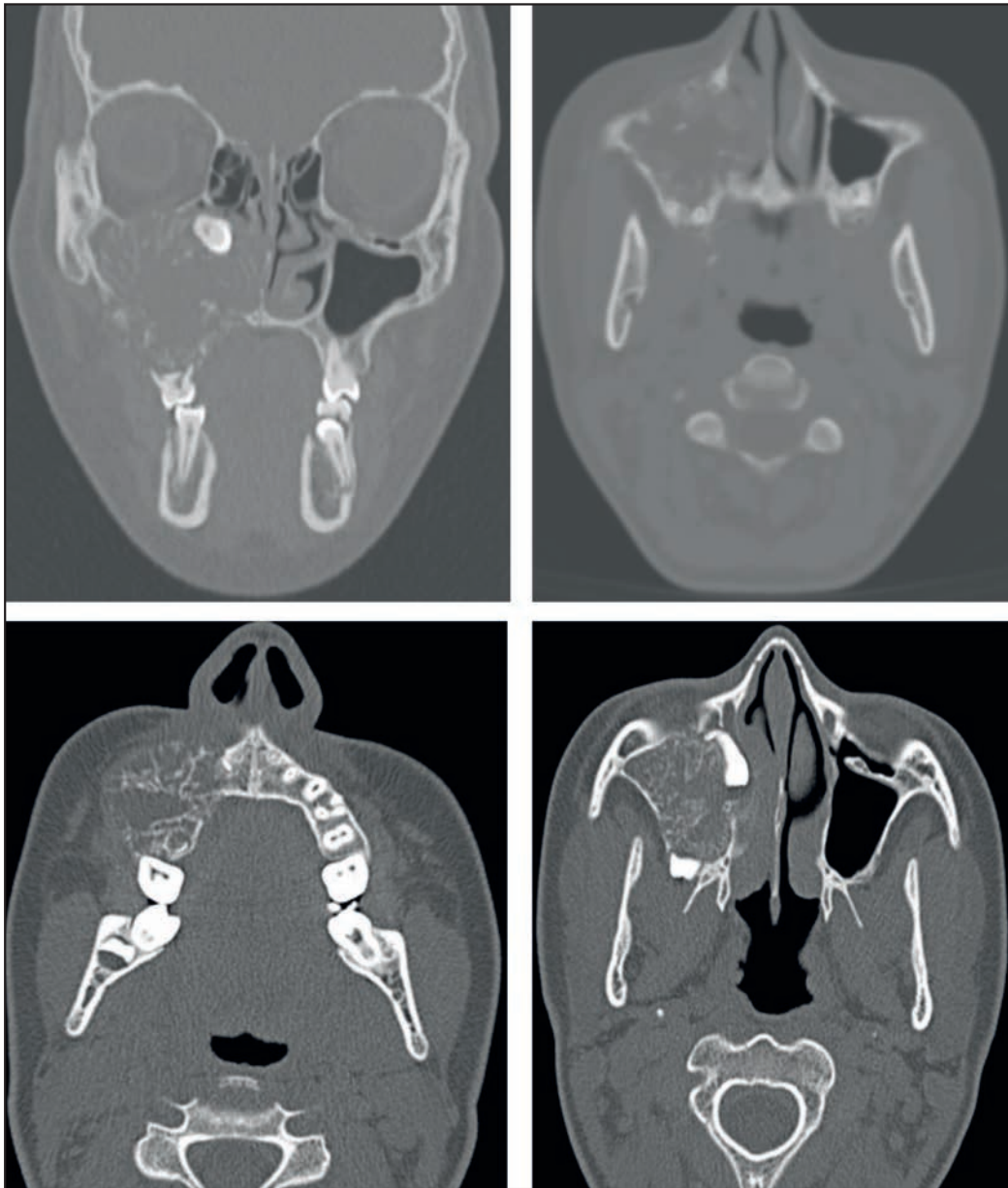


Figure 1 Preoperative cranio-facial CT scan (coronal and axial slices) – soft tissue mass occupying the right maxillary sinus; erosion of the anterior, medial and inferior maxillary walls

rior, superior and lateral walls. An inferior meatal sinus opening was created, posteriorly from the nasolacrimal duct in the inferior nasal meatus.

Intraoperative histology suggested the presence of a chordoma, but the paraffin-embedded material later showed the existence of an odontogenic myxoma. Immunohistochemistry confirmed the diagnosis.

A minor congestion and pain persisted postoperatively under the inferior orbital rim, for at least 1 month. Persistent rhinorrhea was also noted in the early follow-up period, persisting at least 1 month after surgery.

The patient was recalled for further evaluations by MRI and close monitoring.

DISCUSSIONS

Myxoma is a rare mesenchymal tumor, with benign histologic appearance. Its cause is unknown. Most of the cases studied have brought data for this tumor to be of odontogenic origin⁵. Most of them have been described in the mandible⁶. The first maxillary case was reported by Thoma and Goldman in 1947^{7,8}. Due to the maxillary invasion, our presented case suggested a paranasal sinus malignancy at first, rather than a benign odontogenic disease.

The published literature on the subject mentions an asymptomatic, slow-growing tumor⁷. In our case, symptoms were noted just 3 weeks before presenta-

tion. It is possible that a longer period for tumor development had passed before the admission in our Department. That would be in accord with other reports, where most myxomas account for late presentation. Our patient described pain and facial asymmetry at the diagnosis moment.

The imagistic appearance of the myxomas varies: clear bubbles, honey comb and intralobular trabeculation are also possible⁹. Unilocular or multilocular diseases are possible. The CT scan usually shows the extent of the tumor, while the MRI can demonstrate surrounding tissues invasion².

The histologic appearance of osseous myxoma is typical: spindle and stellate cells within a myxomatous stroma. Our case showed the same type of cells that stained S100 and ACT frequently positive, AE1-AE3 and Ki67 negative, thus supporting the diagnosis. We also discovered intraoperatively many bone islands inside the tumor, probably representing residual osseous trabeculae. This aspect has also been described in other papers¹⁰. We could not elicit a clear capsule of the tumor, but we found instead a compression development with bone resorption (of the anterior maxillary sinus wall). The mass effect was obvious even on the CT scan images, where we could also observe that a tooth had been pushed near the superior margin of the inferior concha. This aspect has already been observed in other studies as well².

CONCLUSIONS

Odontogenic myxoma of the maxilla is a rare disease with a locally aggressive course. It can sometimes simulate malignant tumors. Imaging is important for supporting the diagnosis. Surgical approach is the only treatment described. Recurrences are frequent if the excision is not complete. Long-term monitoring of the patients is mandatory.

Conflict of interest: The authors have no conflict of interest.

Contribution of authors: All authors have equally contributed to this work.

REFERENCES

1. Simon E.N., Merck M.A., Vuhahula E., Nqassapa D., Stoelinga P.J. - Odontogenic myxoma: a clinicopathological study of 33 cases. *Int J Oral Maxillofac Surg.*, 2004;33(4):333-337.
2. Kheir E., Stephen L., Nortje C., van Rensburg L.J., Titinchi F. - The imaging characteristics of odontogenic myxoma and a comparison of three different imaging modalities. *Oral Surg Oral Med Oral Pathol Oral Radiol.*, 2013;116(4):492-502. doi: 10.1016/j.oooo.2013.05.018. Epub 2013 Aug 20.
3. Pahl S., Henn W., Binger T., Stein U., Remberger K. - Malignant odontogenic myxoma of the maxilla: case with cytogenetic confirmation. *J Laryngol Otol.*, 2000;114(7):533-535.
4. Landa L.E., Hedrick M.H., Nepomuceno-Perez M.C., Sotereanos G.C. - Recurrent myxoma of the zygoma: a case report. *J Oral Maxillofac Surg.*, 2002;60(6):704-708.
5. Veras Filho Rde.O., Pinheiro S.S., Almeida I.C., Arruda Mde.L., Costa Ade.L. - Odontogenic myxoma of the maxilla invading the maxillary sinus. *Braz J Otorhinolaryngol.*, 2008;74(6):945.
6. Fenton S., Slootweg P.J., Dunnebie E.A., Mourits M.P. - Odontogenic myxoma in a 17-month-old child: a case report. *J Oral Maxillofac Surg.*, 2003;61(6):734-736.
7. Carvalho de Melo A.U., de Farias Martorelli S.B., Cavalcanti P.H., Gueiros L.A., Martorelli Fde.O. - Maxillary odontogenic myxoma involving the maxillary sinus: case report. *Braz J Otorhinolaryngol.*, 2008;74(3):472-475.
8. Thoma K.H., Goldman H.M. - Central myxoma of the jaw. *Oral Surg Oral Med Oral Pathol.*, 1947;33(7):B532-B540.
9. Peltola J., Magnusson B., Happonen R.P., Borrmann H. - Odontogenic myxoma—a radiographic study of 21 tumours. *Br J Oral Maxillofac Surg.*, 1994;32(5):298-302.
10. Oygur T., Dolanmaz D., Tokman B., Bayraktar S. - Odontogenic myxoma containing osteocement-like spheroid bodies: report of a case with an unusual histopathological feature. *J Oral Pathol Med.*, 2001;30(8):504-506.

