

## CASE REPORT

# Bilateral infraorbital maxillary air cells: recess-derived non-Haller cells

Mugurel Constantin Rusu<sup>1</sup>, Andrei Leonid Chirita<sup>1</sup>, Mihai Sandulescu<sup>2</sup>

<sup>1</sup>Division of Anatomy, Faculty of Dental Medicine, “Carol Davila” University of Medicine and Pharmacy, Bucharest, Romania

<sup>2</sup>Division of Oral Implantology, Faculty of Dental Medicine, “Carol Davila” University of Medicine and Pharmacy, Bucharest, Romania

## ABSTRACT

**BACKGROUND.** The infraorbital recess of the maxillary sinus can reach in front of the nasolacrimal duct to become prelacri-mal recess. During a routine Cone Beam CT (CBCT) study of a male patient of 72 years old, there were bilaterally found infra-orbital maxillary air cells (IMACs) resulted after the almost complete closure of infraorbital recesses of the maxillary sinuses. Only that on the left side was reaching in front of the nasolacrimal canal. The closure of each infraorbital recess led to a narrow draining passage opened in the terminal end of the maxillary infundibulum, thus proximal to the maxillary sinus ostium. On the left side, a small cell of the lacrimal bone was interposed between the IMAC drainage pathway and the nasolacrimal canal. On the right side, the nasolacrimal canal was communicating with the ethmoidal infundibulum. Such an anatomic variation in the infraorbital angle of the maxillary sinus can impede the endoscopic procedures which use the anterior lacrimal pathway.

**KEYWORDS:** maxillary sinus, cone beam computed tomography, CBCT, nasolacrimal duct

## INTRODUCTION

Anatomic variations of the nasal fossa are extremely important for the otolaryngologists performing functional endoscopic sinus surgery<sup>1</sup>. Radiologists must also know the anatomic possibilities of variation in their preoperative evaluation<sup>2</sup>.

The endoscopic sinus surgeons must be aware of the drainage pattern of the maxillary sinus, the maxillary sinus ostium being closely related to the nasolacrimal canal, ethmoidal infundibulum and orbit floor<sup>3</sup>.

The anatomic variation of pneumatizations in the pterygopalatine angle of the maxillary sinus seems better documented<sup>4,6</sup> than the variation in the infraorbital (antero-supero-medial) angle of the sinus.

The drainage of the maxillary sinus is ensured by successive anatomical structures: maxillary infundibulum, main ostium of the maxillary sinus, ethmoidal infundibulum and, finally, the hiatus semilunaris superior<sup>7</sup>. This anatomic pathway can be modified by variable pneumatizations, such as recesses of the maxillary sinus, which expand either in the orbit floor on the

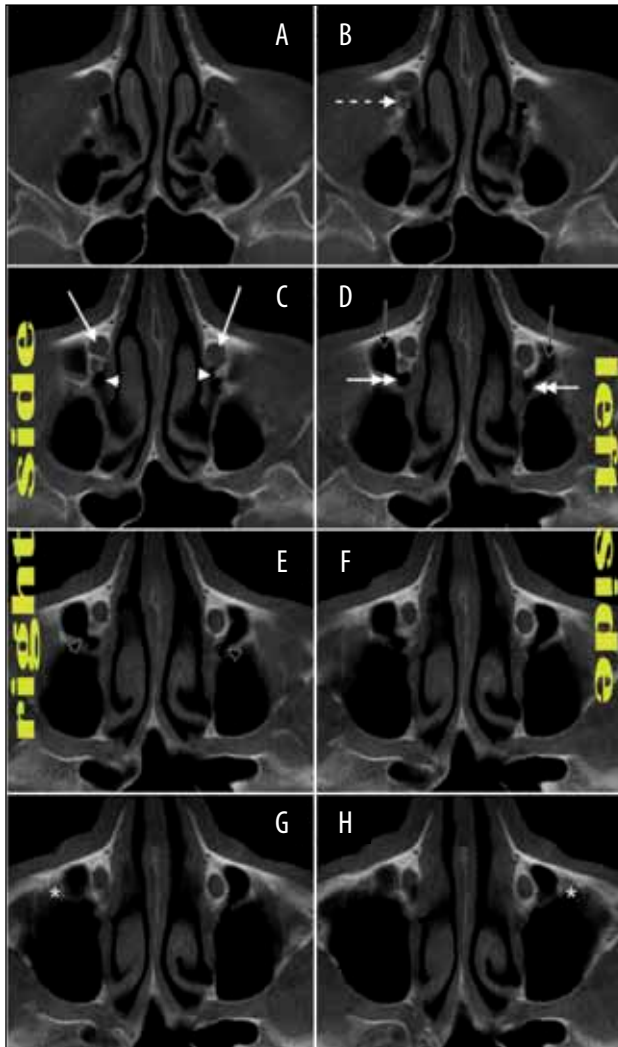
inner side of the infraorbital canal (infraorbital recesses), or within the ethmoid (ethmoidal recesses)<sup>7</sup>. A rare occurrence (3%) of the infraorbital recess of the maxillary sinus was reported<sup>8</sup>.

## CASE REPORT

A cone beam computed tomography (CBCT) case study was performed in a 72-year-old male patient for dental medical purpose. The subject was scanned using a CBCT machine – iCat (Imaging Sciences International), and the CT data were analysed using the iCatVision software and the application 3DVR v5.0.0.3, for the three-dimensional volume renderizations (3D VRs), the specific protocol being described elsewhere<sup>5</sup>. The anatomical patterns were studied bilaterally on bidimensional multiplanar reconstructions (MPRs) in the axial, coronal and sagittal planes, as well as on three-dimensional volume renderizations resulted after applying the filter *Transparent Skin*, in which the transparency of air spaces was maximal and that of the bone was minimal.

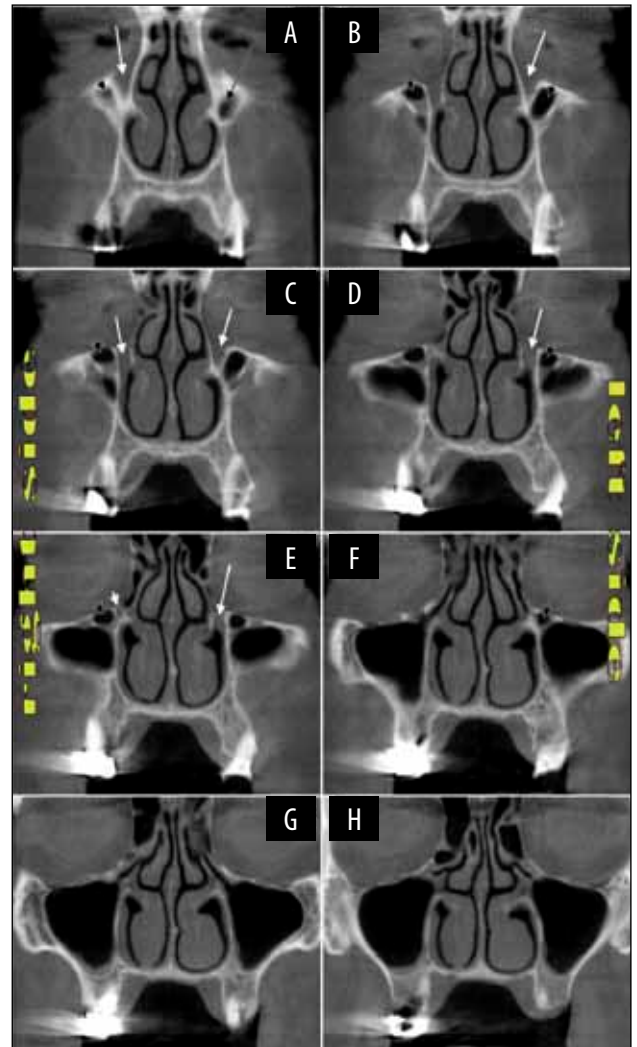
In that case, a distinctive air chamber of the maxillary bone was bilaterally encountered, in the situs of the infraorbital recess of the maxillary sinus, on the inner side of the infraorbital canal (Figures 1-4). That air cell was neither deriving from the ethmoid bone, nor from the frontal bone. It was termed “*infraorbital maxillary air cell (IMAC)*” and on 3D VRs it appeared (Figures 3,4) as an accessory mini-sinus in the infraorbital (antero-supero-medial) angle of the maxillary sinus.

The IMAC was separated from the main chamber of the maxillary sinus by an almost complete septum, which only allowed a narrow drainage pathway. That septum was partly osseous and partly membranous (Figure 1C,D,E).

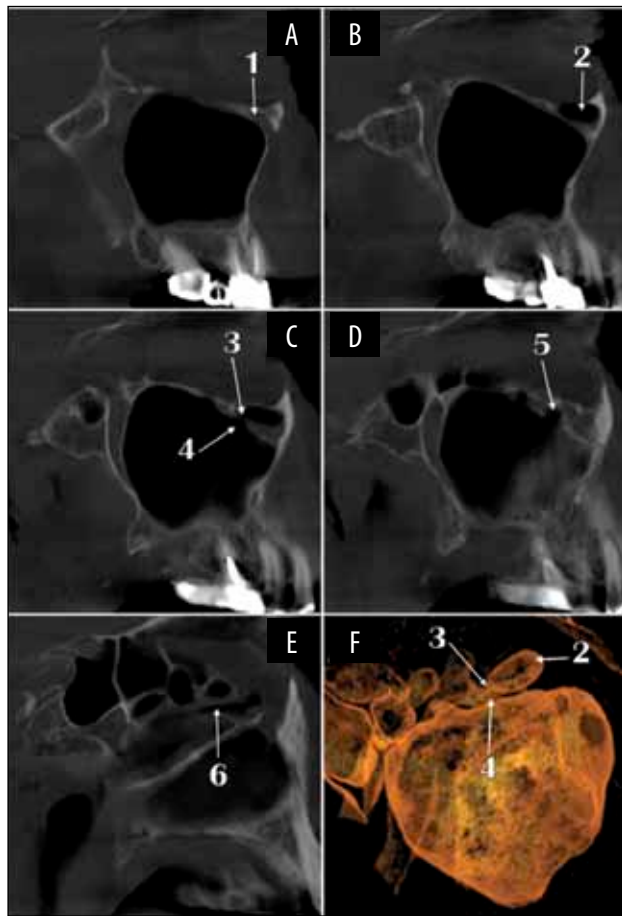


**Figure 1** Cone Beam CT, axial multiplanar reconstructions, in a superior-to-inferior sequence (A-H). There are indicated the nasolacrimal canal (white arrow), the ethmoidal infundibulum (white arrowhead) and, on each side, infraorbital maxillary air cells (IMAC, black arrow) draining into the distal end of the maxillary infundibulum (double-headed white arrow) via a narrow passage (black arrowhead). The IMAC lies medially to the infraorbital canal (\*). On the right side, a cell of the lacrimal bone located immediately behind the nasolacrimal canal, is identified (B, dashed white arrow). This one, on the right side, as well as the left nasolacrimal canal, communicates with the ethmoidal infundibulum (C).

On each side, the ostium of the maxillary sinus was found immediately posterior to the nasolacrimal canal, and was opened in the ethmoidal infundibulum (Figures 1,3,4). Into the right ethmoidal infundibulum, a cell of the lacrimal bone was also found opened, being located immediately posterior to the respective nasolacrimal canal (Figure 1B,E; Figure 2D,E). The left nasolacrimal canal had a minute opening in the ethmoidal infundibulum (Figure 1D). On the left side, the IMAC was extended in front of the nasolacrimal canal (Figure 4H, prelacrimal recess). On the right side, the IMAC kept a lateral position to the nasolacrimal canal (Figure 1E).



**Figure 2** Cone Beam CT, coronal multiplanar reconstructions, in an anterior-to-posterior sequence (A-H). There are identified the nasolacrimal canals (white arrow), the right infraorbital maxillary air cell (black arrowhead), the left infraorbital maxillary air cell (black arrow), as well as, on the right side, a lacrimal bone cell located immediately posterior to the nasolacrimal canal (white arrowhead).



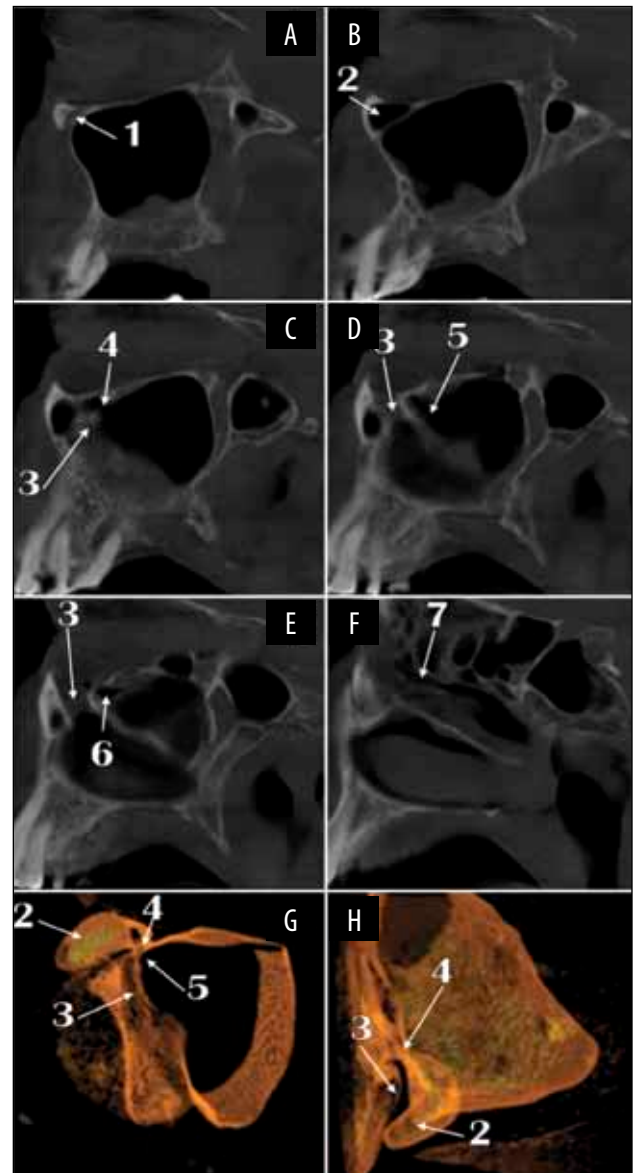
**Figure 3** Cone Beam CT, sagittal multiplanar reconstructions, in a lateral-to-medial sequence (A-E), on the right side. The air spaces on that side are presented in a three-dimensional volume rendering (F), viewed postero-infero-laterally. 1. right infraorbital canal; 2. right infraorbital maxillary air cell (rIMAC); 3. narrow passage of drainage of the rIMAC; 4. maxillary infundibulum; 5. ostium of maxillary sinus; 6. ethmoidal infundibulum.

Each maxillary sinus was narrowing towards the ostium to form the maxillary infundibulum (Figures 2G, 2H, 3F, 4G). On each side, the IMAC was opened into the terminal end of the maxillary infundibulum by a narrow passage, immediately proximal to the maxillary sinus ostium (Figures 1E, 3, 4).

## DISCUSSIONS

Most studies dealing with the recesses of the maxillary sinus focus on the sinus floor and the alveolar recesses and septa, which are subjected to dental implants placement and the need of sinus floor elevation<sup>9-13</sup>. This is in accord with the observation of Underwood (1910) that the majority of the maxillary sinus septa raise from the sinus floor<sup>14</sup>.

There is little information available on other different recesses of the maxillary sinus, although outgoing pneumatizations can occupy spaces in all the bones surrounding the maxillary bone, such as the sphenoid



**Figure 4** Cone Beam CT, sagittal multiplanar reconstructions, in a lateral-to-medial sequence (A-F), on the left side. The air spaces on that side are presented in three-dimensional volume renderizations, viewed antero-laterally (G) and from above (H). 1. left infraorbital canal; 2. left infraorbital maxillary air cell (lIMAC); 3. nasolacrimal canal; 4. drainage of the lIMAC in the maxillary infundibulum; 5. maxillary infundibulum; 6. ostium of maxillary sinus; 7. ethmoidal infundibulum.

and ethmoid bones and the inferior turbinate<sup>5,6,15</sup>. On axial cuts, the position of the infraorbital recess as referred to the nasolacrimal duct was used to classify the maxillary sinuses into two types: lateral, in which the sinus extension does not reach the pre-lacrimal situs, and anterior, in which the infraorbital recess becomes a pre-lacrimal one<sup>16</sup>. A variant of these two sinus types was presented here, the right IMAC being derived from a lateral sinus type, and the left IMAC corresponding to an anterior sinus type.

The infraorbital recess of the maxillary sinus, as well as its extreme variant, the IMAC presented here, would

rather influence the lower lacrimal drainage pathway and the associated pathology and treatment. It should not be ignored that such an almost completely closed IMAC closely related to the nasolacrimal duct is a poorly drained cavity, which is subject to local inflammation that, in turn, could lead to transient nasolacrimal obstruction.

Moreover, the dacryocystantrostomy, in which the lacrimal sac is drained into the maxillary sinus in patients with epiphora<sup>17</sup>, should be technically adapted if such patients present with an IMAC, to avoid emptying the nasolacrimal duct into a small and poorly drained cavity.

It should not be ignored that endoscopic maxillary sinus surgery used for treating benign lesions of the maxillary sinus could prefer the pre-lacrimal recess approach; in such situations, an interposed IMAC would not allow for an adequate antral access, if the entrance is via the middle meatus. An inferior antrostomy should be preferred in such cases.

## CONCLUSIONS

The almost completely closed infraorbital recess of the maxillary sinus becomes an infraorbital maxillary air cell, prone to inflammation and, on other hand, to surgical damage if endonasal sinus approaches use the prelacrima pathway, via the middle meatus.

**Conflict of interest:** The authors have no conflict of interest.

**Contribution of authors:** All authors have equally contributed to this work.

## REFERENCES

1. Kayalioglu G., Oyar O., Govsa F. - Nasal cavity and paranasal sinus bony variations: a computed tomographic study. *Rhinology*, 2000;38:108-113.
2. Kantarci M., Karasen R.M., Alper F., Onbas O., Okur A., Karaman A. - Remarkable anatomic variations in paranasal sinus region and their

clinical importance. *Eur J Radiol.*, 2004;50:296-302.

3. Prasanna L.C., Mamatha H. - The location of maxillary sinus ostium and its clinical application. *Indian J Otolaryngol Head Neck Surg.*, 2010;62:335-337.
4. Rusu M.C., Sandulescu M., Derjac-Arama A.I. - The pterygopalatine recess of the superior nasal meatus. *Surg Radiol Anat.*, 2016; 10.1007/s00276-016-1632-y.
5. Craiu C., Rusu M.C., Hostiuc S., Sandulescu M., Derjac-Arama A.I. - Anatomic variation in the pterygopalatine angle of the maxillary sinus and the maxillary bulla. *Anat Sci Int.*, 2015; 10.1007/s12565-015-0320-z.
6. Rusu M.C., Didilescu A.C., Jianu A.M., Padurarur D. - 3D CBCT anatomy of the pterygopalatine fossa. *Surg Radiol Anat.*, 2013;35:143-159.
7. Derjac-Arama A.I., Mihai S.A., Sandulescu M., Rusu M.C. - Anatomic patterns of maxillary sinus drainage. *Romanian Journal of Rhinology*, 2015;5(20):209-214.
8. Rysz M., Bakon L. - Maxillary sinus anatomy variation and nasal cavity width: structural computed tomography imaging. *Folia Morphol. (Warsz)*, 2009;68:260-264.
9. Pommer B., Ulm C., Lorenzoni M., Palmer R., Watzek G., Zechner W. - Prevalence, location and morphology of maxillary sinus septa: systematic review and meta-analysis. *J Clin Periodontol.*, 2012;39:769-773.
10. Orhan K., Kusakci Seker B., Aksoy S., Bayindir H., Berberoglu A., Seker E. - Cone beam CT evaluation of maxillary sinus septa prevalence, height, location and morphology in children and an adult population. *Med Princ Pract.*, 2013;22:47-53.
11. Kim M.J., Jung U.W., Kim C.S., et al. - Maxillary sinus septa: prevalence, height, location, and morphology. A reformatted computed tomography scan analysis. *J Periodontol.*, 2006;77:903-908.
12. Lee W.J., Lee S.J., Kim H.S. - Analysis of location and prevalence of maxillary sinus septa. *J Periodontal Implant Sci.*, 2010;40:56-60.
13. Shibli J.A., Faveri M., Ferrari D.S., et al. - Prevalence of maxillary sinus septa in 1024 subjects with edentulous upper jaws: a retrospective study. *J Oral Implantol.*, 2007;33:293-296.
14. Underwood A.S. - An inquiry into the anatomy and pathology of the maxillary sinus. *Journal of anatomy and physiology*, 1910;44:354.
15. Măru N., Rusu M., Săndulescu M. - The conchal recess of the maxillary sinus: a 100 cases CB CT study. *Romanian Journal of Functional & Clinical, Macro- & Microscopic Anatomy & of Anthropology/Revista Română de Anatomie Funcțională și Clinică, Macro și Microscopica și de Antropologie*, 2013;12.
16. Navarro Pde L., Machado A.J. Jr., Crespo A.N. - Assessment of the lacrimal recess of the maxillary sinus on computed tomography scans. *Eur J Radiol.*, 2013;82:802-805.
17. Belal A. Jr. - Dacryocystantrostomy. A preliminary report. *J Laryngol Otol.*, 1976;90:763-771.

