

CLINICAL PHOTOGRAPHS

Frontal sinus osteoma

Codrut Sarafoleanu^{1,2}, Roxana – Elena Decusara¹^{1,2}ENT&HNS Department, “Sfanta Maria” Hospital, Bucharest, Romania¹“Carol Davila” University of Medicine and Pharmacy, Bucharest

Osteomas are the most frequent benign tumors that arise in the paranasal sinuses and the nose, with a slow growing rate, that develop predominantly into the frontal sinus (80% of the sinusal localization)¹. At the beginning, small osteomas are usually asymptomatic. The clinical symptoms depend on the location and the size of the tumor¹. The most common symptom is frontal headache or facial pain. Osteomas are usually identified accidentally by radiological examinations – classical Rx or CT scan images.

From the histological point of view, there are three types of sinusal osteomas²:

- eburnated (ivory, compact type): very dense, with no evidence of haversian canals;
- mature, spongy osteomas – osseous trabeculae associated with fibrous tissue and collagen fibers;
- mixed types – contain both histological types.

The management of these tumors is divided into two main directions: *conservative*, “wait and see” attitude, in case of small, asymptomatic lesions, and *surgical treatment*³. Surgery is recommended in the following cases: rapid growth of the tumor, infections, intracranial or orbital complications that arise due to the tumor extension, severe pain⁴.

There are three types of surgery used for the treatment of this pathology: endoscopic, external or combined approach. The main purpose of the surgical

intervention is the complete excision, with minimal damage to the peritumoral tissues^{5,6}.

Transnasal excision, using endoscopic techniques are used in cases of involvement of the medial wall of the maxillary sinus, ethmoidal and sphenoidal sinuses, inferior and medial wall of the orbit, selected cases of frontal osteomas (located medially from a sagittal plane through lamina papiracea). Usually, in case of frontal osteomas, surgeons prefer techniques type Draf II or III. Although, plenty osteomas are better cured by using a combined approach⁷.

We present the case of a 45 years old female that was admitted in the ENT&HNS Department of “Sfanta Maria” Clinical Hospital, Bucharest, Romania for headache, pressure-like sensation located in the left orbita and left eye, and a mild deformity of the left frontal region. The symptoms appeared 2 years before presentation, with a slow onset and a progressive evolution.

The ENT examination revealed a round, osseous tumoral mass, located in the internal angle of the left orbit, covered with normal looking skin; endonasal aspect showed no important anatomical modifications.

The cranio-facial CT native scan revealed an inhomogeneous, well circumscribed mass with anterior ethmoidal cells with ethmoidal septa destruction, externalized into the left orbit (Figure 1).

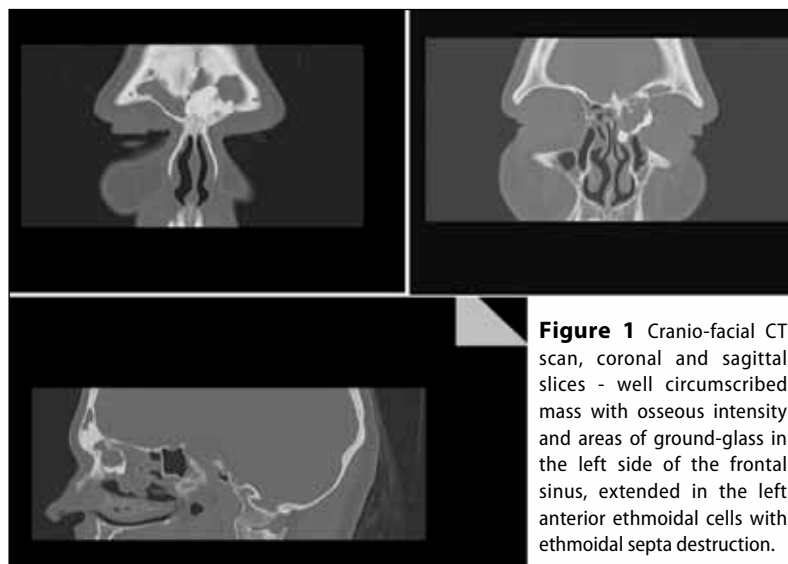


Figure 1 Cranio-facial CT scan, coronal and sagittal slices - well circumscribed mass with osseous intensity and areas of ground-glass in the left side of the frontal sinus, extended in the left anterior ethmoidal cells with ethmoidal septa destruction.

Taking into consideration the large size and the localization of the tumor, the surgical treatment consisted in an Ogston-Luc external approach, by removing the anterior wall of the left frontal sinus, revealing a round, yellow, osseous density tumoral mass. The tumor was then excised by drilling and decollated from the bony walls. Finally, the anterior wall of the frontal sinus was reconstructed using silicon prosthesis (Figure 2). A silicon drainage tube was set in place inside the frontal sinus, and externalized through *dorsum nasi*.

During the surgery, we did not encounter any major bleeding, intracranial or external complications. Post-operative evolution under general treatment (antibiotic, NSAIDs, cortisone) and local treatment of the nasal fossa was optimal, with no significant bleeding, intracranial or oculo-orbital problems.

The post-therapeutic follow-up was made at 1 month, 3 months and 6 months, by clinical and nasal endoscopy assessment and it revealed the healing of the frontal sinus and of the external incision; at 6 months post-operative, the patient underwent a CT scan, who did not show any sign of tumoral reoccurrence.

REFERENCES

1. Popescu I., Ciuce C. (edit.), Sarafoleanu C. (coord.) - *Tratat de Chirurgie. Vol 1. ORL și Chirurgie Cervico-Faciala*. Editura Academiei Romane, Bucuresti, 2012;pp.166-171.
2. Fu Y.S., Perzin K.H. - Non-epithelial tumors of the nasal cavity, paranasal sinuses, and nasopharynx. A clinicopathologic study. II. Osseous and fibro-osseous lesions, including osteoma, fibrous dysplasia, ossifying fibroma, osteoblastoma, giant cell tumor, and osteosarcoma. *Cancer*, 1974;33(5):1289-1305.
3. Lund V.J., Stammberger H., Nicolai P., et al. - European position paper on endoscopic management of tumours of the nose, paranasal sinuses and skull base. *Rhinol Suppl.*, 2010;22:1-143.
4. Ledderose G.J., Betz C.S., Stelter K., Leunig A. - Surgical management of osteomas of the frontal recess and sinus: extending the limits of the endoscopic approach. *Eur Arch Otorhinolaryngol.*, 2011;268:525-523.
5. Gil-Carcedo L.M., Gil-Carcedo E.S., Vallejo L.A., de Campos J.M., Herrero D. - Frontal osteomas: standardising therapeutic indications. *J Laryngol Otol.*, 2011;125:1020-1027.
6. Hehar S.S., Jones N.S. - Fronto-ethmoid osteoma: the place of surgery. *J Laryngol Otol.*, 1997;111:372-375.
7. Strek P., Zagólski O., Składzień J., Kurzyński M., Dyduch G. - Osteomas of the paranasal sinuses: surgical treatment options. *Med Sci Monit.*, 2007;13(5):CR244-250.

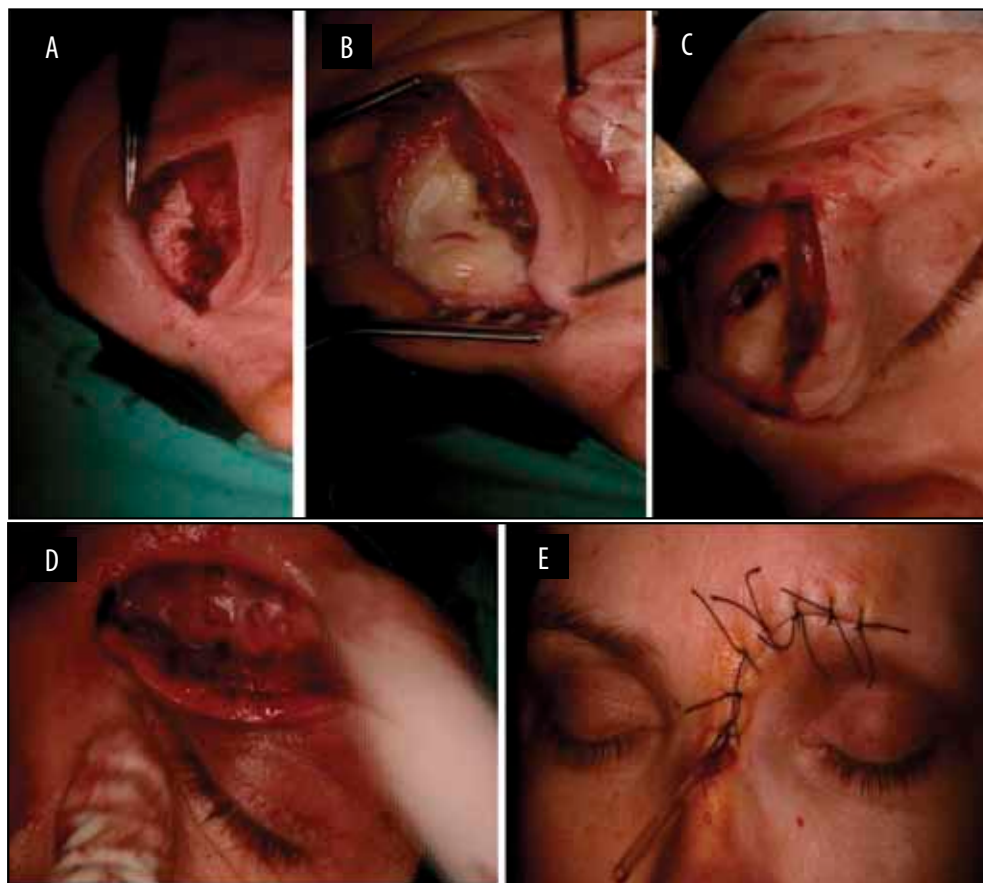


Figure 2 Intraoperative view – Ogston-Luc technique for excision of the left frontal sinus osteoma, by drilling (A,B,C); reconstruction of the anterior bony wall of the frontal sinus with silicon prosthesis (D,E)