

## ORIGINAL STUDY

# The role of continuous intraoperative neuromonitoring followed by facial nerve stimulation during parotidectomy

Georgiana Pasu<sup>1,2,3</sup>

<sup>1</sup>ENT&HNS Department, "Sfanta Maria" Hospital, Bucharest, Romania

<sup>2</sup>"Carol Davila" University of Medicine and Pharmacy, Bucharest, Romania

<sup>3</sup>CESITO Centre, "Sfanta Maria" Hospital, Bucharest, Romania

## ABSTRACT

**BACKGROUND.** Intraoperative neural monitoring (IONM) has begun to be studied in detail by surgeons around the world since several decades ago from the need to verify functional integrity of the neural elements. Parotid gland surgery requires a thorough knowledge of the anatomy of this region by ENT surgeons. Also, the surgeons performing parotid surgery need to have important strategies of management which include: handiness to identify facial nerve, dissection nerve branches and application of neuromonitoring in order to preserve nerve functions.

**OBJECTIVE.** This study has analysed the usefulness of intraoperative continuous monitoring in superficial or in total parotidectomy. It identifies the facial nerve and reduces the risk of postoperative facial palsy. We have been using intraoperative continuous monitoring - evoked facial nerve electromyograms (EMG).

**MATERIAL AND METHODS.** Continuous intraoperative facial nerve monitoring was prospectively achieved in the case of three patients diagnosed with benign tumors, on which parotidectomy with the preservation of the nerve was carried out in order to highlight the value and efficacy of this method.

**RESULTS.** In our country, continuous intraoperative facial nerve monitoring performance is still not a common practice in ENT Departments. It revealed postoperatively that the incidence of temporary or permanent facial palsy was 0% and the minimal stimulation was obtained at levels equal to 0,5 mA, which implies integral functioning of the facial nerve.

**CONCLUSION.** In parotid surgery, facial nerve IONM represents the gold standard in recognition of real-time electrophysiological signals, electromyography waves and auditory signals to enable the correct approach wherever possible, avoiding extensive nerve damage. It is known the importance of continuous IONM in postoperative prognosis of the neural function and intraoperative decision making regarding the technical surgery.

**KEYWORDS:** electrophysiologic intraoperative neural monitoring, facial nerve stimulation, continuous intraoperative monitoring, parotidectomy

## INTRODUCTION

The capacity of intraoperative neural monitoring (IONM) devices is to transform muscle activity into acoustic and electromyographic signals recorded and displayed in detail on the monitor. For the practical use of continuous IONM, we have elaborated standard protocols. Also, precise algorithms have been analysed - EMG spike waves, confirming the presence of spontaneous intraoperative electrical responses and the responses after direct stimulation to check the integrity of the nerve at the end of the surgery. Intraopera-

tive strategies of management involving facial nerve identification and neuromonitoring perioperative results are very important objectives that take account of the specialists in medico-legal litigation on the parotid gland tumoral pathology. Facial nerve dysfunction can cause medium to long-term psychological impact, significant cosmetic defects and functional morbidity: facial asymmetry, facial spasms, ocular complications - lagophthalmos and affected taste<sup>1</sup>. At the present moment, intraoperative electrophysiologic facial nerve monitoring is used by the surgeons performing parotid gland surgery around the world. Continuous in-

traoperative neuromonitoring has an important value during parotidectomy, especially regarding preservation of the anatomy and function of the facial nerve, which is one of the principal goals<sup>2</sup>.

Electrophysiological parameters of intraoperative facial nerve stimulation and monitoring are: stimulus amplitude, nerve stimulation threshold and latency. We will assess the effect of these electrophysiological parameters during facial dissection and superficial or total parotidectomy.

We are able to record changes in the amplitude of the compound muscle action (CMAP) continuously throughout the surgery by stimulating the facial nerve, exactly where the trunk of the facial nerve exits the skull at the stylomastoid foramen. These records can be achieved if the CMAP amplitude is preserved more than 50% at the end of the surgery; then, the probability of severe facial nerve palsy is very low<sup>3</sup>.

Our approach regarding FNM (facial nerve monitoring) in extracranial surgeries of the parotid gland integrates: percutaneous preoperative mapping, intra-field intraoperative mapping and a continuous CMAP monitoring throughout the surgery. The advantage of this modern technique is the ability to detect early signs of nerve stress in response to surgical manipulations by recording decrements in CMAP amplitude and using those values as neurophysiologic warnings to alert the surgeon before the FN is severely injured.

## MATERIAL AND METHODS

Our prospective study was carried out at "Sfanta Maria" Hospital – Otolaryngology Department on a group of three patients diagnosed with benign parotid tumors. Intraoperative continuous electromyographic monitoring in superficial or total parotidectomy with intraoperative/postoperative facial nerve evaluation was performed in order to highlight the efficacy of this electrophysiological technique in decreasing the incidence of permanent lesions in the extracranial portion of the facial nerve.

### *Instrumentation*

For performing monitoring of the facial nerve during the research project, our clinic has acquired the NATUS VIKING SYSTEM: EMG/EP 8 channels Software Viking EDX ver.20.1. IOM+PEEG.

### *Operative policy and surgical result*

All patients with tumoral pathology also underwent a magnetic resonance imaging (MRI) study prior to the surgery, which was interpreted by the same radiologist. In all three interventions, given the benign character of the tumor, we assessed the complete removal followed by the excision of the involved parotid

lobe. The purpose is to remove as much of the parotid tumoral mass as possible, along with the lobe, without damaging the nerve and therefore the facial muscles: frontalis, orbicularis oculi, nasalis, orbicularis oris, mentalis. The complete resection of the tumor is important because of the recurrence risk that subtotal resection might hold and also because of the pressure effect on the neighbouring structures<sup>4</sup>.

All three cases were attended by the same surgeon in the classical Redon approach. The facial nerve was discovered near the stylomastoid foramen and dissection was performed following every branch of the nerve until the complete removal of the tumor and the lobe<sup>4</sup>.

There were no intraoperative injuries of the nerve and no facial palsy after the intervention for any of the three cases.

### *Anaesthesia*

Anaesthesia was maintained by inhalational anaesthetics without a muscle relaxant unless intubation was difficult. In general, local administration of lidocaine was avoided. To obtain electrical responses – EMG potentials (CMAP) with appropriate amplitude, a particular type of anaesthesia has been induced to avoid muscle relaxation, specifically: sevoflurane inhalation with oxygen and a significant percentage (70%) of nitrous oxide<sup>5</sup>. In this type of anaesthesia, opioids are frequently used but they cause a low potential evoked motor response. In patients, during parotidectomy, propofol – an aesthetic from the opioid category – was administered. However, propofol has a depressive effect in high doses on muscles causing loss CMAP amplitude<sup>6-8</sup>. To avoid the dose-dependent effect, minimum doses of propofol (100-200µg/kg/min) have been used<sup>9</sup>.

### *Procedure*

Three cases were studied: a 57-year-old female diagnosed with pleomorphic adenoma of the deep parotid lobe, a 53-year-old male with pleomorphic adenoma of the superficial parotid lobe and a 61-year-old male with Warthin's tumor situated also in the superficial lobe of the parotid. In the first two cases, we have performed a total parotidectomy with thorough dissection of all branches and preservation of the facial nerve that was adjacent to the tumor (Figure 1). The third case underwent partial parotidectomy with identification and preservation of the facial nerve.

For recording CMAP responses, disposable twisted pair subdermal needle electrodes (Disposable Subdermal Needle or Disposable Corkscrew Electrode) were inserted into the monitored muscles: orbicularis oculi, orbicularis oris in order to perform electrical stimulation. Recording muscle electrodes were placed: 0.5 cm lateral to the outer wall of the bony orbit for the orbicularis oculi; 0.5 cm on both sides of the upper and lower

lip, close to the angle of the mouth for the orbicularis oris. The correct intramuscular placement of the electrodes is always checked with the impedance meter, so that the anode and cathode impedance is minimal and the difference between them is null (Figure 2).

Electrophysiological parameters were analysed: waveform amplitude, latencies, duration of spicks waves of the facial muscle after identification of the facial nerve trunk and dissection branches. CMAP amplitudes of approximately 2.4 mA were recorded in the orbicularis oculi and orbicularis oris muscles. At the end of the parotidectomy, the records were repeated and EMG parameters were analysed in detail.

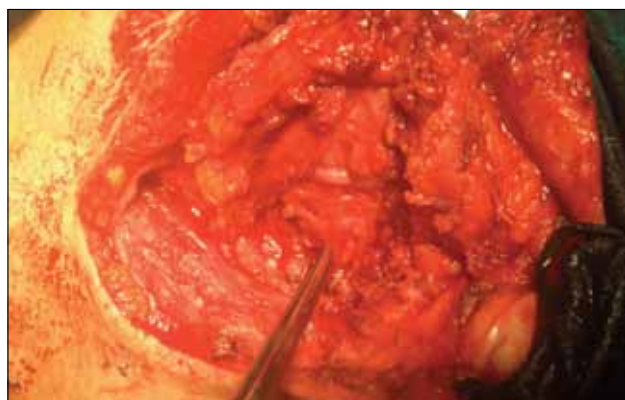
We stimulated the facial nerve with a bipolar portable stimulator (Neurosign; Natus-Disposable bipolar probe). Typical intraoperative stimulation intensity was set at 1-2mA with a duration of 50-100 ms, but the intensity has been shorter during parotid stimulation<sup>2</sup>. The next step

was to record the intraoperative threshold stimulation and subsequently to compare it with the threshold stimulus of the facial nerve post-parotidectomy<sup>10</sup>.

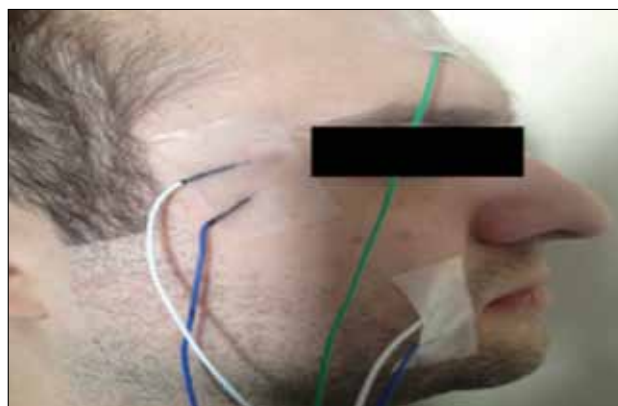### RESULTS

Identification of the facial nerve is accomplished by using two distinct types of intraoperative monitoring: free spontaneous EMG and continuous EMG. During parotidectomy, we used monitoring continuously; subsequently, the facial nerve was electrically stimulated at a frequency of 2.1 Hz and, finally, we studied spontaneous evoked potentials.

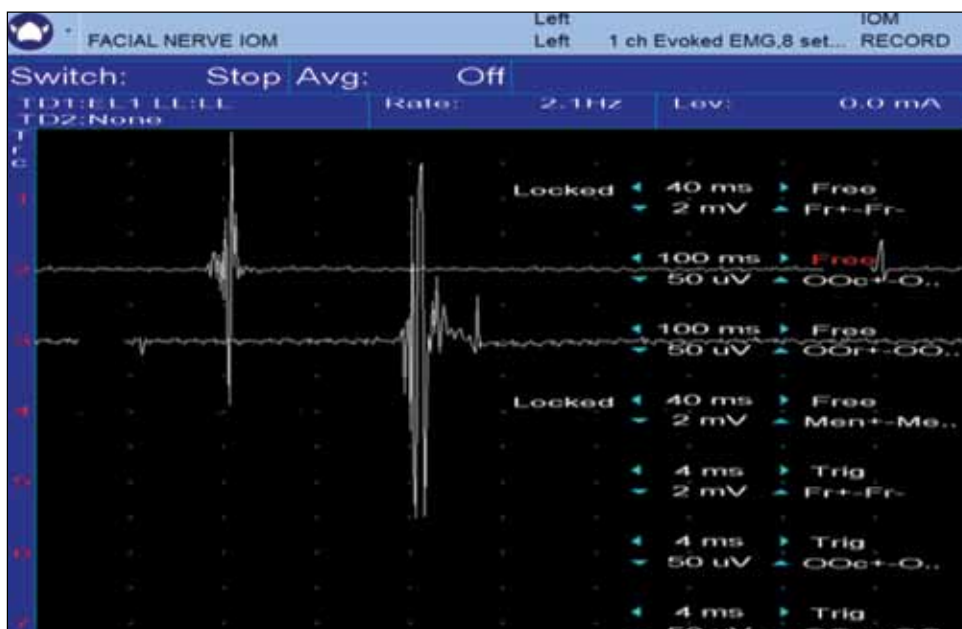
During parotidectomy, spontaneous activation was remarked to few motor potentials having intimate contact with the facial nerve, but they are electrophysiologically and clinically worthless (Figure 3). Waves



**Figure 1** The dissection of the facial nerve – showing: zygomatico-temporal and cervico-facial branches



**Figure 2** Electrode placement: orbicularis oculi muscle and orbicularis oris muscle



**Figure 3** Spontaneous EMG monitoring - EMG spikes (upper panels). A wave with spiking in the EMG signifies proximity to the neural elements of the facial nerve

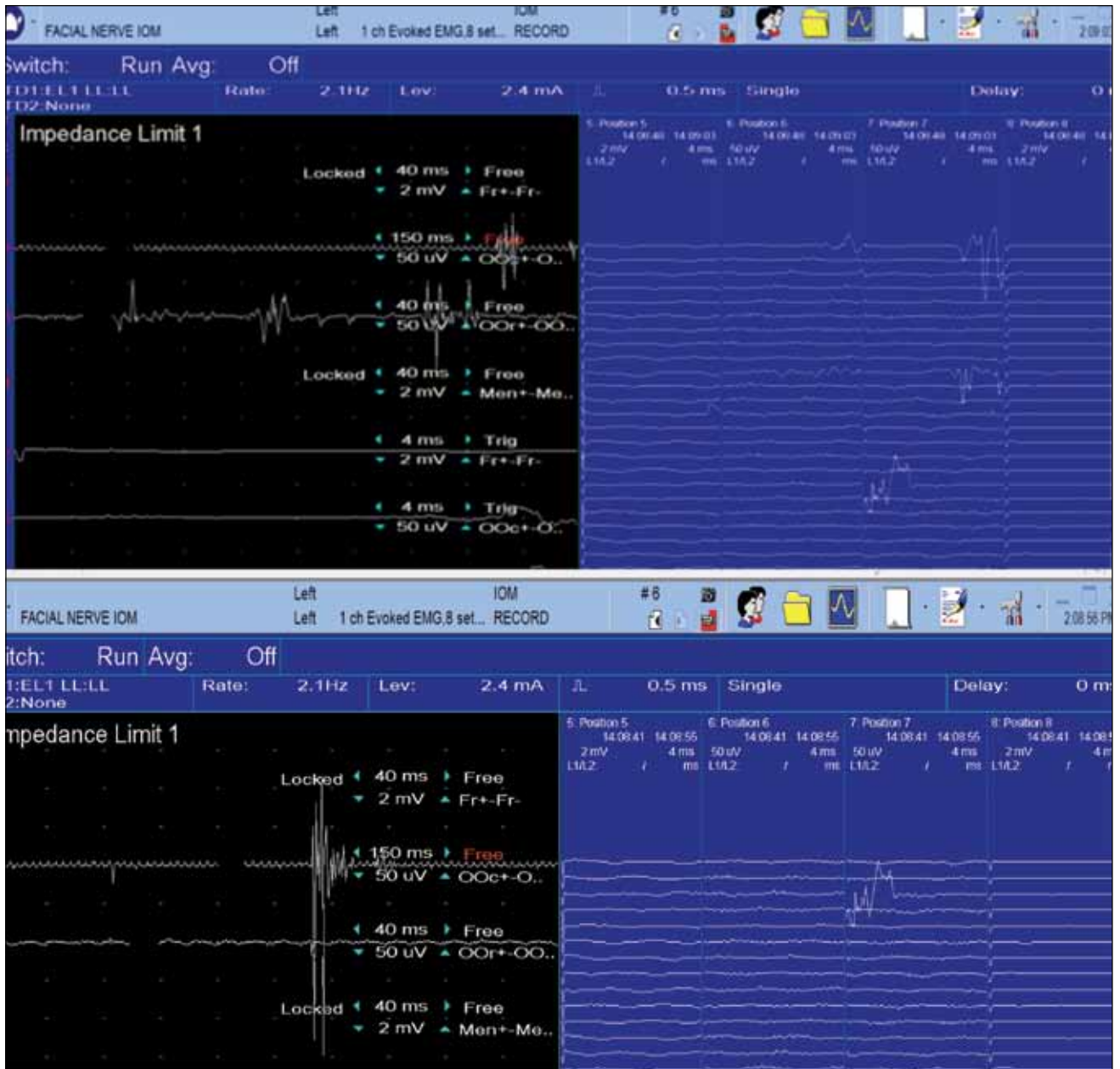
with spikes in the EMG were recorded when they were generated by the stimulation of several motor units, signifying proximity to the neural elements of the facial nerve<sup>11,12</sup>.

Facial nerve IONM is achieved by using real-time electrophysiological signals, electromyography waves and auditory signals to enable the correct approach wherever possible, avoiding extensive nerve damage; thus, the surgeon will change the aggressive dissection technique.

The insertion depth of the stimulating electrode needle and the threshold of stimulation were established when the stimulating current elicited CMAP in muscles innervated by all four branches of the facial

nerve. Single stimuli of 4 ms duration with a maximum intensity of 50  $\mu$ V were applied if necessary, and the repetition rate was 1 Hz. Postoperatively, we stimulated both the nerve trunk and each branch of the facial nerve and we analysed whether an electrical response appeared on the display (amplitude, frequency, EMG waves). The clinical significance of potential motor-CMAP is correlated with the anatomical and functional integrity of the facial nerve (Figure 4).

It was revealed postoperatively that the incidence of temporary or permanent facial palsy was 0% and the minimal stimulation was obtained at levels equal to 0,5 mA, which implies integral functioning of the facial nerve.



**Figure 4** CMAP in the orbicularis oris muscle evoked at a sub- or near-threshold intensity (2,4 mA) by electrical stimulation applied to the parotid region of the facial nerve

## CONCLUSIONS

Continuous intraoperative monitoring of the facial nerve is considered cutting-edge technology in parotid surgery, although it is seldom used in ENT departments. It has been done successfully for the first time in Romania at “Sfanta Maria” Hospital, which is “Center of excellence for research of sensitive and sensorial disorder mechanism and inflammatory pathology, tumoral and obstructive upper aero-digestive paths diseases”.

The evolution after the first utilization of the presented patients was favourable both in immediate and “follow-up” evaluation.

The benefit of this technique is the capacity to exactly identify the facial nerve trunk and branches and also to make intraoperative changes of the electrical signals in the muscle and the motor neurons using evoked facial EMGs.

The important issue is to maintain constant amplitude of the potentials while stimulating the nerve and to adapt the intensity according to the lowering of the depolarization threshold. Therefore, a medical technologist must be in charge of the permanent surveillance and adjustment of the potentials.

In this way, the evoked potentials will generate proper information regarding the nerve status; thus, immediate postoperative and follow-up facial palsy will be avoided, also assuring satisfactory tumoral resection.

**Acknowledgment:** This research has been conducted successfully and realized in the hospital thanks to the acquisition of modern state-of-the-art medical equipment, especially for this project co-financed through the European Fund for Regional Development.

**Conflicts of interests:** None

## REFERENCES

1. Ryzenman J.M., Pensak M.L., Tew J.M. Jr - Facial paralysis and surgical rehabilitation: a quality of life analysis in a cohort of 1,595 patients after acoustic neuroma surgery. *Otol Neurotol.*, 2005;26(3):516–521.
2. Brennan J., Moore E.J., Shuler K.J. - Prospective analysis of the efficacy of continuous intraoperative nerve monitoring during thyroidectomy, parathyroidectomy, and parotidectomy. *Otolaryngol Head Neck Surg.*, 2001;124(5):537–543.
3. Amano M., Kohno M., Nagata O., Taniguchi M., Sora S., Sato H. - Intraoperative continuous monitoring of evoked facial nerve electromyograms in acoustic neuroma surgery. *Acta Neurochir (Wien)*, 2011;153(5):1059–1067 [discussion 1067].
4. Ozturk K., Akylidiz S., Gode S., Turhal G., Gursan G., Kirazli T. - The effect of partial superficial parotidectomy on amplitude, latency and threshold of facial nerve stimulation. *Eur Arch Otorhinolaryngol.*, 2016;273(6):1527-1531. doi: 10.1007/s00405-015-3622-9. Epub 2015 Apr 11.
5. Kaye A.D., Davis S.F. - Principles of Neurophysiological Assessment, Mapping, and Monitoring. Springer-Verlag New York, 2014.
6. Kawaguchi M., Sakamoto T., Inoue S., Kakimoto M., Furuya H., Morimoto T., Sakaki T. - Low dose propofol as a supplement to ketamine-based anesthesia during intraoperative monitoring of motor-evoked potentials. *Spine (Phila Pa 1976)*, 2000;25(8):974–979.
7. Nathan N., Tabaraud F., Lacroix F., Moulies D., Viviand X., Lansade A., Terrier G., Feiss P. - Influence of propofol concentrations on multipulse transcranial motor evoked potentials. *Br J Anaesth.*, 2003;91(4):493–497.
8. van Dongen E.P., ter Beek H.T., Aarts L.P., Schepens M.A., Morshuis W.J., Benning F.J., de Boer A., Boezeman E.H. - The effect of two low-dose propofol infusions on the relationship between six-pulse transcranial electrical stimulation and the evoked lower extremity muscle response. *Acta Anaesthesiol Scand.*, 2000;44(7):799–803.
9. Inoue S., Kawaguchi M., Kakimoto M., Sakamoto T., Kitaguchi K., Furuya H., Morimoto T., Sakaki T. - Amplitudes and intrapatient variability of myogenic motor evoked potentials to transcranial electrical stimulation during ketamine/N<sub>2</sub>O- and propofol/N<sub>2</sub>O-based anesthesia. *J Neurosurg Anesthesiol.*, 2002;14(3):213–217.
10. Doikov I.Y., Konsulov S.S., Dimov R.S., Deenitchin G.P., Yovchev I.P. - Stimulation electromyography as a method of intraoperative localization and identification of the facial nerve during parotidectomy: review of 15 consecutive parotid surgeries. *Folia Med (Plovdiv)*, 2001;43(4):23–6.
11. Husain A.M. - A practical approach to neurophysiologic intraoperative monitoring [electronic resource]. Demos Medical Publishing, New York, 2008.
12. Holland N.R., Lukaczyk T.A., Riley L.H. 3rd, Kostuik J.P. - Higher electrical stimulus intensities are required to activate chronically compressed nerve roots. Implications for intraoperative electromyographic pedicle screw testing. *Spine (Phila Pa 1976)*, 1998;23(2):224–227.

