

**CASE REPORT****“Visual Hook” for the removal of nasal foreign body – Case report****Sabari Nath H.S.**

Department of ENT, Azeezia Institute of Medical Science, Kollam, Kerala, India

**ABSTRACT**

We present a case of paediatric nasal foreign body removal using a flexible nasopharyngolaryngoscope, which is used both as an endoscope for visualization and as a hook for the rapid and complete removal of the nasal foreign body (“Visual Hook”).

**KEYWORDS:** “Visual Hook”, nasal foreign body, flexible nasopharyngolaryngoscopy, video-assisted foreign body removal

**INTRODUCTION**

Otorhinolaryngeal foreign bodies are more commonly seen in children. Foreign bodies have been estimated to account for approximately 11% of the cases seen in ENT services<sup>1-3</sup>. The type of foreign body varies with age and site of lodgement. The local food constitutes the highest incidence of otorhinolaryngeal foreign bodies<sup>4</sup>.

Nasal foreign bodies constitute the second place in ENT foreign bodies<sup>4</sup>. Foreign body removal in an awoken child is embarrassing for both bystanders and the surgeon, moreover it is traumatic also.

**CASE REPORT**

A 5-year-old girl was brought to the emergency department of a tertiary care teaching hospital with alleged history of insertion of an orange peel in the right nasal cavity one hour back. Otorhinolaryngology consultation was sought for the child. The child was shifted to the Department of Otorhinolaryngology.

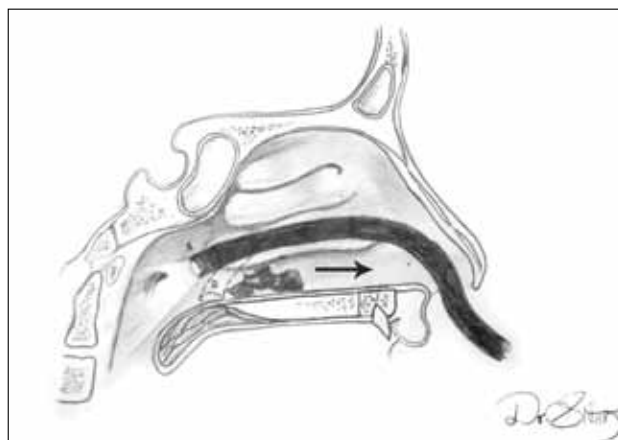
On examination, a whitish and orange coloured foreign body was visualized in the area of the right inferior meatus surrounded by mucous secretions. Parents were explained about the procedure for the removal of the foreign body; then the child was mummified and two small pieces of orange peel around 3x4 mm were removed from the nasal cavity using the conventional probe. Multiple small bits of orange peel were noted in the right nasal cavity.

As the child was not co-operative, there was need for sedating and intubating the child for the removal of the foreign body. This aspect was explained to the parents and, after getting their consent, the child was

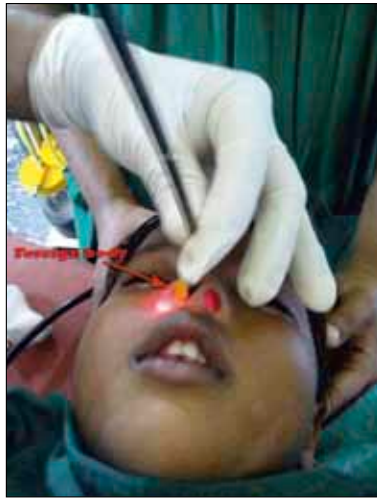shifted to the operation theatre. She was given 5 ml of Pedicloryl syrup (100mg/5ml) and Ketamine 50mg with Atropine 0.3 mg intramuscular injection.

Once the child was asleep, she was kept in head low position and a flexible nasopharyngolaryngoscope was introduced into the nasal cavity. Multiple small bits of orange peels were visualized on the floor of the right nasal cavity and one small piece above the middle turbinate. The piece above the middle turbinate was pushed down with the help of the scope under visualization. The scope was passed above and behind the foreign body and it was flexed down, and slowly pulled it back (Figure 1).

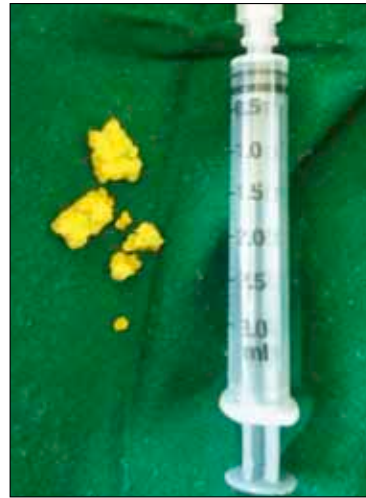The foreign body was extracted using the hook made by the endoscope under visualization (Figure 2, Figure 3). There was no trauma or complications. The nasal cavity was examined again and there was no residual foreign body. The child was discharged after 2 hours of observation.



**Figure 1** Diagrammatic representation of removal of the foreign body using the visual hook 1) introducing the scope above the foreign body 2) Flexing the scope to form a hook and it is removed by pulling out



**Figure 2** Removal of the foreign body using the "Visual Hook"



**Figure 3** Foreign body removed with the "Visual hook"

## DISCUSSIONS

Foreign body removal in an awoken child is embarrassing for both bystanders and the surgeon, moreover it is traumatic also. Nasal fossa represents the second site in ENT foreign bodies' location<sup>4</sup>. This pathology is seen more in the age group of 4-8yrs<sup>5</sup>. The most common foreign bodies include beans, safety pins, nuts, coins, rubber erasers, paper or beads<sup>6,7</sup>. They may lead to congestion, swelling or ulceration of the nasal mucosa, bony destruction and epistaxis, breathlessness, pain. Alteration in the resonance of speech, hyponasality, headaches, sneezing, nasal discharge and halitosis has also been reported<sup>7</sup>. Also, the close contact between the foreign bodies and the mucosal surface can result in tissue destruction and septal perforation<sup>8</sup>.

The most common locations of the nasal foreign bodies are represented by the floor of the nasal passage, just below the inferior turbinate, or the upper nasal fossa anterior to the middle turbinate<sup>9</sup>.

Various techniques for the removal of the nasal foreign body include the removal with direct visualization using forceps, curved hooks, cerumen loops or suction catheters. Additionally, successful removal has been achieved by passing a thin, lubricated balloon-tip catheter (5 or 6 French Foley) past the foreign body; after inflating the balloon, the inflated catheter balloon is pulled forward, thus moving the foreign body into the anterior nares and then removed<sup>10</sup>.

The most commonly used method for the removal of a foreign body is the rigid nasal endoscope, but the chances of iatrogenic trauma are bigger. Flexible nasopharyngoscopes use was limited to passive guidance of the surgical instrument<sup>11</sup>. Till date, there are no reported cases with photographic documentation from India using the flexible scope as an extractor.

## CONCLUSIONS

We presented a case of paediatric nasal foreign body removal by using a flexible nasopharyngolaryngoscope for both visualization and extraction of the foreign body. With this method we can visualize and remove the foreign body without manipulation of an instrument in selected cases. As this method is not that commonly used, long case series need to be done to testify the validity of this method. We believe that this method can be used for removal of selected foreign bodies in the nose.

**Conflicts of interests:** None

## REFERENCES

1. Figueiredo R.R., Azevedo A.A., Kós A.O., Tomita S. - Complications of ENT foreign bodies: a retrospective study. *Braz J Otorhinolaryngol.*, 2008;74(1):7-15.
2. Silva B.S.R., Souza L.O., Camera M.G., Tamiso G.B., Castanheira L.V.R. - Foreign bodies in otorhinolaryngology: a study of 128 cases. *Int Arch Otorhinolaryngol.*, 2009;13(4):394-399.
3. Bressler K., Shelton C. - Ear foreign-body removal: a review of 98 consecutive cases. *Laryngoscope.* 1993;103(4 Pt 1):367-370.
4. Chiun K.C., Tang I.P., Tan T.Y., Jong D.E. - Review of ear, nose and throat foreign bodies in Sarawak General Hospital. A five year experience. *Med J Malaysia.*, 2012;67(1):17-20.
5. Ngo A., Ng K.C., Sim T.P. - Otorhinolaryngeal foreign bodies in children presenting to the emergency department. *Singapore Med J.*, 2005;46(4):172-178.
6. Dudvarski Z., Pendjer I., Janosevic L.J., Djukic V., Dimitrijevic M., Arsovic N., Basaric D. - Overlooked nasal foreign body with a 48-year latent period. *Acta Chir Jugosl.*, 2008;55(4):113-116.
7. Pellacchia V., Moricca L.M., Buonaccorsi S., Indrizzi E., Fini G. - Unusual foreign body in the nasal cavity. *J Craniofac Surg.*, 2006;17(6):1176-1180.
8. Fox J.R. - Fogarty catheter removal of nasal foreign bodies. *Ann Emerg Med.*, 1980;9(1):37-38.
9. Bhatia R., Singhal S.K., Dass A. - Button Cell Causing Septal Perforation in a Child. *Clin Rhinol A Int J.*, 2010;3(3):161-163.
10. Chan T.C., Ufberg J., Harrigan R.A., Vilke G.M. - Nasal foreign body removal. *J Emerg Med.*, 2004;26(4):441-445.
11. Giourgos G., Matti E., Pagella F. - Endoscopic removal of a nasal foreign body with the "hook-scope" technique. *Eur Arch Otorhinolaryngol.*, 2009;266(10):1663-1665. doi: 10.1007/s00405-009-1056-y. Epub 2009 Jul 28.