

CASE REPORT

Bilateral sinoliths in the ethmoid sinus – a rare Cone Beam CT finding

Cristina Julieta Sava¹, Mugurel Constantin Rusu²

¹Division of Anatomy, Faculty of Medicine, “Victor Babes” University of Medicine and Pharmacy, Timisoara, Romania

²Division of Anatomy, Faculty of Dental Medicine, “Carol Davila” University of Medicine and Pharmacy, Bucharest, Romania

ABSTRACT

Sinoliths are calculi found particularly in paranasal sinuses, the rarest location being the ethmoid air cells. There were previously reported only 4 cases of unilateral large ethmoidal sinoliths (ES), this one being the fifth report. We report here the incidental bilateral evidence in a 34-year-old female patient evaluated in Cone Beam Computed Tomography (CBCT) of minor ES. The left ES, of 1.6 mm² sagittal size, occupied the suprabullar cell, in front of the ground lamella and behind the anterior ethmoidal canal. The right ES, of 7.6 mm², was located behind the ground lamella. The radiodensity of each ES was about 1000 HU, their bone quality being thus assessed. This is the first evidence of bilateral and clinically silent ethmoidal sinoliths. Being small-sized and incidentally found, it seems reasonable to consider that ethmoidal sinoliths could have a higher incidence but they are overlooked due to the lack of clinical manifestations.

KEYWORDS: sinolith, ethmoid air cells, paranasal sinus, basal ethmoidal lamella, anterior ethmoidal canal

INTRODUCTION

Sinoliths are calculi found particularly in frontal, maxillary, sphenoid and ethmoid sinuses^{1,2}. Sinoliths of the paranasal sinuses are still rare entities². The highest incidence of stone formation is in the maxillary sinus, following the frontal sinus and the ethmoidal sinus³.

The term “sinolith” usually indicates calculi in the sphenoid, ethmoid or frontal sinuses, whereas calculi in the maxillary sinus are also termed antroliths or antrolithiasis and calculi in the nasal fossae are known as rhinoliths or rhinolithiasis². Although antroliths and sinoliths are extremely common in world literature, the presence of a sinolith, especially in the ethmoid sinus, is exceedingly uncommon³.

We report here bilateral minor sinoliths in the ethmoid sinuses. These were found incidentally at a Cone Beam Computed Tomography (CBCT) exploration of a patient prior to the dental treatment.

CASE REPORT

In a 34-year-old female patient who was evaluated in Cone Beam Computed Tomography (CBCT) for es-

tablishing an adequate dental treatment, minor dense bodies in the ethmoid sinuses were bilaterally found.

The subject was explored using a Cone Beam Computer Tomography (CBCT) machine – iCat (Imaging Sciences International), and CT data was analysed using the iCatVision software and the application 3DVR v5.0.0.3, for the 3D reconstructions, the specific protocol being previously described⁴. We used bidimensional multiplanar reconstructions (MPRs) in the axial, coronal, sagittal and oblique planes.

On each side, small opaque masses were identified within the respective ethmoid sinuses, the radiodensity of each one being of 1000 HU average, thus corresponding to calcified or bony structures. These were thus objectivated so as ethmoidal sinoliths (ES).

The left ES was located (Figure 1) 1 mm inferior to the ethmoid roof, within a suprabullar ethmoid air cell which was draining in the suprabullar recess. It was posterior to the 2nd ethmoidal lamella (the basal lamella of the ethmoidal bulla), applied on the outer side of the inferior end of the lateral lamella, thus in the infero-lateral angle of the olfactory fossa. On oblique/coronal multiplanar reconstructions (MPRs) it was located inferior to the anterior ethmoidal canal, coursing to its opening into the lateral lamella (Figure 2). The sagittal area of the left ES was of 1.6 mm².

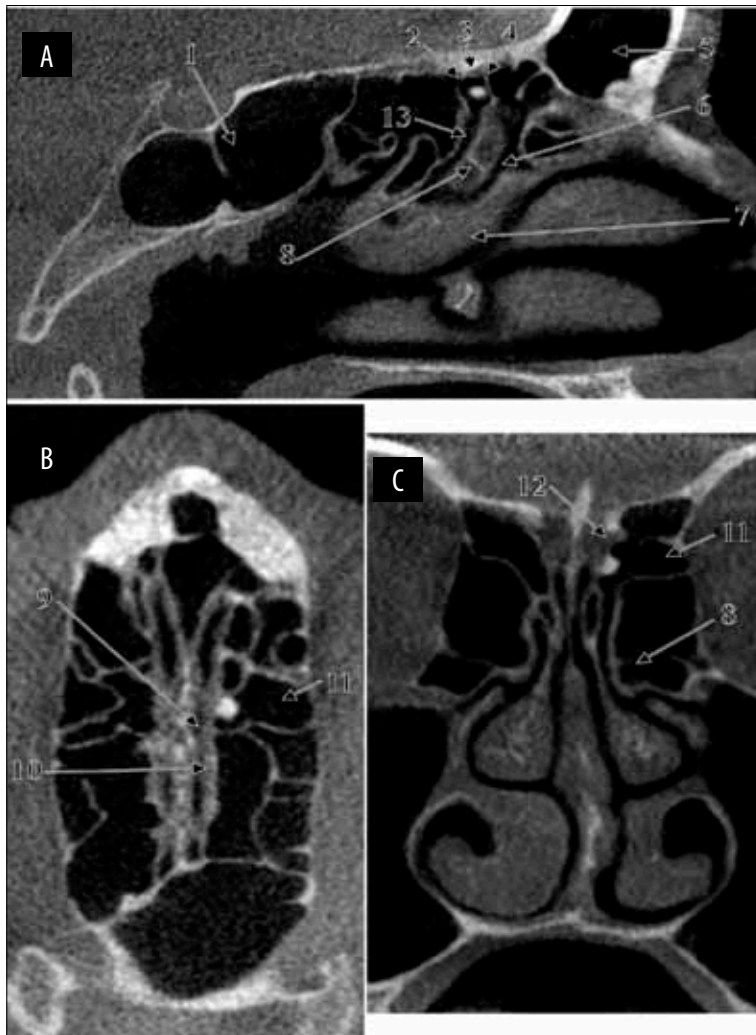


Figure 1 Multiplanar reconstructions (MPRs) depicting the location of the left ethmoidal sinolith: (A) sagittal MPR; (B) axial MPR; (C) coronal MPR. 1. sphenoid sinus; 2. basal lamella of the middle turbinate; 3. anterior ethmoidal artery, coursing above the left ethmoidal sinolith and beneath the roof of the suprabullar air cell; 4. basal lamella of the ethmoidal bulla; 5. frontal sinus; 6. ethmoidal infundibulum; 7. middle turbinate; 8. ethmoidal bulla; 9. olfactory fossa; 10. lateral lamella; 11. suprabullar cell; 12. medial opening of the anterior ethmoidal canal; 13. suprabullar recess.

The right ES was at 1.50 mm beneath the ethmoid roof, within the central posterior ethmoid air cell, which was draining in the upper nasal meatus (Figure 3). It was placed immediately posterior to the 3rd ethmoidal lamella (the basal lamella of the middle turbinate, ground lamella); the anterior ethmoidal canal was identified applied on the posterior side of the 3rd ethmoidal lamella on that side, at 3.20 mm antero-superior to the ES and separated from it by the ground lamella. The sagittal area of the right ES was of 7.6 mm².

DISCUSSIONS

An ES was firstly reported by Kanzaki and Sakamoto in 2005⁵. It was found in the left ethmoid sinus of a

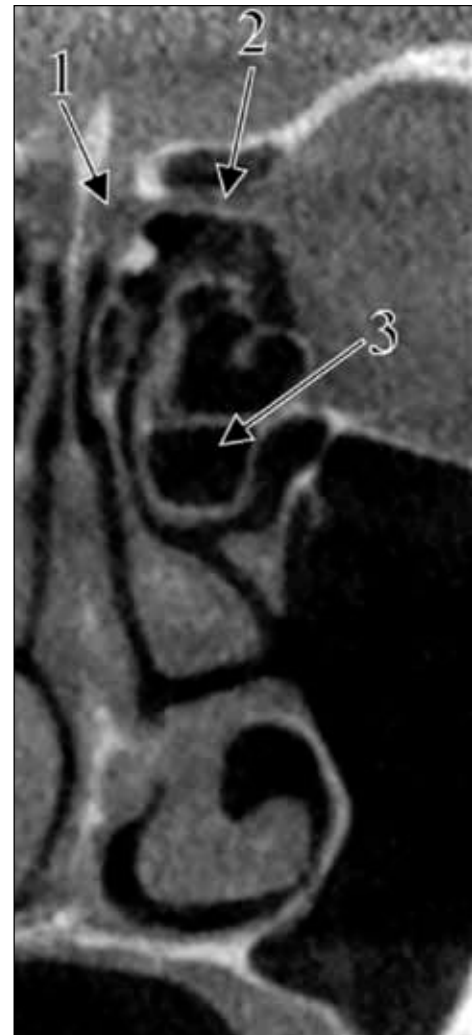


Figure 2 Left oblique-coronal MPR illustrating the relation of the left ethmoidal sinolith with the anterior ethmoidal canal:

1. olfactory fossa;
2. anterior ethmoidal canal; 3. ethmoidal bulla.

61-year-old patient who complained of nasal obstruction; the ES was about 1 cm in diameter and its structure was confirmed histopathologically as being bone-like⁵. The authors discussed that the pathogenesis of such sinoliths is not fully understood, sinoliths or antroliths being either of exogenous or of endogenous (sinus infections) origin⁵. In the case reported here, neither the clinical history, nor CBCT signs of ethmoid infections were documented.

Two more cases of large unilateral ES were further reported by Almasi et al. (2010)⁶. One was a 52-year-old female patient with a clinical picture of nasal dyspnea, postnasal drip and dry cough; the second case was of a 71-year-old male patient who had had repeated polypectomies⁶. In the first case the stone was located in the middle meatus and occupied the ethmoidal

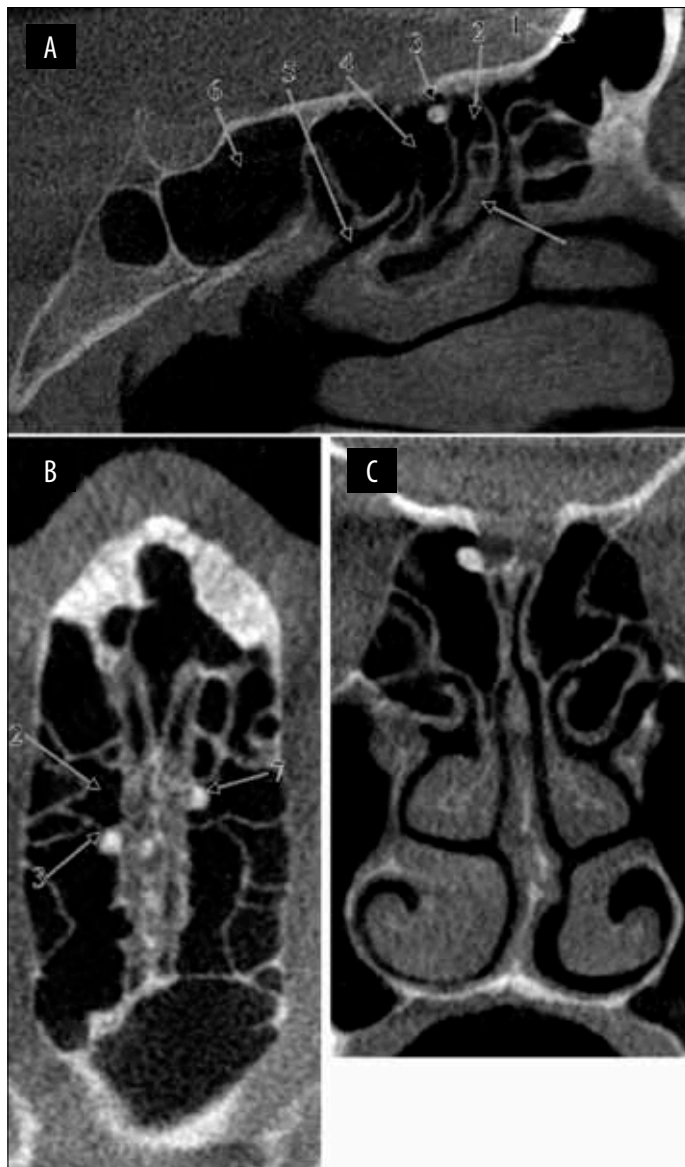


Figure 3 Multiplanar reconstructions (MPRs) depicting the location of the right ethmoidal sinolith: (A) sagittal MPR; (B) axial MPR; (C) coronal MPR. 1. frontal sinus; 2. suprabullar cell; 3. right ethmoidal sinolith, applied on the posterior side of the ground lamella; 4. central posterior ethmoid air cell; 5. upper nasal meatus; 6. sphenoid sinus; 7. left ethmoidal sinolith, within the left suprabullar cell.

bulla, while in the second case the ES was placed in the anterior ethmoid adjacent to the lamina papyracea⁶. The authors discussed then the vague pathogenesis of sinoliths and included as endogenous factors anatomical ones, such as poor sinus aeration and drainage⁶. Neither of these could be considered in the case reported here, as no anatomical modifications were found impeding the drainage of the sinuses.

The fourth case of ES was reported by Nayak et al. (2014) in a 45-year-old male patient with recurrent

nasal obstruction, episodic sneezing spells, headache and nasal discharge of 20-year duration³. The CT exam revealed a 21.75 cm³ hyperdense irregular mass in the right anterior ethmoidal cell which was blocking the frontal recess and the hiatus semilunaris; mucosal thickenings were present in all paranasal sinuses⁵. We fully agree with those authors who discuss that „*CT of the paranasal sinuses clinches the diagnosis where a bony density is visualised*”⁵. Exploration in CBCT could benefit of the software possibility of determining the radiodensity of the solid masses, to assess the stone quality, as we did here. Nevertheless, rhinoscopy stands as a useful tool to support the CT diagnosis⁶.

CONCLUSIONS

The sinoliths of the ethmoidal sinus are rare findings, this case being, in our knowledge, the fifth one reported. This is also the first evidence of bilateral occurrence of ethmoidal sinoliths. Being small-sized and incidentally found, it seems reasonable to consider that ethmoidal sinoliths could have a higher incidence, but they are overlooked due to the lack of clinical manifestations.

Conflict of interest: The authors have no conflict of interest.

Contribution of authors: All authors have equally contributed to this work.

REFERENCES

1. Elangovan S., Srinivasa V. - Maxillary Antrolith - A Rare Cause of Epistaxis. *Journal of Evolution of Medical and Dental Sciences*, 2014;3(01):100-102. doi: 10.14260/jemds/1796.
2. Lee D.H., Yoon T.M., Lee J.K., Lim S.C. - Frontal Sinolith. *J Craniofac Surg.*, 2015;26(5):e385-e386. doi: 10.1097/SCS.0000000000001858.
3. Nayak D.R., Bhandarkar A.M., Valiathan M., K S.V. - Incidental 'ethmoid sinolith'-an unusual cause of frontal recess obstruction. *BMJ Case Rep.*, 2014;2014. pii:bcr2014204157. doi: 10.1136/bcr-2014-204157.
4. Rusu M.C., Didilescu A.C., Jianu A.M., Padurarur D. - 3D CBCT anatomy of the pterygopalatine fossa. *Surg Radiol Anat.*, 2013;35(2):143-159. doi: 10.1007/s00276-012-1009-9.
5. Kanzaki S., Sakamoto M. - Sinolith in the ethmoid sinus. *J Laryngol Otol.*, 2006;120(2):e11.
6. Almasi M., Andrasovska M., Koval J. - Sinolith in the ethmoid sinus: report of two cases and review of the literature. *Eur Arch Otorhinolaryngol.*, 2010;267(10):1649-1652. doi: 10.1007/s00405-010-1321-0. Epub 2010 Jul 2.

