

CASE REPORT

A rare case of triple-hit diffuse large B-cell lymphoma of the parotid gland in a patient with Sjogren's syndrome

Adelina Birceanu^{1,2}, Anca Evsei^{1,3}, Adrian Dumitru^{2,4}, Maria Sajin^{2,4}, Codrut Sarafoleanu^{3,5,6}

¹Department of Pathology, "Sfanta Maria" Hospital, Bucharest, Romania

²Pathology Department, Faculty of Medicine, "Carol Davila" University of Medicine and Pharmacy, Bucharest, Romania

³CESITO Center, "Sfanta Maria" Hospital, Bucharest, Romania

⁴Department of Pathology, Emergency University Hospital, Bucharest, Romania

⁵ENT&HNS Department, "Sfanta Maria" Hospital, Bucharest, Romania

⁶ENT&HNS Department, Faculty of Dental Medicine, "Carol Davila" University of Medicine and Pharmacy, Bucharest, Romania

ABSTRACT

BACKGROUND. Primary malignant lymphomas of the salivary gland are rare, accounting for 2% of salivary gland tumors and 5% of all extranodal lymphomas. The clinical presentation is not particularly characteristic, a feature that usually leads to diagnostic and treatment delays.

CASE REPORT. We report a case of a parotid gland triple-hit diffuse large B-cell (DLBCL) lymphoma associated with follicular lymphoma in a 76-year-old female patient with a unique personal history, which included a diagnosis of Sjogren Syndrome and exposure to a toxic working environment with pesticides. Diffuse large B-cell lymphomas are uncommon given the fact that most lymphoid malignancies are low-grade lymphomas, with MALT (mucosa associated lymphoid tissue) lymphomas being the most common. Triple-hit DLBCL are extremely rare and the diagnosis can be challenging. Parotidectomy, as the first step, must be followed by histopathology and immunohistochemistry for final diagnosis and treatment.

CONCLUSION. This case highlights the fact that B-cell lymphoma in the salivary gland can be unrecognized due to unspecific symptoms and requires immunohistochemistry studies for confirmation. It is important to recognize triple-hit lymphoma due to its worse prognosis and differentiated treatment. Patients with Sjogren syndrome have additional risk factors for progression to lymphoma.

KEYWORDS: primary parotid gland lymphoma, triple-hit, diffuse large B-cell lymphoma, Sjogren's syndrome.

INTRODUCTION

Primary lymphoma of the salivary gland is rare, accounting for 2-5% of all salivary neoplasms. Diffuse large B-cell lymphomas (DLBCL) are uncommon, most salivary gland lymphoid malignancies being low-grade lymphomas with MALT (mucosa associated lymphoid tissue) lymphomas being the most common. The majority of primary salivary gland DLBCLs appear to arise from MALT type lymphomas in a background of sialadenitis associated with autoimmune disorders, such as Sjogren syndrome^{1,4}.

The pathophysiology of Non-Hodgkin Lymphoma

(NHL) is unknown. However, some risk factors are related to NHL development, such as acquired or drug-induced immunodeficiency, some autoimmune diseases or Sjogren's syndrome⁵.

Double and triple-hit B-cell lymphoma (DHL, THL) are rare lymphoma subtypes usually associated with poor prognosis. These specific subtypes are defined by two or three recurrent chromosome translocations: MYC/8q24loci, usually in combination with the t(14;18)(q32; q21) bcl-2 gene and/or BCL6 3q27 chromosomal translocation. Here, we present one case with diffuse large B-cell lymphoma associated with follicular lymphoma transformed to THL⁶.

CASE REPORT

We herein report a case of a 76-year-old female patient who presented with a painless, gradually increasing mass in the region of the right parotid gland in the last two months.

Patient personal history revealed that the patient had worked in a toxic environment with constant exposure to pesticides. Arterial hypertension, pulmonary sclero-emphysema, post-tuberculosis sequelae in the superior half of the right hemithorax and atherosclerosis stage IV were secondary pathological conditions.

Imaging studies, including computer tomography (CT) and ultrasonography, were non-specific. Blood tests revealed positive Anti-nuclear antibody, anti-Ro (SS-A) antibody and a high rheumatoid factor, which, in association with a positive Schirmer test, confirmed the diagnosis of Sjogren's syndrome. She received a 16-day treatment with Medrol and the swelling was resolved; a week later the swelling reappeared.

The patient underwent a full ENT and systemic clinical workup. Cardio-respiratory and neurological examinations were normal. Routine haematological and biochemical parameters revealed a high serum lactate dehydrogenase (LDH) which showed a 430 IU/L value.

The CT-scan revealed an infiltrative mass in the right parotid gland, with a maximum diameter of 5 cm. A parotidectomy was performed under general anaesthesia.

Gross examination of the parotid gland showed a white-greyish mass characterized by low consistency, well encapsulated, multinodular, with 5.5 cm in maximum diameter. Specimen samples were fixated with 10% buffered formalin and were processed by conventional histopathological methods using paraffin embedding, sectioning and Hematoxylin-Eosin (HE) staining.

Histopathological examination of the specimen revealed a tumor that destroyed the salivary gland parenchyma and showed an infiltrative diffuse (30%) and nodular (70%) pattern with atypical lymphoid cells, round to oval, large, vesicular, hyperchromatic nuclei with conspicuous nucleoli, resembling centroblasts, apoptotic bodies and numerous mitoses (Figure 1A). No lymphoepithelial lesions were identified.

The following mandatory investigations were immunohistochemical tests that required acquisition of paraffin blocks by histopathological processing. To begin with, the paraffin blocks were sliced at microtome and the resulting sections with 3- μ m thickness were mounted on slides covered with poly-L-Lysine. After that, the sections were deparaffinised in toluene and alcohol successive baths, one hour (15 minutes by bath), rehydrated (three successive alcohol baths with decreased concentration: 96%, 80% and 70% (10 minutes in each bath) and followed by a bath with distillate water for 10 minutes. Washing in PBS (phosphate-buffered saline), incu-

bation with normal serum, for 20 minutes, incubation with primary antibody over-night, Dako LSAB kit, washing in carbonate buffer and development in 3,3'-diaminobenzidine hydrochloride/ hydrogen peroxide and nuclear counterstain with Mayer's Haematoxylin were the intermediate steps. We used the following antibodies from Biocare: CD 20 antibody (mouse monoclonal, clone: L-26, dilution in 200 μ l 1:75); BCL2a antibody (mouse monoclonal, clone: D5/100, dilution in 200 μ l 1:200); BCL6 antibody (mouse monoclonal, clone: LN 22, dilution in 200 μ l 1:100); c-MYC (rabbit monoclonal, clone: Y69, dilution in 200 μ l 1:75); CD10 antibody (mouse monoclonal, clone: 56C6, dilution in 200 μ l 1:75); MUM1 antibody (rabbit monoclonal, clone: BC5, dilution in 200 μ l 1:200); CD 4 antibody (mouse monoclonal, clone: 4B12, dilution in 200 μ l 1:100); CD 8 antibody (rabbit monoclonal, clone: SP16, dilution in 200 μ l 1:75) Ki67 antibody (rabbit monoclonal, clone: SP6, dilution in 200 μ l 1:100). We also used in situ hybridization: RISH™ EPSTEIN-BARR ENCODED RNA (EBER) probe ready-to-use.

Immunohistochemistry studies confirmed the clonal B-cell nature of the tumor. Based on the histopathological report and immunohistochemistry tests, a diagnosis of diffuse large B-cell lymphoma associated with follicular lymphoma was made. Immunohistochemistry showed CD 20 (Figure 1B), BCL 2 (Figure 1C), BCL6 (Figure 1D), MYC (Figure 1E) positivity and CD 10, MUM1, EBER negativity. CD4 and CD8 showed positivity in a nodular staining pattern. Ki67 (proliferation index) (Figure 1F) was very high (95%).

After this diagnosis, the patient underwent systemic imaging studies, which revealed expansive masses in the right lateral cervical region and parapharyngeal space, with no other lesions reported. Bone marrow study was unremarkable and the haematologist established a clinical stage IV disease. The patient started treatment using chemotherapy with CNOP regimen (cyclophosphamide, mitoxantrone, vincristine and prednisone). The physician added additional treatment choosing Oncotron instead of Adriablastin because of the age and comorbidities. After one month, the patient also received Rituximab.

After 4 months, a CT-scan was made and the results highlighted an expansive mass with 9 cm in maximum diameter that infiltrated the skull base, the middle of the right clavicle, right external auditory canal, right pharyngeal recess, common carotid artery, mylohyoid and hypoglossal right muscle, without bone involvement.

Diagnosis of relapsed disease was established and the patient received polychemotherapy with Hyper CVAD (cyclophosphamide, vincristine, doxorubicin, dexamethasone). After the treatment, the patient suffered severe aplasia and pancytopenia and died 6 months after the initial diagnosis.

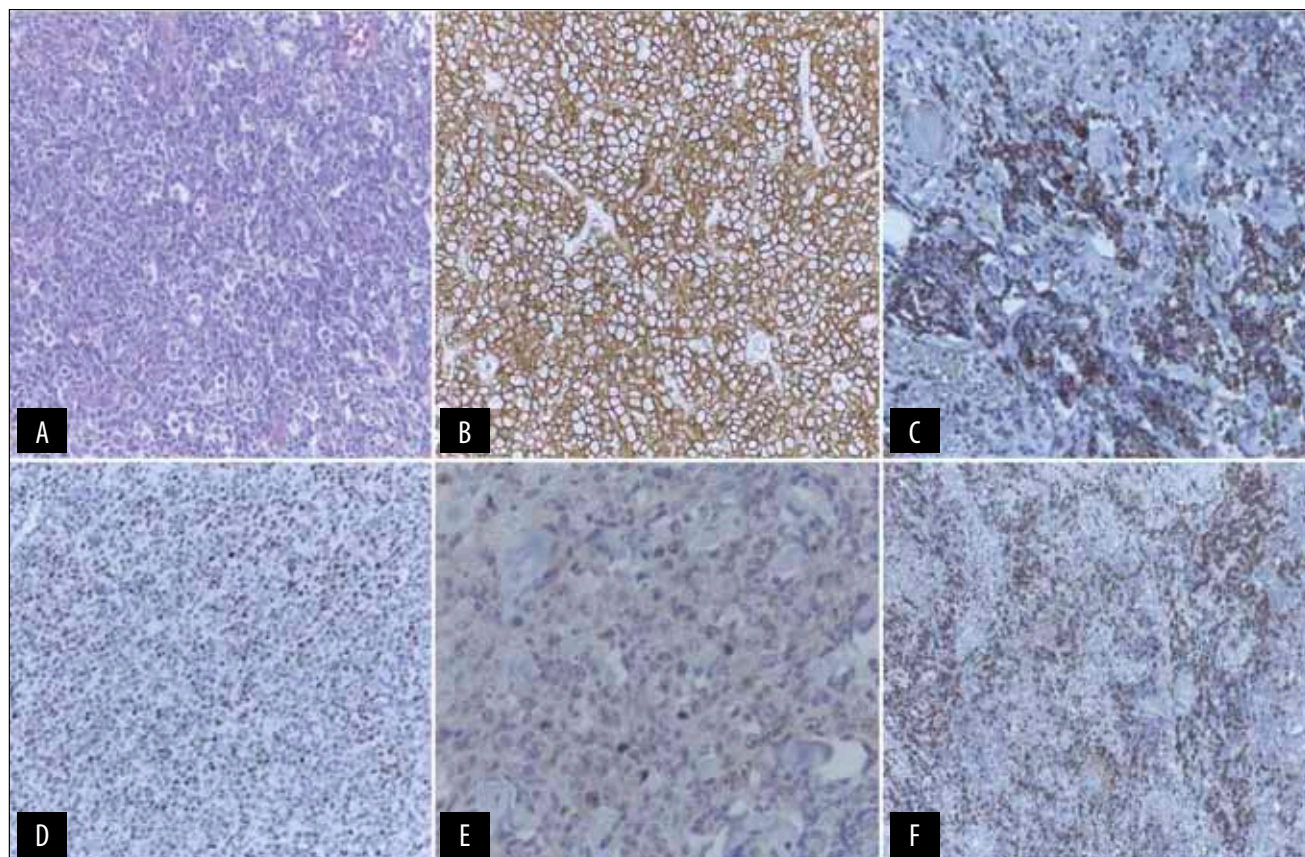


Figure 1 A. HE Ob 20x: Diffuse lymphoid proliferation with cells resembling centroblasts with oval nuclei and one or more nucleoli. B. CD 20 Ob 20x: Membrane staining tumor cells. C. BCL 2 Ob 20x: Nuclear staining in lymphoid atypical cells. D. BCL 6 Ob 20x: Nuclear staining in lymphoid malignant cells. E. MYC Ob 4x: Positive in the nuclei of the malignant cells. F. Ki67 Ob 10x: Positive in the nuclei of almost all the malignant cells.

DISCUSSIONS

Malignant lymphomas developing primarily in the salivary glands are exceptionally rare. Only a few case reports are available in the literature. They are commonly seen in the parotid gland followed by submandibular glands regarding location⁷. The age interval is fairly wide and nonspecific with a mean age of 70 years, the disease afflicting typically adults and older people⁸. Most parotid gland NHLs are of B-cell lineage, including low-grade MALT lymphoma, rarely diffuse large B-cell lymphoma. These may arise from the intraparotid lymph nodes or the gland itself. The parotid gland contains as histological characteristic intraparotid lymph nodes and, in consequence, it is difficult to distinguish between lymphoma arising primarily in the salivary gland and those arising in intraparotid lymph nodes^{9,10}. Hyman and Wolff proposed several criteria in order to establish the diagnosis of primary parotid lymphoma:

- Involvement of the salivary gland as a first clinical presentation.
- The histopathological report outlines the involvement of the salivary gland parenchyma.

c. Architectural and cytological confirmation of the malignant nature of the infiltrate. Following these three criteria, our case was diagnosed as a primary parotid lymphoma^{9,10}.

Patients with primary Sjogren's syndrome showed a 16-44 higher risk to develop lymphomas than the general population, as reported by two large case series studies¹¹. DLBCL is a high-grade infiltrative tumor associated with destruction of the salivary gland parenchyma, with lymphoid cells disrupting the residual gland acini¹². Freedman et al noted a relationship between the histopathological nodular pattern and a prolonged survival rate¹³.

Patients with DLBCL can be divided into prognostic groups based on the cell of origin of the tumor as determined by the microarray analysis. The Choi and Hans algorithm had high concordance with the microarray results classifying DLBCLs into germinal center B-cell (GCB) and non-GCB or activated B-cell-like (ABC) subtypes. Patients with GCB or ABC DLBCLs may benefit from different therapeutic approaches with the ABC subtype responding to novel drugs (bortezomib, lenalidomide or ibrutinib)¹⁴. Among the published immunohistochemical algorithms, the Hans algorithm was most widely used in routine practice

and prognostic significance has been questioned, especially in the chemioimmunotherapy era¹⁵⁻¹⁹.

As described before, this case with MYC, BCL 2 and BCL 6 translocations was classified as a triple hit lymphoma (THL), which has the worst outcome^{20,21}. The clinical implications of a correct diagnosis of this entity are significant because of the fact that triple hit lymphomas have shown worse clinical prognosis than either DLBCL or Burkitt lymphoma (BL). In consequence, it is important to select the right therapeutic strategy as they vary accordingly. Standard chemotherapy used for DLBCL or BL is not efficient in this case, mostly because of the particular genetic profile and the worse clinical course²². Some studies have outlined a median survival time 5 months shorter than for the more frequent lymphomas, classical DLBCL or BL.

Extensive literature review on triple hit lymphomas uncovered a paucity of case reports on this matter. Their rarity and the fact that clinical evolution is unfavourable have made establishing a precise incidence virtually impossible⁶.

A few published studies that shared the same genetic BCL2/MYC translocations in DLBCLs provided a range of 3-11% in incidence, but further data collection and analysis are necessary^{23,24}.

CONCLUSIONS

Parotid gland swelling is a common clinical presentation both in benign and malignant lesions. Imaging studies and biopsy are not always helpful and the majority of patients require parotidectomy for definitive diagnosis.

Histopathological report and immunohistochemistry studies are necessary for final diagnosis and treatment.

What remains a challenge for these types of lymphomas is recognizing the necessity for molecular studies. A personalized treatment plan is mandatory, as THL benefit from targeted therapy. In consequence, we routinely perform BCL-2, BCL-6 and MYC on a specific subset of DLBCL: any B-cell lymphoma with features intermediate between DLBCL and BL, any lymphoma with a Ki67 proliferation index higher than 90% and any DLBCL that has recurred or it is refractory to therapy.

It is important to recognize the histopathological and immunohistochemical unique features of this kind of lymphoma because of its unspecific symptoms, rarity, aggressive behaviour and targeted treatment.

Conflict of interest: The authors have no conflict of interest.

Contribution of authors: All authors have equally contributed to this work.

REFERENCES

- Sarris A.H., Papadimitrakopoulou V., Dimopoulos M.A., Smith T., Pugh W., Ha C.S., McLaughlin P., Callender D., Cox J., Cabanillas F. - Primary parotid lymphoma: the effect of International Prognostic Index on outcome. *Leuk Lymphoma*, 1997;26(1-2):49-56.
- Gleeson M.J., Bennett M.H., Cawson R.A. - Lymphomas of salivary glands. *Cancer*, 1986;58(3):699-704.
- Harris N.L. - Lymphoid proliferations of the salivary glands. *Am J Clin Pathol*, 1999;111(1 Suppl 1):S94-S103.
- Ampil F.L., Misra R.P. - Malignant lymphoma of the salivary gland: Case reports and review of the literature. *Radiat Med*, 1987;5(1):20-26.
- Ekstrom Smedby K., Vajdic C.M., Falster M., Engels E.A., Martinez-Maza O., Turner J., et al. - Autoimmune disorders and risk of non-Hodgkin lymphoma subtypes: a pooled analysis within the InterLymph Consortium. *Blood*, 2008;111(8):4029-4038. doi: 10.1182/blood-2007-10-119974. Epub 2008 Feb 8.
- Tomita N. - BCL2 and MYC dual-hit lymphoma/leukemia. *J Clin Exp Hematop*, 2011;51(1)7-12.
- Almothafar B., Wong L., Noorafidah M.D. - Primary large B cell lymphoma of the parotid gland: Case report. *JUMMEC*, 2011;14(1):26-30.
- Samanta M., Ratha B., Mallik A.K., Mishra M. - Disseminated non-Hodgkin's lymphoma presenting as unilateral parotid gland enlargement with facial nerve palsy. *Med J DY Patil Univ*, 2014;7(5):683-685.
- Dispenza F., Cicero G., Mortellaro G., Marchese D., Kulamarva G., Dispenza C. - Primary non-Hodgkins lymphoma of the parotid gland. *Braz J Otorhinolaryngol*, 2011;77(5):639-644.
- Faur A., Lazăr E., Cornianu M., Dema A., Lăzureanu C., Mureșan A., Taban S. - Primary malignant non-Hodgkin's lymphoma of salivary glands. *Rom J Morphol Embryol*, 2009;50(4):693-699.
- Kim C.S., Choi Y.D., Choi J.S., Bae E.H., Ma S.K., Kim S.W. - EBV-positive diffuse large B-cell lymphoma in a patient with primary Sjogren's syndrome and membranous glomerulonephritis. *BMC Nephrol*, 2012;13:149. doi: 10.1186/1471-2369-12-149.
- Tadashi T. - Primary diffuse large B-cell lymphoma of the submandibular gland. *Int J Clin Exp Pathol*, 2012;5(2):179-181.
- Freeman C., Berg J.W., Cutler S.J. - Occurrence and prognosis of extranodal lymphomas. *Cancer*, 1972;29(1):252-260.
- Choi W.W., Weisenburger D.D., Greiner T.C., Piris M.A., Banham A.H., Delabie J., Brazier R.M., Geng H., Iqbal J., Lenz G., et al. - A new immunostain algorithm classifies diffuse large B-cell lymphoma into molecular subtypes with high accuracy. *Clin Cancer Res*, 2009;15(17):5494-5502. doi: 10.1158/1078-0432.CCR-09-0113. Epub 2009 Aug 25.
- Coutinho R., Clear A.J., Owen A., Wilson A., Matthews J., Lee A., Alvarez R., Gomez da Silva M., Cabecadas J., Calaminici M., Gribben J.G. - Poor concordance among nine immunohistochemistry classifiers of cell-of-origin for diffuse large B-cell lymphoma: implications for therapeutic strategies. *Clin Cancer Res*, 2013;19(24):6686-6695. doi: 10.1158/1078-0432.CCR-13-1482. Epub 2013 Oct 11.
- Hans C.P., Weisenburger D.D., Greiner T.C., Gascoyne R.D., Delabie J., Ott G., Muller-Hermelink H.K., Campo E., Brazier R.M., Jaffe E.S., Pan Z., Farinha P., Smith L.M., Falini B., Banham A.H., Rosenwald A., Staudt L.M., Connors J.M., Armitage J.O., Chan W.C. - Confirmation of the molecular classification of diffuse large B-cell Lymphoma by immunohistochemistry using a tissue microarray. *Blood*, 2004;103(1):275-282. Epub 2003 Sep 22.
- Hwang H.S., Park C.S., Yoon D.H., Suh C., Huh J. - High concordance of gene expression profiling-correlated immunohistochemistry algorithms in diffuse large B-cell lymphoma, not otherwise specified. *Am J Surg Pathol*, 2014;38(8):1046-1057. doi: 10.1097/PAS.0000000000000211.
- Benesova K., Forstero K., Votavova H., Campr V., Stritesky J., Velenska

- Z., Prochazka B., Pytlík R., Trněný M. - The Hans algorithm failed to predict outcome in patients with diffuse large B-cell lymphoma treated with Rituximab. *Neoplasma*, 2013;60(1):68-73. doi: 10.4149/neo_2013_010.
19. Gutierrez-García G., Cardesa-Salzmán T., Climent F., González-Barca E., Mercadal S., Mate J.L., Sancho J.M., Arenillas L., et. al. - Gene-expression profiling and not immunophenotypic algorithms predicts prognosis in patient with diffuse large B-cell lymphoma treated with immunochemotherapy. *Blood*, 2011;117(18):4836-4843. doi: 10.1182/blood-2010-12-322362. Epub 2011 Mar 25.
20. Sarkozy C., Traverse-Glehen A., Coiffier B. - Double-hit and double-protein-expression lymphomas: aggressive and refractory lymphomas. *Lancet Oncol.*, 2015;16(15):e555-e567. doi: 10.1016/S1470-2045(15)00005-4.
21. Lu T.X., Fan L., Wang L., Wu J.Z., Miao K.R., Liang J.H., Gong Q.X., Wang Z., Young K.H., Xu W., Zhang Z.H., Li J.Y. - MYC or BCL2 copy number aberration is a strong predictor of outcome in patients with diffuse large B-cell lymphoma. *Oncotarget*, 2015;6(21):18374-18388. doi: 10.18632/oncotarget.4073.
22. Motllo C., Grau J., Junca J., Ruiz N., Mate J.L., Orna E., Navarro J.T., Vives S., Sancho J.M., Esteban D., Granada I., Feliu E., Ribera J.M., Milla F. - Translocation (3;8)(q27;q24) in two cases of triple hit lymphoma. *Cancer Genet Cytogenet.*, 2010;203(2):328-332. doi: 10.1016/j.cancergen-cyto.2010.08.018.
23. Pedersen M.O., Gang A.O., Poulsen T.S., Knudsen H., Lauritzen A.F., Nielsen S.L., Gang U.O., Nargaard P. - Double-hit BCL2/MYC translocations in a consecutive cohort of patients with large B-cell lymphoma - a single centre's experience. *Eur J Haematol.*, 2012;89(1):63-71. doi: 10.1111/j.1600-0609.2012.01787.x. Epub 2012 Apr 26.
24. Savage K.J., Johnson N.A., Ben-Neriah S., Connors J.M., Sehn L.H., Farinha P., Horsman D.E., Gascoyne R.D. - MUC gene rearrangements are associated with a poor prognosis in diffuse large B-cell lymphoma patients treated with R-CHOP chemotherapy. *Blood*, 2009;114(17):3533-3537. doi: 10.1182/blood-2009-05-220095. Epub 2009 Aug 24.

© 2017 Adelina Birceanu, Anca Evsei, Adrian Dumitru, Maria Sajin, Codrut Sarafoleanu, published by Romanian Rhinologic Society



This is an open access article published under the terms and conditions of the Creative Commons Attribution-NonCommercial-NoDerivatives 4.0 International (CC BY-NC-ND 4.0) License (<https://creativecommons.org/licenses/by-nc-nd/4.0/>). CC BY-NC-ND 4.0 license requires that reusers give credit to the creator by citing or quoting the original work. It allows reusers to copy, share, read, download, print, redistribute the material in any medium or format, or to link to the full texts of the articles, for non-commercial purposes only. If others remix, adapt, or build upon the material, they may not distribute the modified material.