

## CASE REPORT

# Endoscopic orbital decompression in Graves ophthalmopathy - Case report

Vlad A. Budu<sup>1,2</sup>, Tatiana Decuseara<sup>2</sup>, Ioan Bulescu<sup>1</sup>, Andrei Panfiloiu<sup>2</sup>,  
Lavinia Georgiana Sava<sup>2</sup>, Mihai Tusaliu<sup>1,2</sup>

<sup>1</sup>“Carol Davila” University of Medicine and Pharmacy, Bucharest, Romania

<sup>2</sup>“Prof. Dr. D. Hociota” Institute of Phono-Audiology and Functional ENT Surgery, Bucharest, Romania

## ABSTRACT

Graves ophthalmopathy, an autoimmune disease, associated with hypermetabolism, enlargement of the thyroid gland and exophthalmia are the most frequent expressions of Graves' disease, which often require surgical treatment. We present the case of a 41-year-old male with severe Graves ophthalmopathy for which we performed an endoscopic orbital decompression with good surgical outcome, the patient being discharged after 48 hours.

**KEYWORDS:** endoscopic sinus surgery, Graves ophthalmopathy, orbital decompression.

## INTRODUCTION

Graves ophthalmopathy (GO) is an autoimmune disorder first described in 1835 by Robert Graves and it represents the most frequent and important expression of Graves' disease, which causes cosmetic changes and dysfunctionalities<sup>1</sup>. Women are more frequently affected than men, with a female to male ratio of 4:1. It is a disorder with an incidence of 42 per million per year<sup>2</sup>. When eyelid changes are excluded, GO is clinically apparent in 10-25% of patients and, if eyelid changes are included, it appears in 30-45% of patients<sup>3</sup>.

Graves disease is associated with hypermetabolism, enlargement of the thyroid gland and exophthalmos, the orbit being affected due to the expression of organ-specific autoantibodies against the thyroid-stimulating receptor (TSH receptor), which is present in both thyroid and periocular tissue<sup>2</sup>. GO is an extenuating disease that adversely interferes with the quality of life of the affected patients. The spectrum of eye changes range from eyelid retraction, which results in the appearance of a “stare”, to proptosis, corneal exposure and ulceration, diplopia and loss of vision. Its symptomatology implies chemosis, conjunctivitis and mild proptosis,

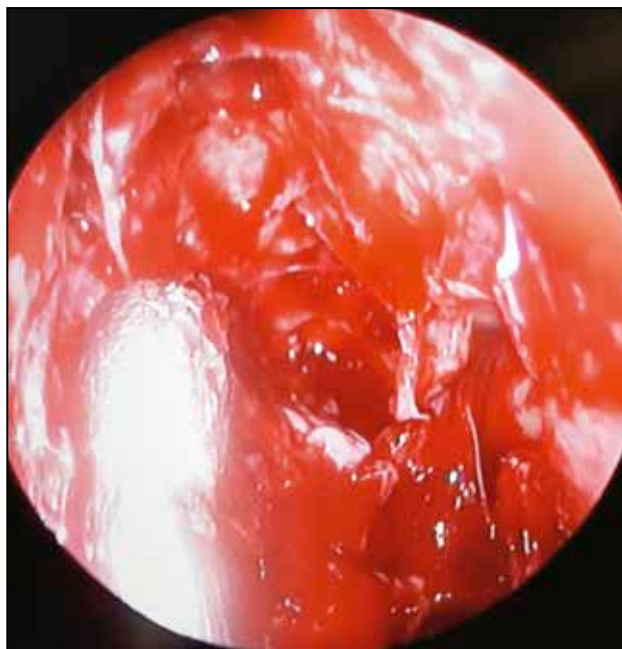and also lid lag, which are nonspecific signs.

Surgical decompression was first described by Dollinger<sup>4</sup> who advocated removal of the lateral orbital wall for decompression into the temporal fossa (the Krönlein procedure). Decompression into the paranasal sinuses was first analysed by Sewell<sup>5</sup> who described decompression into the ethmoid sinus, and later it was Hirsch<sup>6</sup> who reported the removal of the inferior orbital floor with decompression into the maxillary sinus. Indications for orbital decompression are: visual acuity, lagophthalmos and cosmetic aspect. Advantages of endoscopic orbital decompression (EOD) relative to open approaches include improved visualization of key anatomical landmarks<sup>5</sup>, lower complication rates and the obviation of facial scars. There may be several types of orbital decompression: endoscopic decompression of one wall, two walls, three walls.

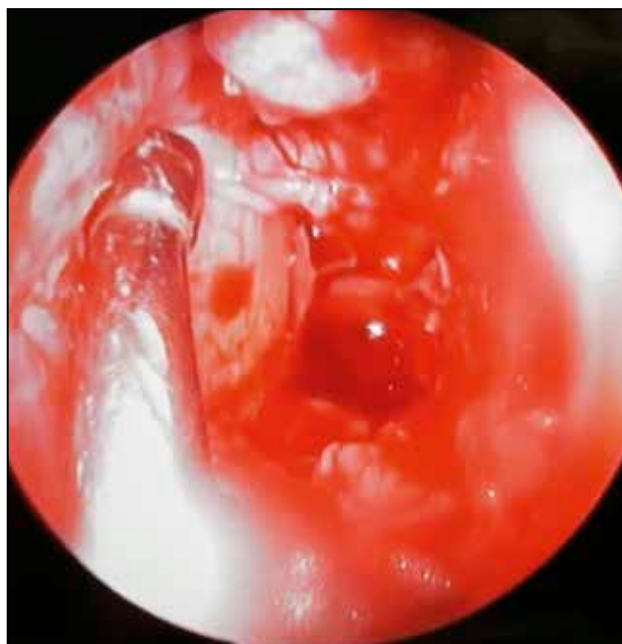## CASE REPORT

In September 2016, a 41-year-old man with severe GO symptoms was referred by ophthalmologists at the Institute of Phono-Audiology and Functional

Surgery of Bucharest, 1<sup>st</sup> Department. He experienced chronic eye pain, inconstant double vision, chemosis, proptosis, swelling of the upper and lower eyelids and the retraction of the upper eyelid. The funduscopic examination revealed papilloedema. Thin-slice computed tomography of the orbits revealed signs of GO, including enlarged intraorbital muscles and oedema of the periorbital fat. Accord-



**Figure 1** Lamina papyracea on the left side.



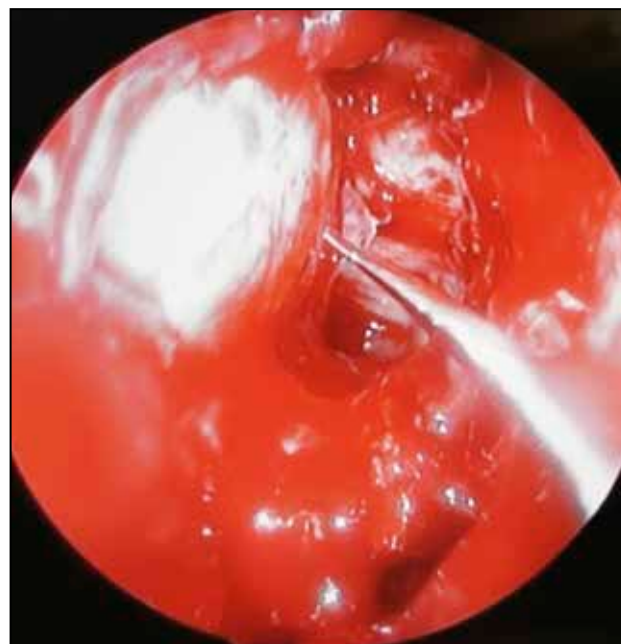
**Figure 2** Incision of the right periorbital.

ing to the Graves Orbitopathy Severity Assessment, the patient had the moderate grade<sup>7</sup>. It was decided to perform an endoscopic surgical decompression of both orbits. Therefore, the patient was scheduled for a one-wall decompression on both sides.

Under general anaesthesia, the uncinat process was removed and a total ethmoidectomy was performed. The lamina papyracea, the middle turbinate and the skull base were exposed (Figure 1). The lamina papyracea was decompressed from the anterior to the posterior area, starting superiorly close to the ethmoidal roof with the visualization of the periorbital. The Tenon capsule was visualized and incised with the sickle knife (Figure 2). The orbital fat prolapsed medially at first without any pressure on the eyeball, after which a little bit of pressure was applied on the eyeball within the area of the former ethmoidal cells (Figure 3). No fat was removed. Bleeding or CSF leak were excluded.

## RESULTS

One-wall endoscopic decompression has minimal complications, it does not need any nasal package and it has immediate cosmetic results. It is difficult to approximate the equivalence in quantity of the fat released from both orbits and if there is significant difference between the left and the right orbit, transient diplopia may occur (Figure 4).



In our case, 24-48 hours after surgery the diplopia diminished and the visual field returned to normal because of the eye plasticity and rearrangement of the orbital fat. The same surgical technique was applied on both orbits without any nasal package. Follow-up was made at one month, three months, six months and one year. The visual acuity and diplopia returned to normal. The patient did not re-

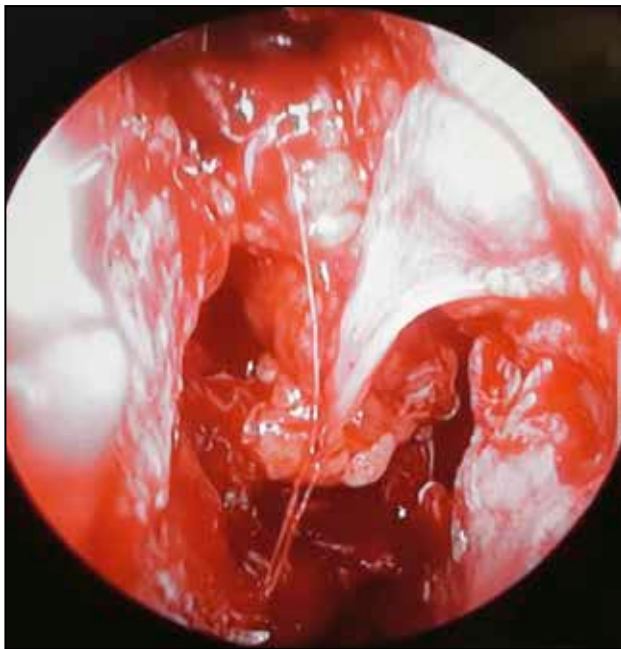
quire any other surgery after one year.

## DISCUSSIONS

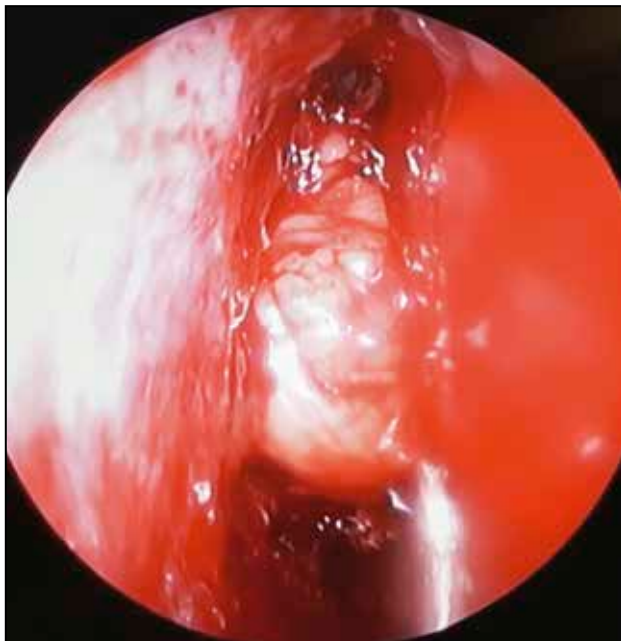
There are studies which report endoscopic approaches with an average of 1 to 8 mm reduction of proptosis with an endoscopic decompression of the medial wall, medial one-and-a-half wall, three wall, orbital apex<sup>8</sup>. This happens when there is no improvement from immunosuppressive therapy and radiotherapy, and when patients have an increased risk of dysthyroid optic neuropathy<sup>9</sup>. It is necessary to assess and measure the degree of orbital content decompression into the sinuses using the CT scans.

Endoscopic orbital decompression performed in patients with severe thyroid eye disease is not reported to be associated with any significant decrement in long-term sinonasal-specific quality of life<sup>10</sup>. Some studies claim to have multiple operations for secondary corrections on the same patients at the same time; therefore, follow-up is of utmost importance to achieve optimal results<sup>11</sup>.

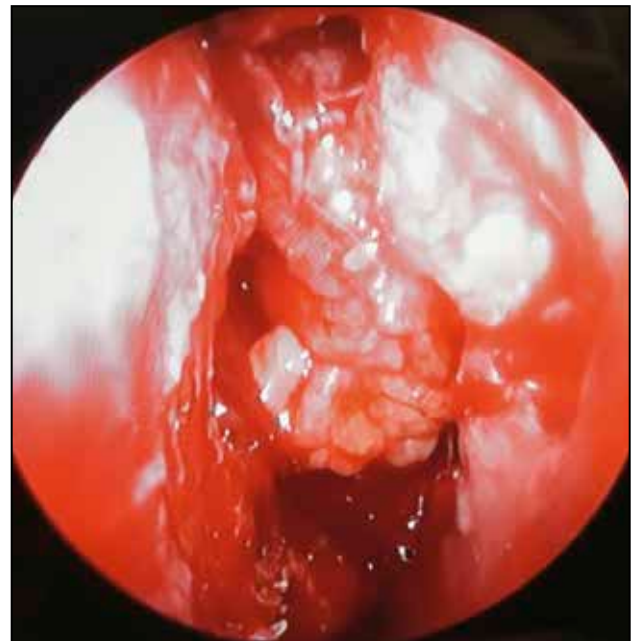One aspect to be mentioned to the patients is that after surgery they are prone to the activation of other inflammatory or autoimmune diseases. This is why perioperative intravenous methylprednisolone is taken into consideration as well as close monitoring in the early postoperative period<sup>8</sup>.



**Figure 3** Orbital fat on the left side.



**Figure 4** Orbital fat protrusion (right-left).



## CONCLUSIONS

Orbital decompression in GO can provide eye-ball and vision functionality in the context of a pathology, but also the aesthetic appearance; it implies a small cost of surgical intervention with short hospital stay, ranging between 24-48 hours. Endoscopic medial wall decompression improves the visual outcomes, the visual field as well as it reduces exophthalmos. Identification of risk factors for severe outcomes and early detection of ophthalmopathies are critical. CT scan and MRI imaging proved to be effective means in data acquisition, allowing exact proptosis measurement although the bony orbit has changed.

**Conflict of interest:** The authors have no conflict of interest.

**Contribution of authors:** All authors have equally contributed to this work.

## REFERENCES

1. Flint PW, Haughey BH, Lund VJ, Niparko JK, Robbins KT, Thomas JR, et al. Cummings Otolaryngology: Head and Neck Surgery. 6th Edition. Saunders; 2014, p.1969-74.
2. Abraham-Nordling M, Bystrom K, Torring O, Lantz M, Berg G, Calisendorff J, et al. Incidence of hyperthyroidism in Sweden. *Eur J Endocrinol.* 2011;165(6):899-905. DOI: 10.1530/EJE-11-0548. Epub 2011 Sep 9.
3. Braverman L, Utiger R. Werner and Ingbar's the thyroid: a fundamental and clinical text, 8th edition. Philadelphia: Lippincott Williams & Wilkins; 2000, p.531-48.
4. Dollinger J. Die Druckenlastung der Augenhöhle durch Entfernung der äusseren Orbitalwand bei hochgradigem Exophthalmus und konsekutive Horn hauterkrankung. *Dtsch Med Wochenschr.* 1911;37:1888-90.
5. Sewall EC. Operative control of progressive exophthalmos. *Arch Otolaryngol.* 1936;24(5):621-4. DOI: 10.1001/archotol.1936.00640050634010.
6. Hirsch O. Surgical decompression of malignant exophthalmos. *Arch Otolaryngol.* 1950;51(3):325-34. DOI: 10.1001/archotol.1950.00700020347004.
7. Bartalena L, Baldeschi L, Dickinson A, Eckstein A, Kendall-Taylor P, Marcocci C, et al. Consensus statement of the European Group on Graves' orbitopathy (EUGOGO) on management of GO. *Eur J Endocrinol.* 2008;158(3):273-85. DOI: 10.1530/EJE-07-0666.
8. Jefferis JM, Jones RK, Currie ZI, Tan JH, Salvi SM. Orbital decompression for thyroid eye disease: methods, outcomes, and complications. *Eye (Lond).* 2018;32(3):626-36. DOI: 10.1038/eye.2017.260. Epub 2017 Dec 15.
9. Seibel I, Hofmann VM, Sonmez H, Schonfeld S, Jumah MD, Lenarz M, et al. Medial and mediolateral orbital decompression in intractable Graves' Orbitopathy. *Auris Nasus Larynx.* 2017;44(4):428-34. DOI: 10.1016/j.anl.2016.08.007. Epub 2016 Sep 5.
10. Mueller SK, Miyake MM, Lefebvre DR, Freitag SK, Bleier BS. Long-term impact of endoscopic orbital decompression on sinonasal-specific quality of life. *Laryngoscope.* 2018;128(4):785-8. DOI: 10.1002/lary.26812. Epub 2017 Sep 25.
11. Imburgia A, Elia G, Franco F, Perri P, Franco E, Galie M, et al. Treatment of exophthalmos and strabismus surgery in thyroid-associated orbitopathy. *Int J Oral Maxillofac Surg.* 2016;45(6):743-9. DOI: 10.1016/j.ijom.2015.12.002. Epub 2016 Jan 6.

© 2018 Vlad A. Budu, Tatiana Decuseara, Ioan Bulescu, Andrei Panfiloiu, Lavinia Georgiana Sava, Mihai Tusaliu, published by Romanian Rhinologic Society



This is an open access article published under the terms and conditions of the Creative Commons Attribution-NonCommercial-NoDerivatives 4.0 International (CC BY-NC-ND 4.0) License (<https://creativecommons.org/licenses/by-nc-nd/4.0/>). CC BY-NC-ND 4.0 license requires that reusers give credit to the creator by citing or quoting the original work. It allows reusers to copy, share, read, download, print, redistribute the material in any medium or format, or to link to the full texts of the articles, for non-commercial purposes only. If others remix, adapt, or build upon the material, they may not distribute the modified material.