

CASE REPORT

Sphenoid rhinosinusitis associated with abducens nerve palsy – Case report

Lucian Lapusneanu¹, Marlena Radulescu¹, Florin Ghita²¹ENT Department, Braila Emergency County Hospital, Braila, Romania²Radiology Department, Braila Emergency Hospital, Braila, Romania**ABSTRACT**

The cases with sphenoid sinusitis associated with abducens nerve palsy are rarely cited in the literature. We present the case of a 41-year-old patient who was hospitalized for right hemicrania and ipsilateral paresis of the abducens nerve, without any other ENT previous pathology. The ENT, ophthalmologic, neurological and paraclinical evaluations (nasal endoscopy, MRI examination) have established the diagnosis of right sphenoid rhinosinusitis complicated with unilateral abducens nerve palsy. In such cases, it is important to make a differential diagnosis with tumor pathology as well as that of an infection outbreak located intracranially. In this case, the patient's evolution was favourable after endoscopic surgical treatment of the sphenoid rhinosinusitis.

KEYWORDS: sphenoid sinusitis, abducens nerve palsy, diplopia.

INTRODUCTION

Isolated sphenoid rhinosinusitis is a rare disease, with an incidence of 1-2% of all sinus infections. In the literature, there are very few cases of unilateral sphenoid rhinosinusitis associated with abducens nerve palsy. This type of sinusitis may present complications due to the anatomical location of the sphenoid sinus in relation to the intracranial and orbital contents.

Frequently, sphenoid rhinosinusitis is misdiagnosed, because the sphenoid sinus is not properly visualized on routine radiographs of the sinuses and it is not directly accessible during clinical examination¹. Because of the difficulty of diagnosis, sphenoid rhinosinusitis is characterized by significant morbidity and mortality².

CASE REPORT

A 41-year-old patient presented to the Neurology Department of the Braila Emergency County

Hospital, with right hemicrania and ipsilateral paresis of the abducens nerve, afebrile, without any other ENT pathology in history. Laboratory tests did not reveal any major changes (mild leukocytosis – 12500/mm³, PMN – 79%, ESR – 20mm/h).

The lateralization of the gaze to the right caused horizontal diplopia, which disappeared when closing an eye (Figure 1). The examination of the other cranial nerves did not reveal other associations. The examination of the ocular fundus and the bilateral visual acuity showed no changes.

The cranio-cerebral MRI exam revealed the opacification of the right sphenoid sinus (hypertrophy of the sinus mucosa and secretions at this level) (Figure 2).

Due to the clinical aspect of the symptomatology, the absence of signs of meningeal irritation, of vomiting, the paraclinical and laboratory investigations, the differential diagnoses of tuberculous and fungal meningitis, other opportunistic infections, intracranial and eyeball tumors have been excluded.

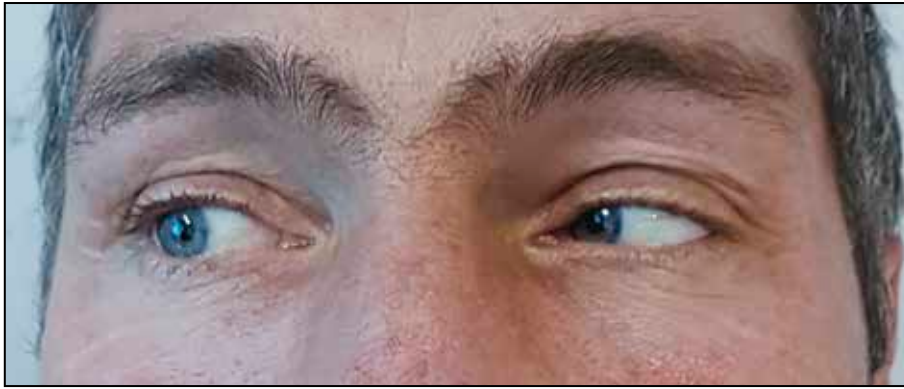

Figure 2 Right abducens nerve palsy; right lateral gaze diplopia.

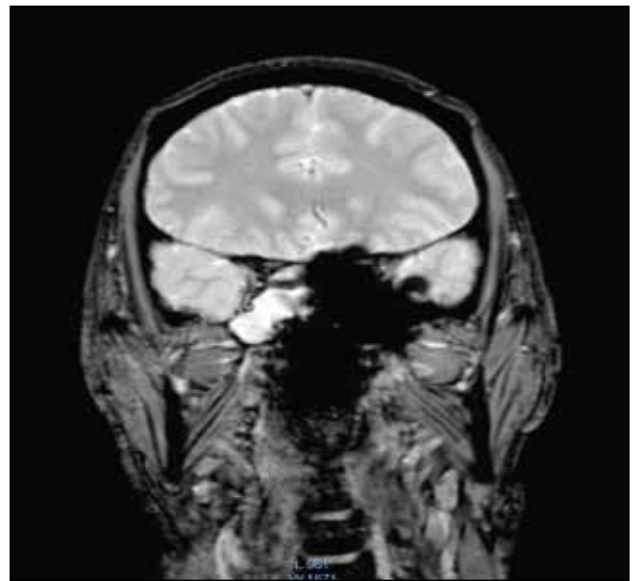
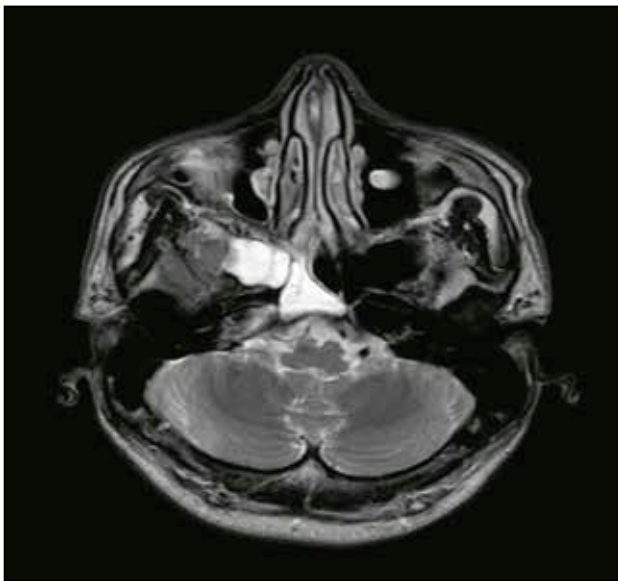

Figure 2 Cranio-facial MRI, axial (A) and coronal (B) section: opacification of the right sphenoid sinus due to the fluid content and the inflamed mucosa.

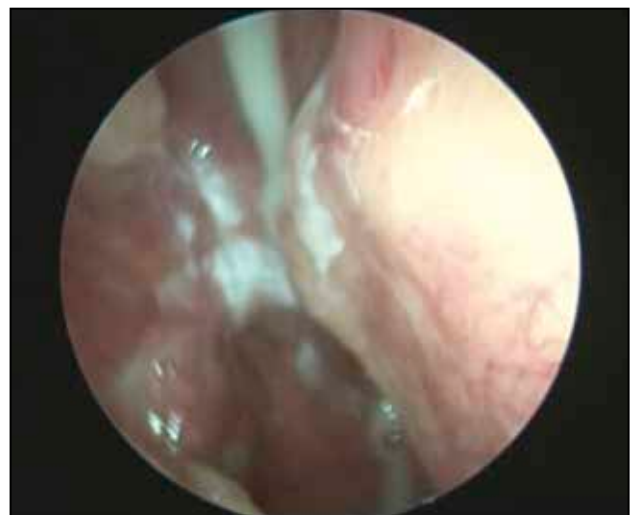
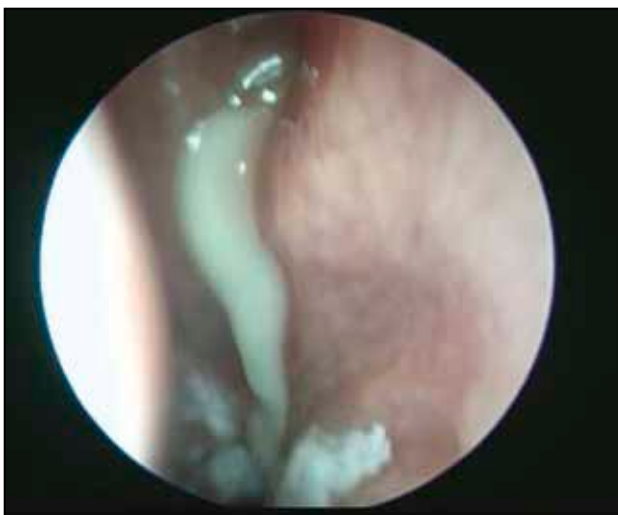
Figure 4 Intraoperative view - highlighting the sphenoid ostium, with local evacuation of purulent secretions.

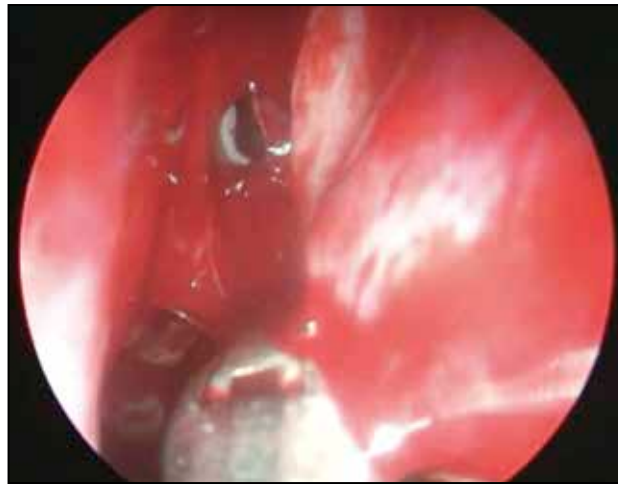

Figure 5 Right sphenoid sinus ostium.

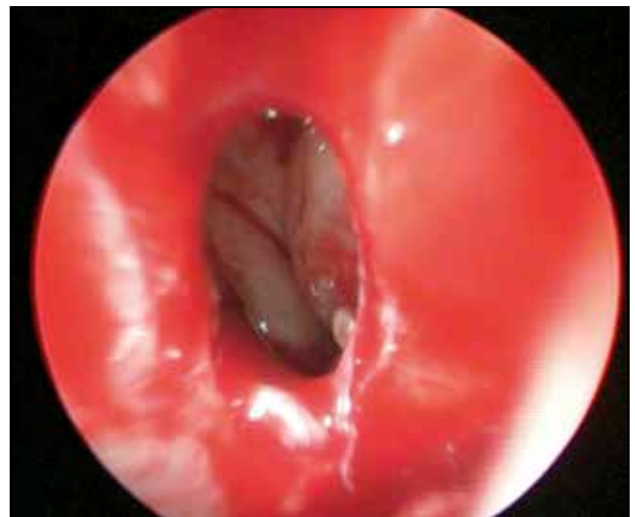
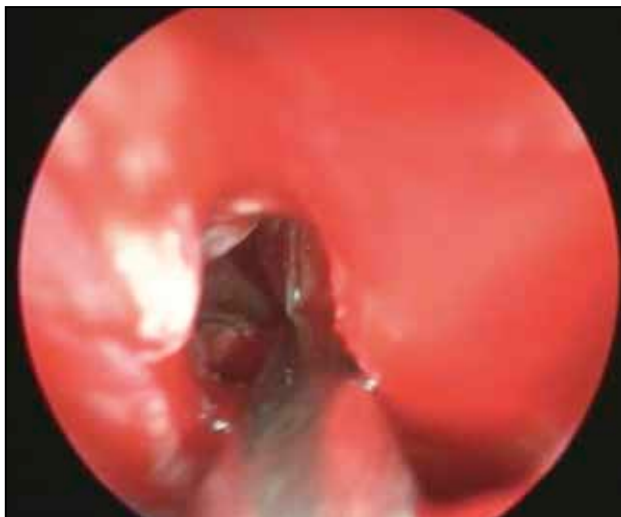
Figure 6 Intraoperative view – the enlargement of the right sphenoid ostium, highlighting the inflamed intrasinusal mucosa.

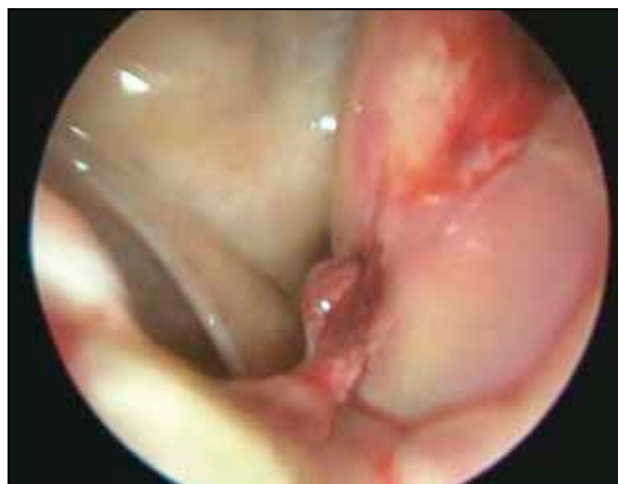

Figure 7 Right sphenoid sinus ostium.

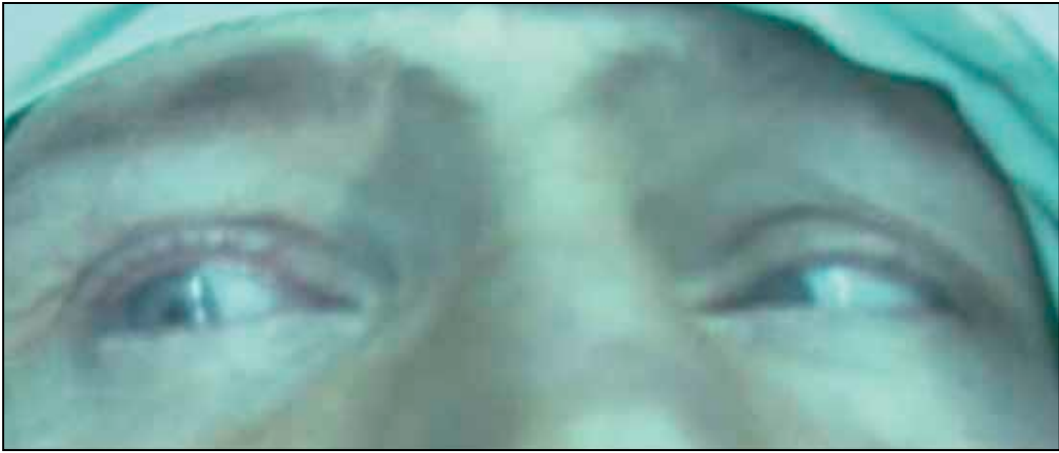

Figure 8 Reduction in paresis and diplopia, immediately postoperatively.

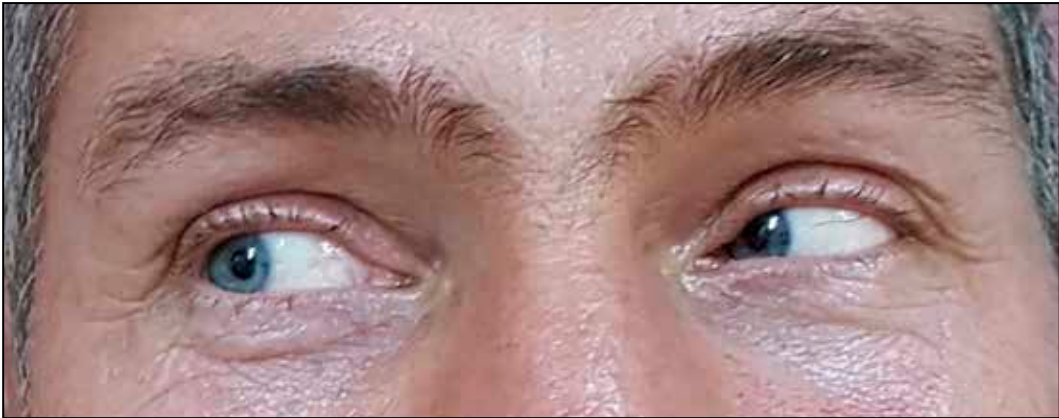

Figure 9 Significant reduction of diplopia on the third postoperative day.

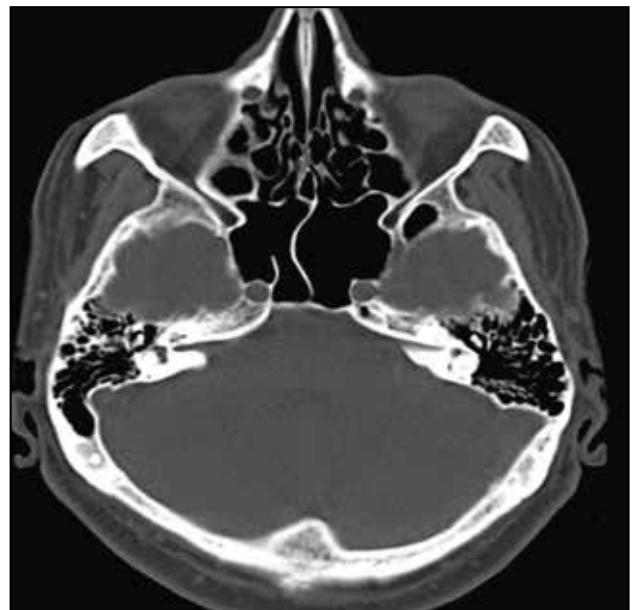
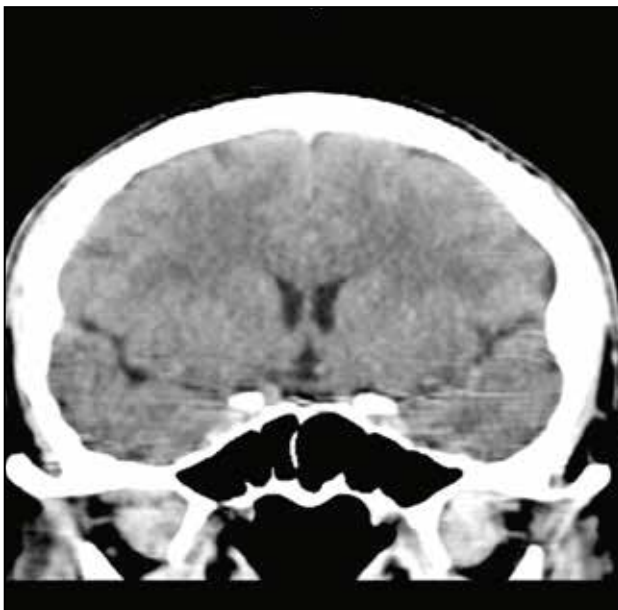


Figure 10 Crano-facial CT performed on day 30 postoperatively (coronal and axial section) – normal appearance of the paranasal sinuses.

An interdisciplinary ENT examination was requested, which supported the diagnosis of abducens nerve palsy associated with acute right sphenoid rhinosinusitis; that is why it was decided to transfer the patient to the ENT Department.

Surgical treatment (transnasal endoscopic sphenoidotomy) was preceded by 24 hours of general antibiotic and steroidal anti-inflammatory drugs administration.

The surgery was performed under local anaesthesia. After the decongestion of the nasal mucosa at the level of the right middle and superior meatus, the middle nasal concha was lateralized under endoscopic control and partial resection of the inferior portion of the superior concha with identification of the anterior wall and the sphenoid sinus ostium was performed (Figure 4). Purulent secretions discharged under pressure from the right sphenoid sinus could be visualized at this level. The sinus ostium was widened with the Kerrison forceps and the straight curette (Figure 5). The purulent sinus contents were evacuated, while the septa and the intrasinus inflammatory mucosa were removed with the Struycken forceps, protecting the intrasinus tract of the internal carotid artery (Figures 6,7). At this point during the surgery, a sample was taken for bacteriological examination.

Lavage with physiological serum of the intrasinus cavity and intranasal packing with Mero-cel®, which was suppressed after 24 hours, were performed. Immediate postoperative evolution was favourable, the patient being able to partially achieve abduction of the right eyeball (Figure 8). Antibiotic and anti-inflammatory treatment was continued 5 days postoperatively.

On the third postoperative day, the mobility of the right eyeball when looking sideways has been restored to 90% and diplopia significantly diminished. Moreover, the patient reported the disappearance of headache (Figure 9).

The evaluation performed on day 7 and 30 post-surgically revealed the complete disappearance of diplopia, with complete abduction of the right eyeball.

The cranio-facial CT exam performed on day 30 postoperatively revealed the paranasal sinuses without pathological changes (Figure 10).

DISCUSSIONS

Isolated sphenoid rhinosinusitis is an uncommon pathology, representing 1.0% - 2.7% of all sinus diseases¹⁻⁵. Rarely, diplopia with ocular paralysis of the cranial nerves associated with hemi-

crania may be the initial symptoms of sphenoid sinusitis. Imaging is the gold standard in the correct diagnosis of isolated sphenoid sinusitis, the positive diagnosis being usually established using imaging studies (CT and / or MRI).

The most common symptom of sphenoid rhinosinusitis is headache. It can be located occipitally, frontally, temporally, retro-orbitally⁶. Hemicrania secondary to this form of sinusitis has been rarely reported⁷.

The most common cranial nerves palsy associated with the sphenoid infection cited in the literature is that of abducens nerve, followed by oculomotor nerve. The abducens nerve palsy has been reported in 6% of the cases with inflammatory conditions and in 50% of the cases with neoplasia⁶. Thus, most of the sphenoid sinus lesions, which are also manifested by ocular paralysis though direct involvement of the cranial nerves, are associated with a neoplastic process at the level of this sinus or extended at this level from an intracranial process.

Several possible mechanisms for the development of cranial nerve palsy associated with the sphenoid disease are suggested in the literature: 1. Direct extension of the inflammatory process from the sphenoid sinus, with infection of the nerve sheath that can lead to paralysis; 2. Nerve compression through the sphenoid mass, which extends to the cavernous sinus or to the superior orbital fissure; 3. Vasculitis or cavernous sinus thrombosis, which causes an ischemic stroke of the cranial nerve^{7,8}.

The abducens nerve is more commonly involved, due to its medial localization with respect to the cavernous sinus⁸.

CONCLUSIONS

Unilateral sphenoid rhinosinusitis accompanied by diplopia and hemicrania is rare. In such situations, one should exclude an intrasinus or intracranial neoplastic process extended into the region of the sphenoid sinus.

The CT and / or the MRI exam have an essential role in establishing the diagnosis, the etiology of the disorder and the surgical treatment.

Early surgery with antibiotic and anti-inflammatory treatment has an excellent result, with complete resolution of the symptoms.

Conflict of interest: The authors have no conflict of interest.

Contribution of authors: All authors have equally contributed to this work.

REFERENCES

1. Wang ZM, Kanoh N, Dai CF, Kutler DI, Xu R, Chi FL, et al. Isolated sphenoid sinus disease: an analysis of 122 cases. *Ann Otol Rhinol Laryngol.* 2002;111(4):323-7.
2. Lew D, Southwick FS, Montgomery WW, Weber AL, Baker AS. Sphenoid sinusitis. A review of 30 cases. *N Engl J Med.* 1983;309(19):1149-54.
3. Ruoppi P, Seppä J, Pukkila M, Nuutinen J. Isolated sphenoid sinus disease: a report of 39 cases. *Arch Otolaryngol Head Neck Surg.* 2000;126(6):777-81.
4. Lawson W, Reino AJ. Isolated sphenoid sinus disease: an analysis of 132 cases. *Laryngoscope.* 1997;107(12 Pt 1):1590-5.
5. Meckling SK, Becker WJ. Sphenoidal sinusitis presenting as indomethacin responsive "hemicranias continuaa": case report. *Cephalalgia.* 1997;17:303.
6. Krisht A, Barnett DW, Barrow DL, Bonner G. Blood supply of intracavernous cranial nerves: an anatomic study. *Neurosurgery.* 1994;34(2):275-9; discussions 279. DOI: 10.1227/0006123-199402000-00011.
7. Patt BS, Manning SC. Blindness resulting from orbital complications of sinusitis. *Otolaryngol Head Neck Surg.* 1991;104(6):789-95.
8. Sarafoleanu C, Manea C, Duda R. Isolated sphenoid sinusitis - Clinical and therapeutic aspects. *Romanian Journal of Rhinology.* 2011;1(3):135-8.

© 2018 Lucian Lapusneanu, Marlena Radulescu, Florin Ghita, published by Romanian Rhinologic Society



This is an open access article published under the terms and conditions of the Creative Commons Attribution-NonCommercial-NoDerivatives 4.0 International (CC BY-NC-ND 4.0) License (<https://creativecommons.org/licenses/by-nc-nd/4.0/>). CC BY-NC-ND 4.0 license requires that reusers give credit to the creator by citing or quoting the original work. It allows reusers to copy, share, read, download, print, redistribute the material in any medium or format, or to link to the full texts of the articles, for non-commercial purposes only. If others remix, adapt, or build upon the material, they may not distribute the modified material.