

## CLINICAL PHOTOGRAPHS

## Dysphagia due to cervical osteophytes

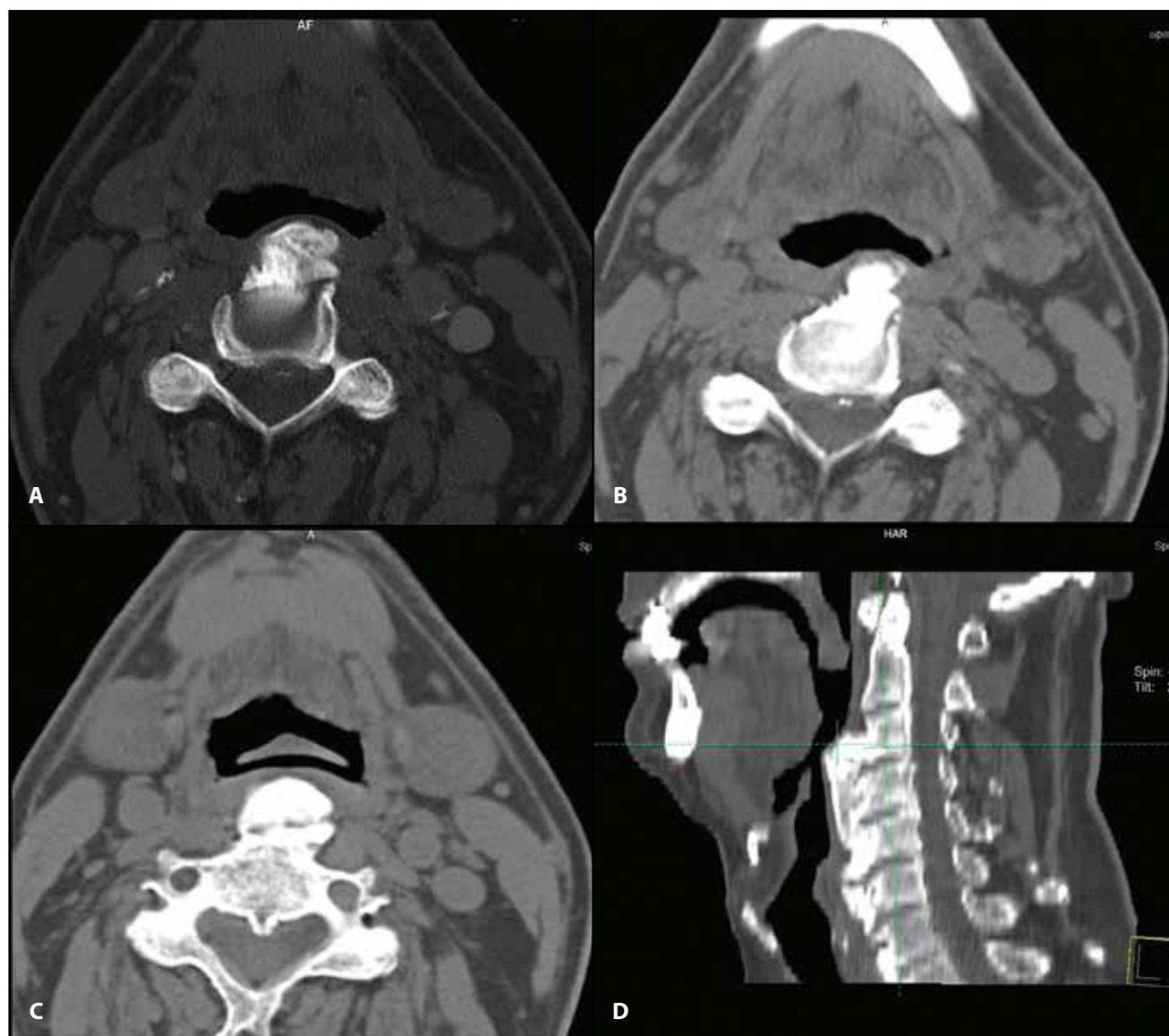
Codrut Sarafoleanu

ENT&amp;HNS Department, "Sfanta Maria" Hospital, Bucharest, Romania

"Carol Davila" University of Medicine and Pharmacy, Bucharest, Romania

A 65-year-old male patient presented to our ENT Department for progressive dysphagia. He described the symptom like a sensation of food getting stuck in the throat.

Prior, the patient had been evaluated clinically and paraclinically (neck CT scan) for the same symptoms in another ENT Department. After the evaluation he was diagnosed with: dysphagia



**Figure 1** Neck CT scan, axial (A,B,C) and sagittal (D) slices – cervical osteophytes, with secondary narrowing of the hypopharynx space.

**Corresponding author:** Prof. Dr. Codrut Sarafoleanu, ENT&HNS Department, "Sfanta Maria" Hospital, 37-39 Ion Mihalache Blvd., District 1, Bucharest, Romania  
e-mail: csarafoleanu@gmail.com

**Received for publication:** March 10, 2018 / **Accepted:** March 15, 2018

syndrome, obstructive nasal septum deviation. The treatment indications given by the ENT specialist for the progressive dysphagia consisted in: septoplasty, tonsillectomy and laser-assisted uvulopalatoplasty.

In this context, the patient addressed to us for a second opinion. Our clinical reevaluation identified a nasal septum deviation, eutrophic palatine tonsils, a normal aspect of the soft palate, but also the protuberance of the posterior wall of the hypopharynx with consecutive narrowing of the hypopharynx.

Analyzing the neck CT scan, we observed a narrowing at the hypopharynx space level due to cervical osteophytes (Figure 1A,B,C,D). The CT was in complete correlation with the local aspect

of the hypopharynx.

A deviated nasal septum, no matter the grade, cannot cause dysphagia. Also, it is well known that a chronic pathology of the palatine tonsils and the soft palate, if present, can be associated with sleep-breathing disorders and not with dysphagia.

Taking into consideration that the pharyngeal phase of swallowing is involuntary and that the narrowing of the hypopharynx can disturb the normal course of the bolus, we considered that the cause of the progressive dysphagia was the cervical osteophytes.

From our point of view, the previous treatment indications received by the patient were not necessary and would have not resolved the swallowing disorder.

© 2018 Codrut Sarafoleanu, published by Romanian Rhinologic Society



This is an open access article published under the terms and conditions of the Creative Commons Attribution-NonCommercial-NoDerivatives 4.0 International (CC BY-NC-ND 4.0) License (<https://creativecommons.org/licenses/by-nc-nd/4.0/>). CC BY-NC-ND 4.0 license requires that reusers give credit to the creator by citing or quoting the original work. It allows reusers to copy, share, read, download, print, redistribute the material in any medium or format, or to link to the full texts of the articles, for non-commercial purposes only. If others remix, adapt, or build upon the material, they may not distribute the modified material.