

LITERATURE REVIEW

Sinonasal inverted papilloma – what’s new

Andreea Marza¹, Codrut Sarafoleanu^{1,2,3}, Gabriela Musat^{1,2}

¹ENT&HNS Department, “Sfanta Maria” Hospital, Bucharest, Romania

²“Carol Davila” University of Medicine and Pharmacy, Bucharest, Romania

³Center of excellence for research of sensorial and sensitive disorders, study of infecto-inflammatory, tumoral and obstructive aero-digestive pathology (CESITO), ENT&HNS Department, “Sfanta Maria” Hospital, Bucharest, Romania

ABSTRACT

Inverted or Schneiderian papilloma is a locally aggressive benign tumor with strong recurring tendency and a high potential to transform into a malignant squamous cell carcinoma. Although the clinical characteristics of inverted papilloma, along with the morphological features, have been adequately described, controversy remains with regards to the risk factors and disease etiology. The complete excision of the tumor by surgery is traditionally considered the mainstay of therapy.

This paper updates the state of knowledge and presents our experience from treating 52 patients, diagnosed with inverted papilloma, who underwent surgical treatment in our department. We performed genotyping for Human Papilloma Virus (HPV) for all the patients included in our study group.

KEYWORDS: sinonasal inverted papilloma, HPV, squamous cell carcinoma.

INTRODUCTION

The sinonasal inverted papilloma (IP) is a locally aggressive benign tumor, with strong recurring tendency and a high potential to transform into a malignant squamous cell carcinoma (SCC)¹⁻⁴. Sinonasal inverted papillomas originate from the mucosal lining of the nasal passage and paranasal sinuses (the Schneiderian membrane). The pathogenic cause of this type of tumor has not been fully understood and controversial opinions highlight the potential role of the Human Papilloma Virus (HPV) in the development of the sinonasal inverted papillomas. The complete surgical excision of the tumor is traditionally considered the mainstay of therapy⁵. The surgery’s goal is to allow a sufficient tumoral exposure for total resection, and also to provide an unobstructed view for postoperative surveillance and minimize the risks associated with postoperative morbidity⁶⁻⁹.

INCIDENCE AND ETIOPATHOGENESIS

The sinonasal inverted papilloma has an incidence of 0.6-1.5/100.000 inhabitants per year, making it the most common sinonasal tumor of benign nature^{10,11}. Its incidence amounts to approximately 0.5-4% of all nasal tumors^{2,12}. The incidence is higher in men, with a 3.4:1 male-to-female ratio¹¹. Inverted papillomas mostly develop in the 5th – 7th decades of life, but they can be diagnosed in all age groups^{5,13}.

The tumor will mainly originate in the lateral nasal wall, near the middle meatus and will often extend to the paranasal sinuses¹⁴. This type of lesion has a tendency toward malignant transformation, and it is generally locally invasive¹⁵⁻¹⁷. The risk of malignancy degeneration ranges from 5 to 15%¹³.

Although the clinical characteristics of IP, along with the morphological features have been adequately described, controversy remains with regards

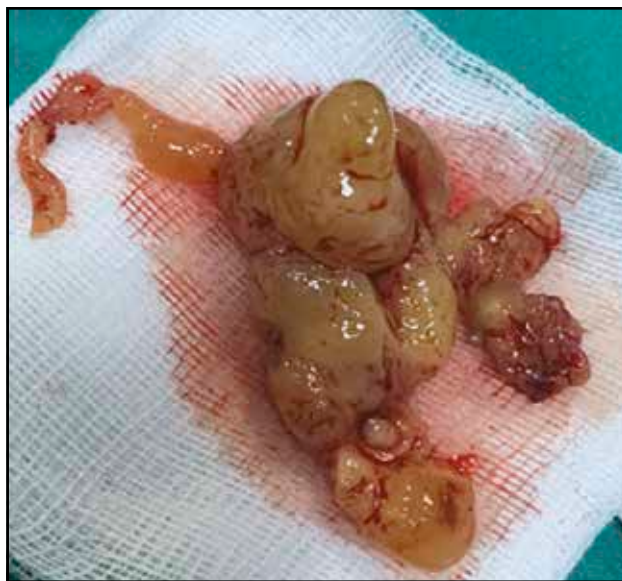

Figure 1. Typical macroscopic appearance of sinonasal inverted papilloma.

to the risk factors and disease etiology. With several hypotheses being suggested, causality has not been clearly established in relation to the suspected risk factors: allergy, smoking or occupational exposure to pollutants^{11,18}.

A potential viral origin was suggested for many years, due to the recurring nature and malignant potential of the tumor. Many authors studied the implication of Human Papilloma Virus (HPV) in the etiology of IP, but the data found in the literature are still contradictory. Different meta-analyses show that HPV rates between 17-38%¹⁰, 6 and 11 serotypes being associated with the benign form of IP, while 16 and 18 serotypes are related to malignancy¹⁹⁻²². There are also authors who do not sup-

port this theory^{19,23,24}. A recently published study from Mohajeri et al.²⁵ does not support the role the human papilloma virus plays as an etiological factor for disease recurrence or its potential progression to squamous cell carcinoma.

Several authors studied the role of Epstein-Barr Virus (EBV) in the etiology of IP, but none of the results supports its implication^{10,19}.

HISTOPATHOLOGY OF INVERTED PAPILLOMAS

In contrast to inflammatory polyps which result from the edematous hypertrophy of the respiratory epithelium, often associated with infection or allergy, sinonasal papillomas are benign tumors of the nasal epithelium. The Schneiderian papilloma term relates to the Schneiderian membrane, which is the embryologic origin of the mucous membranes of the nasal cavity. Schneiderian papillomas have been divided by the World Health Organization (WHO) into 3 different categories: 1) tumors with an endophytic growth pattern (inverted papilloma), 2) tumors with an exophytic growth pattern (fungiform papilloma) and 3) cylindrical cell papillomas^{5,26-28}.

Macroscopically, the sinonasal inverted papilloma may present as a polyp, but of firmer consistency, wider vascularity and with a convoluted, granular appearance (Figure 1).

Microscopic aspect of the sinonasal inverted papilloma is that of a digitiform proliferation of the respiratory or squamous epithelium with infiltration into the subjacent stroma, crypts and microcysts filled with mucus¹³ (Figure 2). In the stroma, there are chronic inflammatory modifications, edema, and the cells can present nuclear atypia.

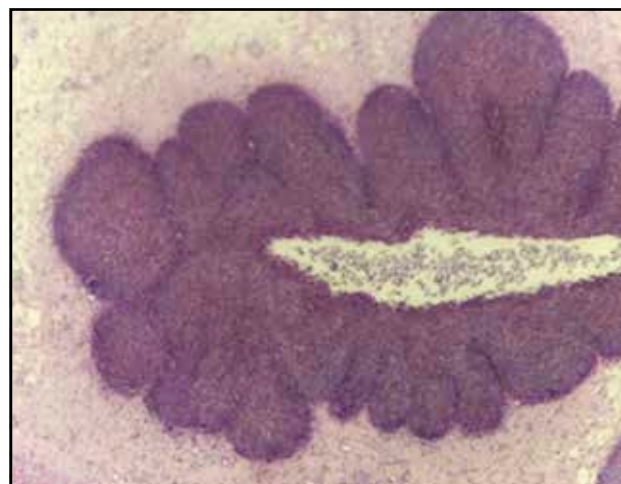
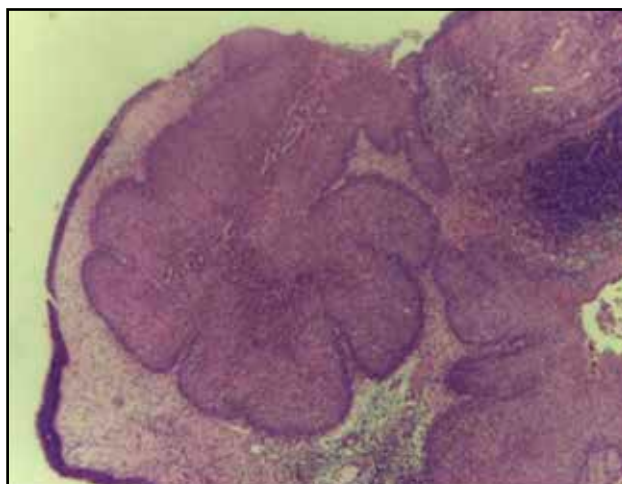
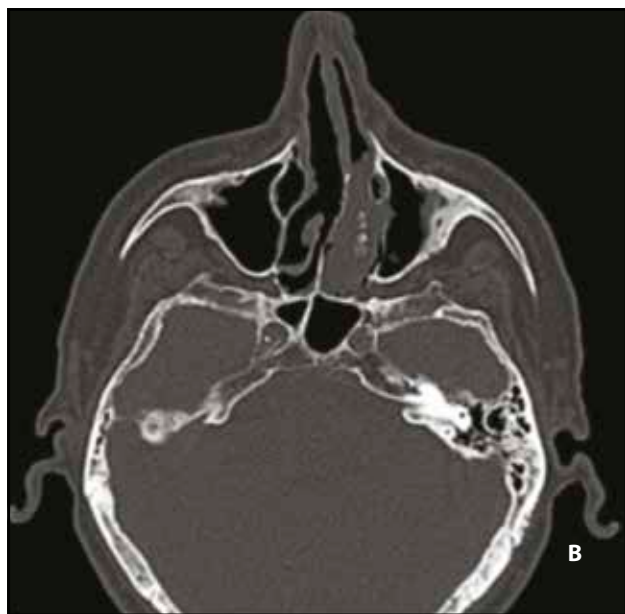
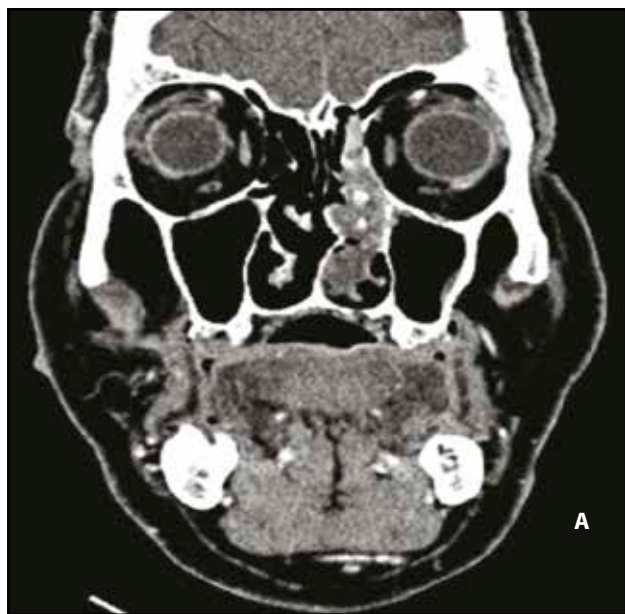


Figure 2 Inverted papilloma – histopathologic images (Hematoxylin and eosin stain, x5).

CLINICAL PRESENTATION

The most common symptom in patients with IP is typically unilateral nasal obstruction, but other symptoms may be present, such as headache, rhinorrhea, hyposmia or epistaxis. Due to its nonspecific presentation which frequently resembles rhinosinusitis or headache, the diagnosis may be delayed for months. In many cases the early lesions of inverted papilloma are accidental findings.

Significant disruptions and modifications of the normal anatomic landmarks in the sinonasal cavities, along with an incompletely resected tumor during previous surgery, may complicate the clinical and imaging evaluations of these patients.



Data in the literature states a period between 6 and 12 months from the symptoms' onset to the cancer transformation and diagnosis^{13,29,30}.

IMAGING MODALITIES AND FINDINGS

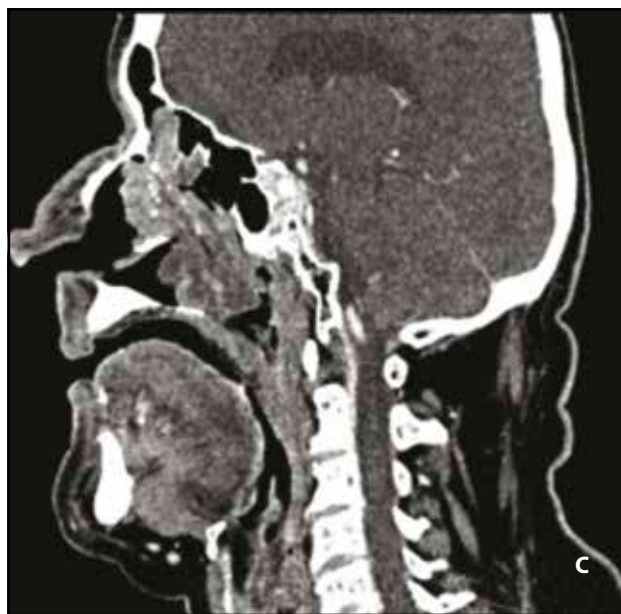In order to determine the tumor location and its extension, a radiological assessment must be performed.

A CT scan is an important imagistic examination when a nasal tumor is identified. Normally, the inverted papilloma is associated with heterogeneous opacification and sclerosis in the adjacent bone, with destruction or erosion areas^{18,31} (Figure 3).

The CT scans demonstrated that focal areas of hyperostosis may correspond to the site of tumor implantation in 90% of cases^{18,32}. The main inconvenience in case of this imaging technique is that a sinonasal inverted papilloma may present features similar to other lobular nasal masses or inflammatory pathology. The tumoral origin may appear as a hyperostosis area on CT scan imaging. This investigation may identify two types of focal aspects: cone-shaped or plaque-like hyperostosis. The plaque-like appearance seems to be more frequent in the case of tumors originating from the lateral walls of the nasal fossae, whilst the cone-shaped hyperostosis is proven to be characteristic of the paranasal sinuses' walls or the bony part of the nasal septum.

Although the findings on the CT scans are nonspecific, the imaging diagnostics method helps in identifying the site of bony attachment to the sinus or the

Figure 3. Craniofacial CT scan (coronal (A), axial (B) and sagittal (C) slices) shows a hyperdense soft tissue lesion in the left nasal cavity with intralésional calcifications representing residual bone fragments from the left middle turbinate which was eroded by the tumor.



lateral nasal wall; this site must be entirely surgically resected to prevent or decrease the risk of recurrence. In some cases, due to CT scan limitations, it may be difficult to clearly identify and differentiate the lesion margins from any adjacent obstructed secretions.

The aspect revealed by the CT images can give valuable information in the preoperative analysis of the bony anatomy surrounding the lesion, especially in those cases presenting with prior surgical procedures in their medical history²⁶.

If a potential mass is suspected on the CT scan, the contrast administration will be reserved for the Magnetic Resonance Imaging (MRI) examination. Contrast-enhanced MRI is superior to CT scan in differentiating a tumoral mass, respectively a papilloma, from inflammation, in identifying the extent of the tumor, the perineural invasion, intracranial involvement or any other potential complications. On the MRI T1-weighted and T2-weighted sequences, the sinonasal inverted papilloma will present as cerebriform circumscriptions^{2,18}.

Many patients are initially tested using CT imaging, although the preferred technique is the MRI due to its specific benefits, such as identifying the characteristic features of sinonasal inverted papillomas, delineating the lesion margins and for differentiating the lesion from mucosal thickening and secretions.

The ability to predict whether an IP has a high potential for malignancy represents one of the most significant challenges in the diagnosis process. Suspicions of associated malignancy should be raised when the CT or MR imaging shows foci of necrosis, areas of osseous destruction and/or disruption of the characteristic IP architecture.

In order to predict the origin, visualize the tumor and distinguish the lesion from other inflammatory diseases, and in addition to the above radiologic methods, surgeons also use the nasal endoscopy and advanced optical instruments^{1,33}. As a result of technological developments, a staging system to evaluate the extensiveness of IPs was proposed by Krouse^{1,34}. Based on this staging system and the identified tumor origin, surgeons can then opt for the appropriate surgical procedure which can be represented by endoscopic, external or combined approach.

PATIENT MANAGEMENT

The preferred approach for sinonasal inverted papilloma therapy is the complete surgical tumor excision. The attachment site and the location of the lesion will determine the surgical approach³⁵.

A pedicle-oriented surgery with clear mucosal margins has been recently preferred as the adequate approach³⁶⁻³⁹. Even in advanced stages, most cases of inverted papillomas have a relatively small area of origin. This specific trait has led to the implementation of the attachment-oriented surgery technique. The attachment-oriented surgery technique requires the identification of the tumor attachment, subperiosteal resection and drilling of the underlying bone at the papilloma origin. The meticulous use of subperiosteal dissection in the involved areas is advocated by Tomenzoli et al., as a mean to improve the recurrence rates³⁹.

The recurrence rate of IP is a characteristic that can be influenced and modified depending on the surgi-

Table 1
Inverted papilloma characteristics in the patients' group.

Type of tumor	No. of cases	Extent			Type of resection		Follow-up	Recurrence
		N*	NS-1**	NS-X***	„en-bloc“	Piece-meal		
Inverted papilloma	52	6	29	17	11	41	9-30 mo (mean 18.7 mo)	8 (15,38%)

Legend: *N- Extent limited to NF; **NS-1 Extent to NF and 1 sinus; ***NS-X Extent to NF and more than 1 sinus.

cal technique. Endoscopic visualization allows a clear and exact view of the tumor and is shown to lower the recurrence rate of the inverted papillomas.

When the tumor is large and is extending to the paranasal sinuses, a wide surgical field is required by lateral rhinotomy, medial maxillectomy or midfacial degloving approach^{38,40,41}. In addition to extensive surgical resection, adjuvant therapies including radiation and chemotherapy may be required in patients with IP-SCC.

A transnasal endoscopic medial maxillectomy (TEMM) may be used to resect benign and malignant tumors of the medial wall of the maxilla and extensive inverted papilloma affecting the lateral nasal wall and involving the maxillary sinus. This technique presents several advantages such as: low risk of infraorbital nerve damage, preservation of important structures (lamina papyracea, anterior maxillary wall), good exposure of the ethmoid and maxillary sinus, no facial scars, and no loss of bony support. The endoscopic approach does present limitations such as: accessing the anterior and lateral wall of the maxillary sinus, and in any instances of massive frontal sinus involvement, intracranial extension and involvement of the orbit. The excision control rates provided by the endoscopic technique for IP treatment seem comparable with traditional open surgery techniques^{18,42}.

Along with the surgical technique, the follow-up is important in inverted papilloma treatment. There is no specific follow-up period recommended, but a minimum 3 to 5 years seems to be proper⁴³⁻⁴⁵. Most authors recommend clinical examination and nasal endoscopy every 3 or 4 months in the first postoperative year, every 6 months in the second year and then every 12 months^{46,47}.

OUR EXPERIENCE

We performed a clinical study on 52 patients, diagnosed with inverted papilloma, who underwent surgical treatment in our department. The study was conducted between January 2015 and May 2018. The follow-up period was between 9 and 30 months, with an average period of 18.7 months.

The preoperative assessment consisted in clinical examination, nasal endoscopy and CT or MR imaging. According to Krouse classification, we encountered 6 patients with tumor limited to the nasal fossa (stage I), 29 patients with tumor involving the nasal fossa and extension to one sinus (stage II); 17 patients with nasal fossa involvement and affecting more than one paranasal sinus (stage III) (Table 1).

All the patients included in our study group patients were surgically treated. In 41 patients we used endoscopic surgical approach and in 11 cases we performed external or combined surgical approach (Figure 4).

Regarding the type of resection, most frequently we used the “piece-meal” technique, due to the tumoral volume and surgical limitations (Table 1). In 11 patients, the “en-bloc” technique was preferred, especially in small tumors.

Postoperatively, the surgical pieces were harvested and sent to histopathological examination in the anatomo-pathology department from our hospital. We also performed genotyping for Human Papilloma Virus (HPV) for all the patients included in our study group. We encountered the presence of HPV infection in 15 patients, out of which 9 patients were males and 6 females. Most of the cases were HPV negative (53%) (Figure 5). Among the group with HPV involvement, the histopathological types were: inverted papilloma (8 patients), exophytic papilloma (6 patients) and cylindrical cell papilloma (one patient).

The most frequent HPV genotype was type 6 (34%),

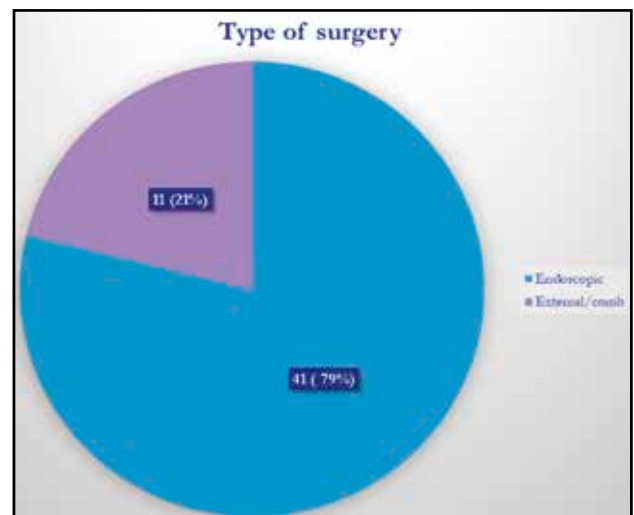


Figure 4. Types of surgery used in our group of patients.

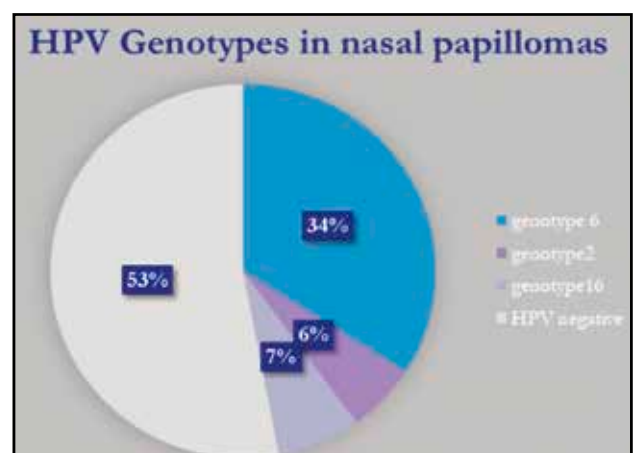


Figure 5. HPV genotypes of inverted papilloma in our study group.

mainly in exophytic papillomas (Figure 5). We also noticed a case of a patient with inverted papilloma and coexistence of HPV type 16, who presented areas of squamous cell carcinoma on the surgical tumoral mass.

CONCLUSIONS

The sinonasal inverted papilloma represents a challenging disease for many otolaryngologists. The recurrence tendency and malignant risks of inverted papillomas are the subject of debates and open questions in the field of otolaryngology. The role of HPV as an etiological factor for IP occurrence or for its progression to squamous cell carcinoma has not been supported by recent studies.

The overall accepted and most widely used approach for most IP is the endonasal endoscopic technique, as it facilitates complete tumor removal and allows for adequate safe margins in the majority of cases, as well as the flexibility to be modified according to the imaging findings and any potential intraoperative findings. Complete removal of the tumor during the initial surgery, as well as a comprehensive follow-up, have been proven to constitute the best preventative measure for IP recurrence.

Conflict of interest: The authors declare that there is no conflict of interest.

Contribution of authors: All authors have equally contributed to this work.

REFERENCES

- Kim JS, Kwon SH. Recurrence of sinonasal inverted papilloma following surgical approach: a metaanalysis. *Laryngoscope*. 2017;127(1):52-8. DOI: 10.1002/lary.26222. Epub 2016 Aug 17.
- Jeon TY, Kim HJ, Chung SK, Dhong HJ, Kim HY, Yim YJ, et al. Sinonasal inverted papilloma: value of convoluted cerebriform pattern on MR imaging. *AJNR Am J Neuroradiol*. 2008;29(8):1556-60. DOI: 10.3174/ajnr.A1128. Epub 2008 May 22.
- Suh KW, Facer GW, Devine KD, Weiland LH, Zujko RD. Inverting papilloma of the nose and paranasal sinuses. *Laryngoscope*. 1977;87:35-46. DOI: 10.1288/00005537-197701000-00005.
- Lesperance MM, Esclamado RM. Squamous cell carcinoma arising in inverted papilloma. *Laryngoscope*. 1995;105(2):178-83.
- McCullister KB, Hopper BD, Ginsberg LE, Michel MA. Inverted Papilloma: A Review and What's New. American Society of Head and Neck Radiology (ASHNR) 47th Annual Meeting, September 25-29, 2013, Milwaukee, Wisconsin.
- Wood JW, Casiano RR. Inverted papillomas and benign nonneoplastic lesions of the nasal cavity. *Am J Rhinol Allergy*. 2012;26(2):157-63. DOI: 10.2500/ajra.2012.26.3732.
- Strojan P, Jereb S, Borsos I, But-Hadzic J, Zidar N. Radiotherapy for inverted papilloma: a case report and review of the literature. *Radiol Oncol*. 2013;47(1):71-6. DOI: 10.2478/v10019-012-0045-8.
- Bathma S, Harvinder S, Philip R, Rosalind S, Gurdeep S. Endoscopic management of sinonasal inverted papilloma. *Med J Malaysia*. 2011;66(1):15-8.
- Grayson JW, Khichi SS, Cho DY, Riley KO, Woodworth BA. Management strategies for skull base inverted papilloma. *Otolaryngology-Head and Neck Surgery*. 2016;155(1):179-83. DOI: 10.1177/0194599816639019.
- Lisan Q, Laccourreye O, Bonfils P. Sinonasal inverted papilloma: From diagnosis to treatment. *Eur Ann Otorhinolaryngol Head Neck Dis*. 2016;133(5):337-41. DOI: 10.1016/j.anorl.2016.03.006. Epub 2016 Apr 1.
- Buchwald C, Franzmann MB, Tos M. Sinonasal papillomas: a report of 82 cases in Copenhagen County, including a longitudinal epidemiological and clinical study. *Laryngoscope*. 1995;105(1):72-9.
- Vrabec DP. The inverted Schneiderian papilloma: a 25-years study. *Laryngoscope*. 1994;104(5):582-605. DOI: 10.1002/lary.5541040513.
- Wassef SN, Batra PS, Barnett S. Skull base inverted papilloma: a comprehensive review. *ISRN Surg*. 2012;2012:175903. DOI: 10.5402/2012/175903.
- Shen J, Baik F, Mafee MF, Peterson M, Nguyen QT. Inverting papilloma of the temporal bone. *Otol Neurotol*. 2011;32(7):1124-33. DOI: 10.1097/MAO.0b013e31822a2b16.
- Acevedo-Henao CM, Talagas M, Marianowski R, Pradier O. Recurrent inverted papilloma with intracranial and temporal fossa involvement: a case report and review of the literature. *Cancer Radiother*. 2010;14(3):202-5. DOI: 10.1016/j.canrad.2010.01.012. Epub 2010 Apr 24.
- Coca-Pelaz A, Gomez-Martinez J, Vivanco-Allende B, Hermsen M, Llorente JL. Primary inverted papilloma of the middle ear with intracranial invasion. *Head Neck*. 2016;38(5):E105-7. DOI: 10.1002/hed.24329. Epub 2015 Dec 24.
- Bayindir E, Hanege FM, Kalcioğlu MT, Zenginkinet T, Celik S. A Case of inverted papilloma originating from the middle ear and review of the literature. *Case Reports in Otolaryngology*. 2019;2019:3041570. DOI: 10.1155/2019/3041570.
- Coutinho G, Marques J, Leal M, Spratley J, Fernandes MS, Santos M. Surgical outcomes of sinonasal inverted papilloma: a 17 year review. *Braz J Otorhinolaryngol*. 2019. DOI: 10.1016/j.bjorl.2018.12.011.
- Wang MJ, Noel JE. Etiology of sinonasal inverted papilloma: a narrative review. *World J Otorhinolaryngol Head Neck Surg*. 2016;3(1):54-8. DOI: 10.1016/j.wjorl.2016.11.004. eCollection 2017 Mar.
- Kashima HK, Kessis T, Hruban RH, Wu TC, Zinreich SJ, Shah KV. Human papillomavirus in sinonasal papillomas and squamous cell carcinoma. *Laryngoscope*. 1992;102(9):973-6.
- McLachlin CM, Kandel RA, Colgan TJ, Swanson DB, Witterick JJ, Ngan BY. Prevalence of human papillomavirus in sinonasal papillomas: a study using polymerase chain reaction and in situ hybridization. *Mod Pathol*. 1992;5(4):406-9.
- McKay SP, Grégoire L, Lonardo F, Reidy P, Mathog RH, Lancaster WD. Human papillomavirus (HPV) transcripts in malignant inverted papilloma are from integrated HPV DNA. *Laryngoscope*. 2005;115(8):1428-31.
- Kraft M, Simmen D, Casas R, Pfaltz M. Significance of human papillomavirus in sinonasal papillomas. *J Laryngol Otol*. 2001;115(9):709-14.
- Jenko K, Kocjan B, Zidar N, Poljak M, Strojan P, Zargi M, et al. Inverted papillomas HPV more likely represents incidental colonization than an etiological factor. *Virchows Arch*. 2011;459(5):529-38. DOI: 10.1007/s00428-011-1139-1. Epub 2011 Sep 9.
- Mohajeri S, Lai C, Purgina B, Almutairi D, Baghai T, Dimitroulakos J, et al. Human papillomavirus: an unlikely etiologic factor in sinonasal inverted papilloma. *Laryngoscope*. 2018;128(11):2443-7. DOI:

- 10.1002/lary.27207. Epub 2018 Apr 18.
26. Eggers G, Mühling J, Hassfeld S. Inverted papilloma of paranasal sinuses. *J Craniomaxillofac Surg.* 2007;35(1):21–9. Epub 2007 Jan 30.
 27. Hyams VJ. Papillomas of the nasal cavity and paranasal sinuses. A clinicopathological study of 315 cases. *Ann Otol Rhinol Laryngol.* 1971;80(2):192–206.
 28. Batsakis JG, Suarez P. Schneiderian papillomas and carcinomas: a review. *Adv Anat Pathol.* 2001;8(2):53–64.
 29. Jackson RT, Fitz-Hugh GS, Constable WC. Malignant neoplasms of the nasal cavities and paranasal sinuses: (a retrospective study). *Laryngoscope.* 1977;87(5 Pt 1):726–36.
 30. Ketcham AS, Van Buren JM. Tumors of the paranasal sinuses: a therapeutic challenge. *Am J Surg.* 1985;150(4):406–13.
 31. Lund VJ. Optimum management of inverted papilloma. *J Laryngol Otol.* 2000;114(3):194–7.
 32. Dammann F, Pereira P, Laniado M, Plinkert P, Lowenheim H, Claussen CD. Inverted papilloma of the nasal cavity and the paranasal sinuses: using CT from primary diagnosis and follow-up. *AJR Am J Roentgenol.* 1999;172(2):543–8.
 33. Stankiewicz JA, Giris SJ. Endoscopic surgical treatment of nasal and paranasal sinus inverted papilloma. *Otolaryngol Head Neck Surg.* 1993;109(6):988–95.
 34. Krouse JH. Development of a staging system for inverted papilloma. *Laryngoscope.* 2000;110(6):965–8.
 35. Lane AP, Bolger WE. Endoscopic management of inverted papilloma. *Curr Opin Otolaryngol Head Neck Surg.* 2006;14(1):14–8.
 36. Tufano RP, Thaler ER, Lanza DC, Goldberg AN, Kennedy DW. Endoscopic management of inverted papilloma. *Am J Rhinol.* 1999;13(6):423–6.
 37. Landsberg R, Cavel O, Segev Y, Khafif A, Fliss DM. Attachment-oriented endoscopic surgical strategy for sinonasal inverted papilloma. *Am J Rhinol* 2008;22(6):629–34. DOI: 10.2500/ajr.2008.22.3243.
 38. Atlmayr B, Derbyshire SG, Kasbekar AV, Swift AC. Management of inverted papilloma: review. *J Laryngol Otol.* 2017;131(4):284–9. doi:10.1017/S0022215117000172.
 39. Tomenzoli D, Castelnovo P, Pagella F, Berlucchi M, Pianta L, Delù G, et al. Different endoscopic surgical strategies in the management of inverted papilloma of the sinonasal tract: experience with 47 patients. *Laryngoscope.* 2004;114(2):193–200.
 40. Mackle T, Chambon G, Garrel R, Meieff M, Crampette L. Endoscopic treatment of sinonasal papilloma: a 12 year review. *Acta Otolaryngol.* 2008;128(6):670–4. DOI: 10.1080/00016480701649564.
 41. Waitz G, Wigand ME. Results of endoscopic sinus surgery for the treatment of inverted papillomas. *Laryngoscope.* 1992;102(8):917–22.
 42. Lawson W, Kaufman MR, Biller HF. Treatment outcomes in the management of inverted papilloma: an analysis of 160 cases. *Laryngoscope.* 2003;113(9):1548–56.
 43. Lund VJ, Stammberger H, Nicolai P, Castelnovo P, Beal T, Beham A, et al. European position paper on endoscopic management of tumours of the nose, paranasal sinuses and skull base. *Rhinol Suppl.* 2010;22:1–143.
 44. Carta F, Blancal JP, Verillaud B, Tran H, Sauvaget E, Kania R, Herman P. Surgical management of inverted papilloma: approaching a new standard for surgery. *Head Neck.* 2013;35(10):1415–20. DOI: 10.1002/hed.23159. Epub 2012 Sep 24.
 45. Lombardi D, Tomenzoli D, Buttà L, Bizzoni A, Farina D, Sberze F, et al. Limitations and complications of endoscopic surgery for treatment of sinonasal inverted papilloma: a reassessment after 212 cases. *Head Neck.* 2011;33(8):1154–61. DOI: 10.1002/hed.21589. Epub 2010 Oct 21.
 46. Minovi A, Kollert M, Draf W, Bockmühl U. Inverted papilloma: feasibility of endonasal surgery and long-term results of 87 cases. *Rhinology.* 2006;44(3):205–10.
 47. Woodworth BA, Bhargava GA, Palmer JN, Chiu AG, Cohen NA, Lanza DC, et al. Clinical outcomes of endoscopic and endoscopic-assisted resection of inverted papillomas: a 15-year experience. *Am J Rhinol.* 2007;21(5):591–600.

