

LITERATURE REVIEW

Nasal swell body: a literature review

Elena Patrascu^{1,2}, Vlad Budu^{1,3}, Gabriela Musat^{1,2}

¹“Carol Davila” University of Medicine and Pharmacy Bucharest, Romania

²ENT&HNS Department, “Sfanta Maria” Clinical Hospital, Bucharest, Romania

³“Prof. Dr. D. Hociota” Institute of Phono-Audiology and Functional Surgery, Bucharest, Romania

ABSTRACT

The nasal swell body (NSB) is considered to be an enlarged region of the nasal septum, which is located superiorly to the inferior nasal turbinate and anteriorly to the middle nasal turbinate, with a potential effect upon the airflow nasal valve. The histological studies of the NSB demonstrated that it is a glandular formation, not a venous structure, and it is formed by septal cartilage and bone, as well as a thick mucosa. Recent studies emphasized the functional role of the nasal swell body and it is thought to interfere with the nasal airflow and air humidification, due to its proximity to the internal nasal valve and its histological characteristics (venous sinusoids and seromucinous glands). The nasal swell body is strongly related to the presence of rhinosinusual chronic inflammations (allergic rhinitis and chronic rhinosinusitis) and the septal deviation. In case of the presence of the nasal swell body, surgical treatment is not commonly done, due to the absence of a consensus between the ENT practitioners. Most of them consider surgery as being too aggressive because of the presence of seromucinous glands, with slight impact upon the nasal obstruction. Most probably, the lack of consensus is determined by inconsistent anatomical and histological study results.

KEYWORDS: nasal swell body, deviated nasal septum, rhinosinusual chronic inflammation.

INTRODUCTION

Rhinosinusual abnormalities, such as deviated nasal septum, are relatively common. They may determine nasal obstruction and, often, recurrent diseases after sinus surgeries. Taking into consideration the normal anatomy of the nasal septum, the septal deviation may be bony or cartilaginous, but sometimes there is a mucosal swelling, space occupying¹.

The nasal swell body (NSB) is considered to be an enlarged region of the nasal septum, which is located superiorly to the inferior nasal turbinate and anteriorly to the middle nasal turbinate, with a potential effect upon the airflow nasal valve. This mucosal-lined structure, comprised of septal cartilage and bone, with a thick mucosa, can be identified on clinical examination (anterior rhinoscopy), nasal endoscopy and rhinosinusual imaging techniques. In the literature, there is insufficient data related to the swell body structure and functions and it is frequently confused with a high septal deviation^{2,3}.

In the literature, the nasal swell body was first described by Morgagni, in the year 1662, as a “mucosal protuberance located anteriorly on the septum”, while Schiefferdecker referred to it as a vascular network situated on the anterior part of the nasal septum, the “septal turbinate”⁴.

The following studies have described this entity, with multiple different names, such as septal turbinates, intumescencia septi nasi anterior or Kiesselbach’s body⁴. In the past years, the researchers and the clinicians continued the studies upon the role of the nasal swell body on the nasal respiration, taking into consideration histological and radiological findings.

A study performed by Costa et al.² evaluated the NSB from the anatomical, radiographic and histologic point of view, trying to identify its role in the pathophysiology of nasal airflow. They analysed the imaging (cranio-cerebral MRI) in adult patients with non-rhinosinusual complaints, and they measured the dimensions of the nasal swell

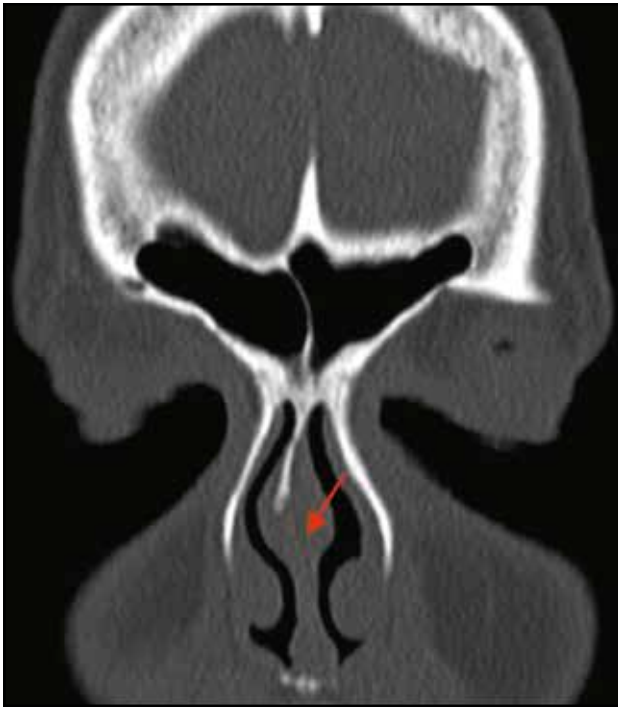


Figure 1. Cranio-facial CT scan, coronal section – Bilateral nasal swell body, with greater size on the left side (opposite to the right high septal deviation).

body, as well as the distance to other nasal structures. After analysing the data, they found that the NSB is an entity of 2/3 cm, situated anteriorly to the middle turbinate and 2.5 cm superior to the nasal floor. Being close to the internal nasal valve region and its structure comprised of venous sinusoids, the authors of the study hypothesized that NSB could play a role in the regulation of the nasal airflow. There are some authors who consider that this structure is similar to the inferior nasal turbinate, in terms of vasoreactivity and role in limiting the nasal airflow by vasodilatation.

ANATOMY

The nasal internal valve is thought to be formed by the septal turbinate and the head of the inferior nasal turbinate, because they determine the resistance necessary to perform inspiration².

Several studies were performed in order to determine the anatomy of the nasal swell body. For example, in one study based on the MRI investigation in 54 adult patients, it has been demonstrated that the NSB is fusiform-shaped, located anterior to the nasal middle turbinate, with mean dimensions of 12.4 mm (width), 19.6 mm (height) and 28.4 mm (length), whilst the distance to the nasal floor was 24.8 mm⁴.

The results of this study were confirmed by another analysis of 118 ostiomeatal complexes on rhinosinusal CT scans, which indicated that the nasal swell body has mean dimensions of 11/18/25 mm, and similar to the inferior nasal turbinate, has a greater size contralateral to the septal deviation (Figure 1). Magnetic resonance imaging studies of the nasal fossae have demonstrated a reduction in the anterior nasal septum dimensions after local decongestion⁵.

HISTOLOGY OF THE NASAL SWELL BODY

In the literature, there is limited information about the nasal swell body, and the main data is focused on the histology and morphology. The septal body was described as a dynamic part of the septum, able to modulate the nasal airflow, because of the vasoactive properties and proximity to the nasal internal valve^{3,6}.

The histological studies of the NSB demonstrated that it is a glandular formation, not a venous structure, and it is formed by septal cartilage and bone, as well as a thick mucosa. It is thought that this formation is more represented in patients with chronic rhinosinusal inflammation.

In one study performed by Yiğit et al.⁷, the authors investigated the dimensions and the histology in 25 allergic patients and in 25 non-allergic patients, who underwent septoplasty and bilateral inferior nasal turbinate reduction. The authors did not observe a difference in the histopathology of the allergic and non-allergic patients, but they noticed that NSB is thicker in patients with allergy. The histology examinations revealed that the nasal swell body is formed from glandular and venous elements, being the thicker structure of the nasal septum, which means that this structure may be involved in nasal obstruction (Figure 2).

Nasal swell bodies have similar histology with the inferior nasal turbinate, and they can undergo the same mucosal changes in case of chronic inflammation (allergic rhinitis, chronic rhinosinusitis), with implications on the nasal obstruction. The duration of the rhinosinusal inflammation stimulates local fibrosis, determining a lower response of the mucosa to topical corticosteroids or nasal decongestants⁸.

Another clinical study performed on adult patients undergoing septoplasty investigated the histology of the nasal swell body, the inferior turbinate and the inferior part of the nasal septum.

The photomicrography, along with morphometric analysis of the biopsy samples, proved that NSB has plenty seromucinous glands (approximately 50%), compared to the inferior turbinate (20%).

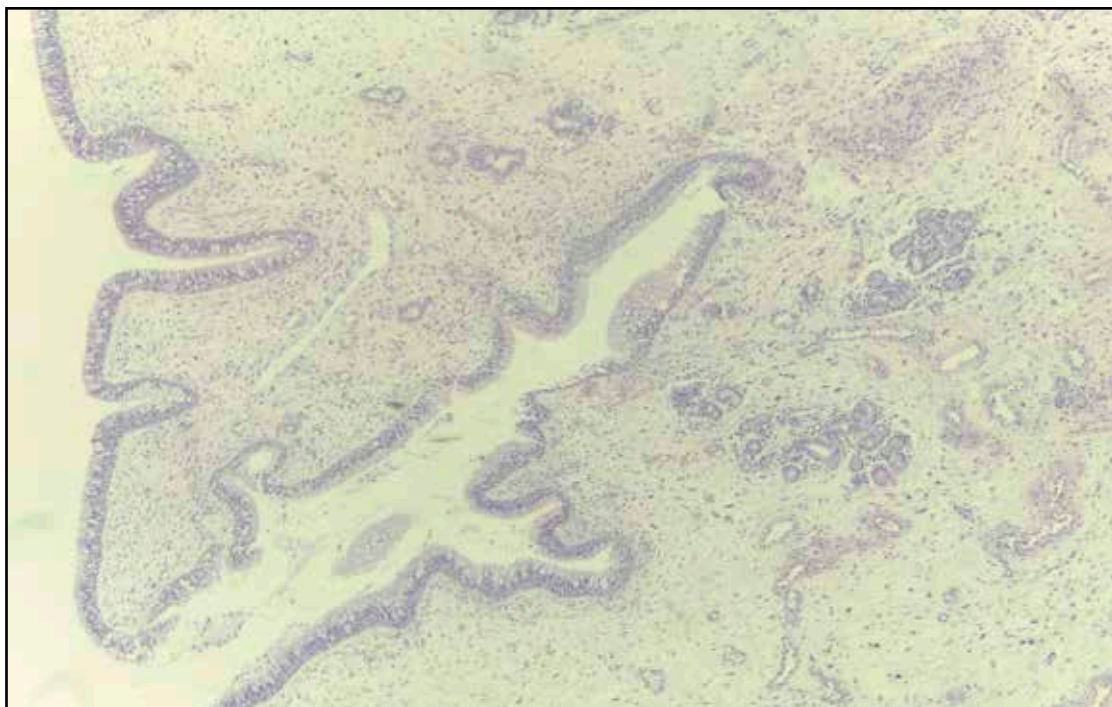


Figure 2. Biopsy sample nasal swell body – respiratory epithelium, seromucinous glands and venous elements (Haematoxylin Eosin staining, 4x).

The mucosa of the inferior turbinates has an increased percentage of venous sinusoids (30%), when compared to the nasal swell body (10%). The proportion of vascular and glandular elements is similar in the inferior septal mucosa and in NSB⁹.

IMPLICATIONS ON RHINOSINUSAL PATHOLOGY

Abnormalities of the nasal septum, such as septal deviation, tumours or mucoceles, may determine both functional and anatomical modifications, in terms of nasal obstruction, predisposition to chronic rhinosinusitis. Recent studies emphasized the functional role of the nasal swell body and it is thought to interfere with the nasal airflow and air humidification, due to its proximity to the internal nasal valve and its histological characteristics (venous sinusoids and seromucinous glands). NSB is strongly related to the presence of rhinosinusal chronic inflammations (allergic rhinitis and chronic rhinosinusitis) and the septal deviation⁵.

A study made by Setlur and Goyal³ on one hundred patients investigated the relationship between the size of the nasal swell body and septal deviation, using cranio-facial CT scans. They demonstrated an important relation between the septal deviation and the contralateral NSB hypertrophy. Consequently, the authors considered the nasal

swell body as septal turbinate, able to influence the nasal airflow and subsequent nasal obstruction, similar to the inferior turbinate (Figure 3).

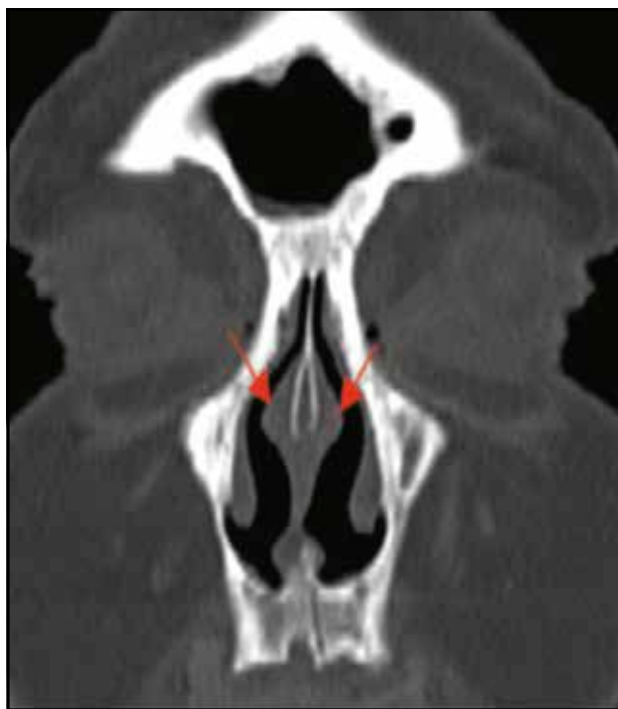


Figure 3. Cranio-facial CT scan, coronal section – bilateral aspect of the nasal swell body.

Arslan and colleagues⁵ investigated the prevalence of NSB, by analysing 595 cranio-facial CT scans of patients with symptoms of chronic rhinosinusitis⁹. They pre-established a standard dimension of at least 8 mm as normal and they noticed the presence of this structure in 56% of the patients, bilateral in the majority of the cases (94%). NSB was a common finding, more prevalent in male patients, aged between 8 to 20 years.

The results are not consistent in all studies. For examples, in one study performed on 40 patients with allergic rhinitis and 30 healthy patients, the authors did not observe any difference between the two study groups¹. The dimensions of the NSB tend to diminish with age, as well as the entire nasal mucosa¹⁰.

The reverse effect on the nasal mucosa is noticed in patients with chronic nasal inflammation, due to the mucosal remodelling, in terms of the thickening of the membrane, increased deposition of the extracellular matrix and hyperplasia of the goblet cells, in direct relationship with the disease duration^{11,12}.

TREATMENT OF THE NASAL SWELL BODY

Nasal obstruction has various methods of treatment, related to the etiology. For example, in case of nasal turbinate hypertrophy or septal deviation, surgical approach is considered the mainstay treatment^{1,13}.

In case of the presence of the nasal swell body, surgical treatment is not commonly done, due to the absence of a consensus between the ENT practitioners. Most of them consider surgery as being too aggressive, because of the presence of seromucinous glands, with slight impact upon the nasal obstruction^{2,14}. Most probably, the lack of consensus is determined by inconsistent anatomical and histological study results.

In the literature, there are few articles and studies related to the surgical approach of the NSB. One clinical study reported that the cryotherapy and nasal cautery of the inferior turbinate and of the nasal swell body in patients with nasal obstruction determined inflammatory disease^{15,16}. The analysis of the patient's symptomatology before and after treatment demonstrated the lack of efficiency of the surgical techniques described^{11,17}.

Thus, combined septoplasty, turbinoplasty and septal body reduction are more efficient than turbinoplasty alone in patients with both deviated nasal septum and chronic hypertrophic rhinitis¹⁸. The removal of the cartilage in the area of the swell body may interfere with the local innervation, by preventing the parasympathetic tone to promote vasodilation.

A recent study used reduction of the septal body with radiofrequency or the submucosal remover with the microdebrider, in the treatment of persistent nasal obstruction. The results seem promising, from the subjective and objective (acoustic rhinometry) points of view, but the long-term effects have not been determined yet^{16,19}.

CONCLUSIONS

The nasal swell body is a normal septal structure, situated anteriorly to the middle turbinate, superiorly to the inferior turbinate, at about 2.5 cm superiorly to the nasal floor. This structure is proved to be more common in the case of patients with chronic rhinosinusitis and allergic rhinitis; it is linked to the septal deviation. The proximity of the nasal swell body to the internal nasal valve, the histology with venous sinusoids plead for a role in the regulation of the nasal airflow, but the exact pathophysiological role and effect on the nasal obstruction remain to be determined by further studies. It is important for the clinicians to be aware of the existence of this structure and not to mistake it for a high septal deviation, which could be inefficiently surgically treated. In the literature, there are several therapeutic methods described for NSB, but currently there is no standard consensus regarding the type of surgery indicated. In the current practice, it is essential to establish an individualized therapeutic plan, based on the symptoms, clinical and radiologic findings.

Conflict of interests: The authors report no conflicts of interest.

Contribution of authors: All authors have equally contributed to this work.

REFERENCES

1. Gelera JE, Ojar D, Lim JH, Wee JH, Kim JW, Rhee CS. Radiographic changes of the nasal septal body among patients with sinonasal diseases. *Clin Exp Otorhinolaryngol*. 2017;10(4):338-43. DOI: 10.21053/ceo.2017.00080.
2. Costa DJ, Sanford T, Janney C, Cooper M, Sindwani R. Radiographic and anatomic characterization of the nasal septal swell body. *Arch Otolaryngol Head Neck Surg*. 2010;136(11):1107-10. DOI: 10.1001/archoto.2010.201.
3. Setlur J, Goyal P. Relationship between septal body size and septal deviation. *Am J Rhinol Allergy*. 2011;25(6):397-400. DOI: 10.2500/ajra.2011.25.3671.
4. Wexler D, Braverman I, Amar M. Histology of the nasal septal swell body (septal turbinate). *Otolaryngol Head Neck Surg*. 2006;134(4):596-600.
5. Koo SK, Jung SH, Moon JS, Son H. A case of nasal swell body (septal

- turbinate) combined with pneumatization of perpendicular plate of the ethmoid bone. *J Rhinol.* 2016;23(1):70-3. DOI: 10.18787/jr.2016.23.1.70.
6. Elwany S, Salam SA, Soliman A, Medanni A, Talaat E. The septal body revisited. *J Laryngol Otol.* 2009;123(3):303-8. DOI: 10.1017/S0022215108003526. Epub 2008 Sep 17.
 7. Yigit O, Taskin U, Acioğlu E, Sisman S, Huq GE. Histological evaluation of the nasal swell body in allergic patients. *Turk Arch Otolaryngol.* 2013;51:41-4.
 8. Wexler DB, Davidson TM. The nasal valve: a review of the anatomy, imaging, and physiology. *Am J Rhinol.* 2004;18(3):143-50.
 9. Arslan M, Muderris T, Muderris S. Radiological study of the intumescencia septi nasi anterior. *J Laryngol Otol.* 2004;118(3):199-201.
 10. Rehl RM, Balla AA, Cabay RJ, Hearp ML, Pytynia KB, Joe SA. Mucosal remodeling in chronic rhinosinusitis. *Am J Rhinol.* 2007;21(6):651-7. DOI: 10.2500/ajr.2007.21.3096.
 11. Haight JS, Gardiner GW. Nasal cryosurgery and cautery: should the septum be treated and is a diagnosis relevant? *J Otolaryngol.* 1989;18(4):144-50.
 12. Farmer SE, Eccles R. Understanding submucosal electrosurgery for the treatment of nasal turbinate enlargement. *J Laryngol Otol.* 2007;121(7):615-22.
 13. Kim SJ, Kim HT, Park YH, Kim JY, Bae JH. Coblation nasal septal swell body reduction for treatment of nasal obstruction: a preliminary report. *Eur Arch Otorhinolaryngol.* 2016;273(9):2575-8. DOI: 10.1007/s00405-016-3946-0. Epub 2016 Feb 24.
 14. Farmer SE, Quine SM, Eccles R. Efficacy of inferior turbinate coblation for treatment of nasal obstruction. *J Laryngol Otol.* 2009;123(3):309-14. DOI: 10.1017/S0022215108002818.
 15. Lee HP, Poh HJ, Chong FH, Wang de Y. Changes of airflow pattern in inferior turbinate hypertrophy: a computational fluid dynamics model. *Am J Rhinol Allergy.* 2009;23(2):153-8. DOI: 10.2500/ajra.2009.23.3287.
 16. Sapci T, Usta C, Evcimik MF, Bozkurt Z, Aygun E, Karavus A, et al. Evaluation of radiofrequency thermal ablation results in inferior turbinate hypertrophies by magnetic resonance imaging. *Laryngoscope.* 2007;117(4):623-7.
 17. Wotman M, Kacker A. Should otolaryngologists pay more attention to nasal swell bodies? *Laryngoscope.* 2015;125(8):1759-60. DOI: 10.1002/lary.25144.
 18. Yu MS, Kim JY, Kim BH, Kang SH, Lim DJ. Feasibility of septal body volume reduction for patients with nasal obstruction. *Laryngoscope.* 2015;125(7):1523-8. DOI: 10.1002/lary.25154.
 19. Catalano P, Ashmead MG, Carlson D. Radiofrequency ablation of septal swell body. *Ann Otolaryngol Rhinol.* 2015;2(11):1069.

