

ORIGINAL STUDY

CT scan evaluation of the distance between maxillary sinus floor and maxillary teeth apices

Daniel Lupoi^{1,2}, Mihai Dragomir¹, Gabriela Coadă¹, Alexandra Sanda¹, Vlad Budu^{2,3}

¹ENT&HNS Department, “Sfanta Maria” Hospital, Bucharest, Romania

²“Carol Davila” University of Medicine and Pharmacy, Bucharest, Romania

³“Prof. Dr. D. Hociota” Institute of Phono-Audiology and Functional ENT Surgery, Bucharest, Romania

ABSTRACT

BACKGROUND. The relationship between the maxillary sinus floor and the roots of the teeth in the upper arch is essential, especially in the correct diagnosis and treatment of odontogenic maxillary sinusitis. The aim of this study was to determine exactly this distance and to observe the most common teeth situated closely to the maxillary sinus.

MATERIAL AND METHODS. The study was performed in 2020, in the ENT Department of “Sfanta Maria” Hospital, and was made based on computed tomography (CT) scans of the sinuses from the clinic's archive. The image analysis was performed with a radiologic software. For each tooth, from both right and left upper hemiarcade, the distance between the dental root and the bony floor of the maxillary sinus was measured and the average distances were compared.

RESULTS. Among the present teeth analysed, those with the closest distance were the 1st M (95.15% on the right side and 96.23% on the left side), then the second molars (96.08% on the right side and 90% on the left side). The 2nd and 3rd PM had a similar percentage of the sinus approach, which varied between 82% and 86%.

CONCLUSION. Knowing these dento-sinusal relationships, there is a win-win situation for both the ENT doctor and the dentist. The paraclinical examination necessary for the analysis of the dento-alveolo-sinusal relation and of the afferent pathology is the imaging one, of choice being the CT and CBCT scans.

KEYWORDS: CT scan, CBCT scan, maxillary sinusitis, dental root.

INTRODUCTION

The relationship between the margins of the root teeth and the maxillary sinus floor is particularly important for both the ENT doctors and the dentists. Dental implantology has developed a lot in the last 30 years and by 2023, it is predicted an implant market value estimated at USD \$13 billion¹. Technological improvements in recent years have contributed exponentially to increasing invasive manoeuvres, including the maxillary dental arcade, often resulting in acute or chronic maxillary sinusitis. What has remained unchanged throughout these permanent improvements is the loco-regional anatomy. Therefore, there are countless anatomical variants of localization of the dental roots, but also, there are variants in the development of the maxillary sinus pneumatization. To minimize the risk of damaging the sinus mucosa or accidental intrasinusal introduction of foreign bodies, we consider useful the analysis of the relationship be-

tween the root of the teeth from the upper dental arch and the maxillary sinus floor.

There are few studies in the literature to evaluate the relationship between dental roots and the floor of the maxillary sinus. The aim of this study was to determine exactly this distance and to observe the most common teeth situated closely to the maxillary sinus. Given that this study was performed in an ENT Department and the patients referred to us for an ENT pathology, we consider that it is not relevant to make a comparison between the distance of dental roots to the maxillary sinus and the intrasinusal inflammatory processes.

MATERIAL AND METHODS

The study was a retrospective one, performed in 2020, in the ENT Department of the “Sfanta Maria” Hospital, on computed tomography (CT) examinations of the si-

Corresponding author: Daniel Lupoi, MD, PhD, ENT&HNS Department, “Sfanta Maria” Hospital, 37-39 Ion Mihalache Blv., District 1, Bucharest, Romania

E-mail: daniel.lupoi@yahoo.com

Received for publication: September 12, 2020 / **Accepted:** October 29, 2020

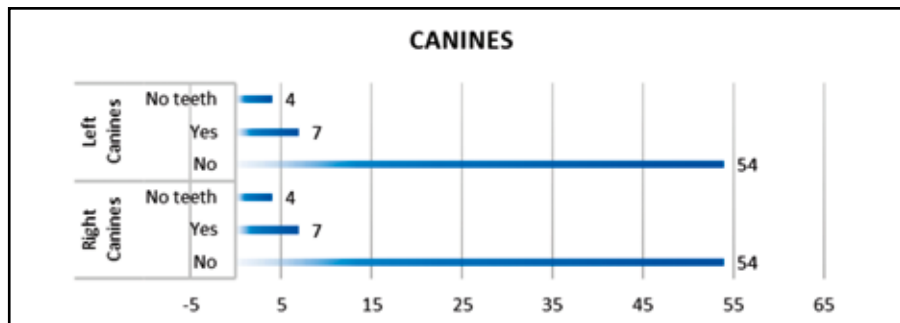


Figure 1. The relation between the root tips of canines and the maxillary sinus floor.

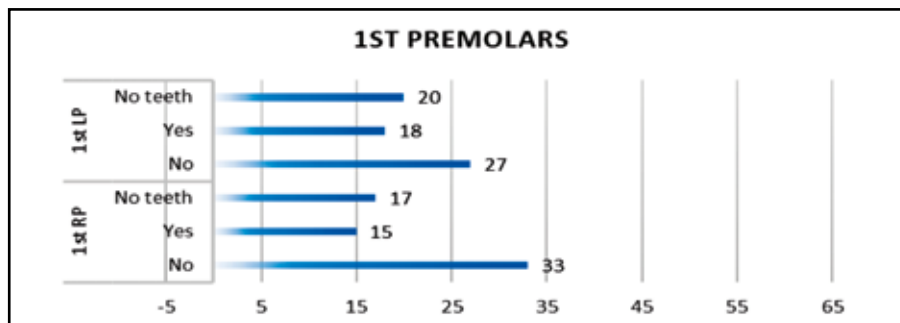


Figure 2. The relation between the root tips of 1st PM and the maxillary sinus floor. (RP – right premolars, LP – left premolars)

nuses from the clinic’s archive. The inclusion criteria were: computed tomography examination of the sinuses to include the teeth on the upper arch, clear coronal and sagittal reconstruction images that allow the precise measurement, adult patients with permanent dentition.

The image analysis was performed with Syngo fast-View® and RadiAnt® medical software programs and the statistical processing was performed with Excel and XLSTAT statistic analysing software. For each tooth, from both the right and left upper hemiarcs, the distance between the dental root and the bony floor of the maxillary sinus was measured and then the average distances were compared. The maximum distance taken into account from the sinus floor was 3 mm, this value being arbitrary.

RESULTS

After applying the inclusion criteria, 65 CT scans were included in the study group. These corresponded to 37 men (56.92%) and 28 (43.08%) women, respectively. The youngest patient was 22 years old, while the oldest was 74 years old. The median age was 45 years, and the standard deviation was 13.705.

The distance between the roots of the first incisors (I) 1 and 2 and the floor of the maxillary sinus was greater than 3 mm, so we cannot say that they had any close relation. Analysing the group, it turned out that 8 canines (C) were absent, 4 on the left side and 4 on the right side. Of those present, 7 from each upper arch were related to the maxillary sinuses (Figure 1) of which 2 had intrasinusal

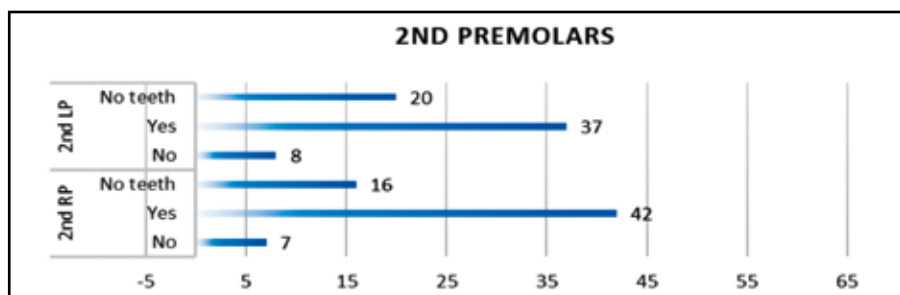


Figure 3. The relation between the root tips of 2nd PM and the maxillary sinus floor. (RP – right premolars, LP – left premolars)

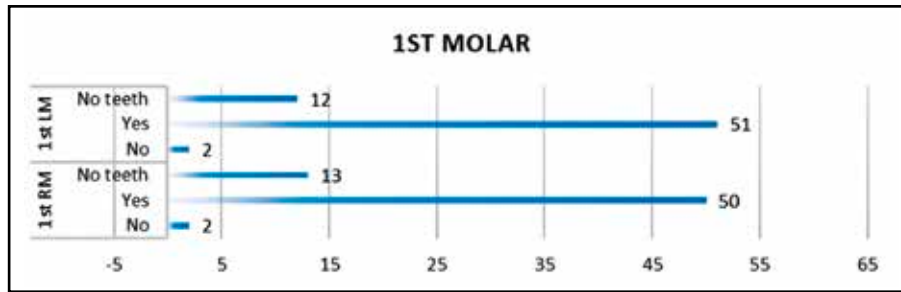


Figure 4. The relation between the root tips of 1st molars and the maxillary sinus floor. (RM – right molars, LM – left molars)

roots on the right side. On the right side, the average distance was 1.85 mm, compared to 1.33 mm on the left side.

Regarding first premolars (1st PM), the situation was as follows (Figure 2): right side - 20 were absent; 18 were close to the sinus floor with an average distance of 1.65 mm, 5 having intrasinusal roots; left side - 17 were absent; 15 were near the sinus floor, the average distance being 1.37 mm, of which 3 teeth had intrasinusal roots. So, the average distance was smaller on the left side.

Analysis of the second premolars (2nd PM) revealed (Figure 3): the right side - 16 missing teeth; 42 teeth within a close distance (an average of 1.5 mm), of which 13 with intrasinusal roots; left side - 20 missing teeth; 37 teeth with an average distance of 1.22 mm to the maxillary floor, 14 of them with intrasinusal roots. Also, we can observe that the average distance was smaller on the left side.

The measurements of the first molars (1st M) were the following (Figure 4): right side - 13 missing teeth; 50 teeth with an average distance of 1.44 mm, of which 23 with intrasinusal roots; left side - 12 missing teeth; 51 teeth with close contact (an average distance of 1.4 mm), 19 of them with intrasinusal roots.

The following data were determined at the second molars (2nd M) (Figure 5): right side - 14 missing teeth; 49 teeth with an average distance of 1.34 mm, 18 with intrasinusal roots; left side - 15 missing teeth; 45 teeth with an average distance of 1.14 mm, 20 with intrasinusal roots.

The analysis of the third molars (3rd M) revealed (Figure 6): the right side - 36 missing teeth; 24 teeth with an average distance of 1.51 mm, 17 with intrasinusal roots; left side - 39 missing teeth; 36 teeth with an average dis-

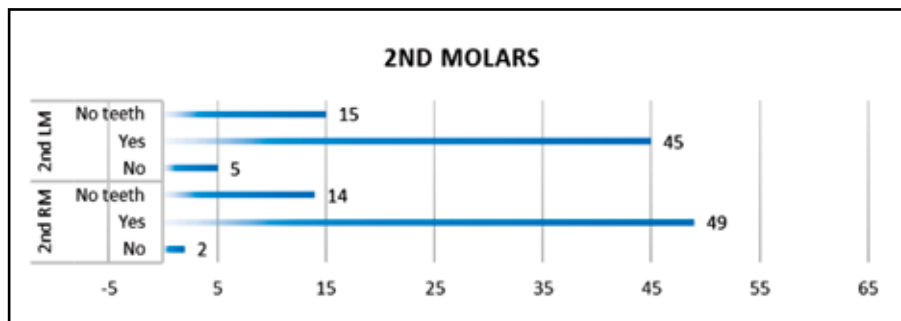


Figure 5. The relation between the root tips of 2nd molars and the maxillary sinus floor. (RM – right molars, LF – left molars)

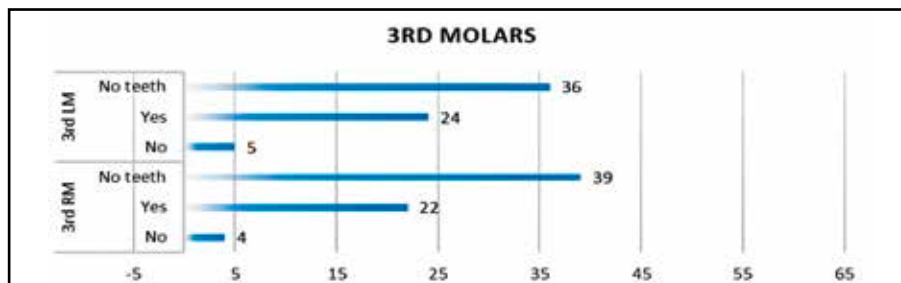


Figure 6. The relation between the root tips of 3rd molars and the maxillary sinus floor. (RM – right molars, LF – left molars)

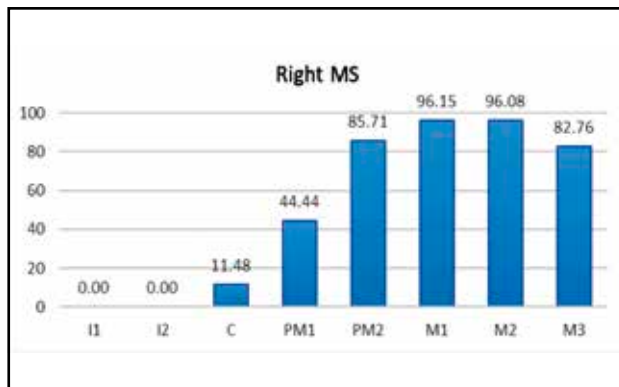


Figure 7. The percentage of each sinus teeth on the right maxillary sinus (MS).

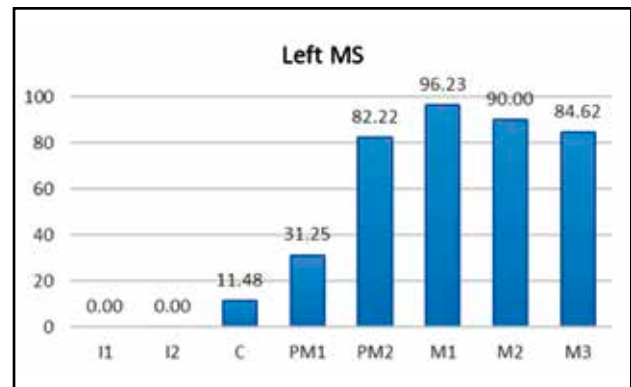


Figure 8. The percentage of each sinus teeth on the left maxillary sinus (MS).

tance of 1.72 mm, 9 with intrasinus roots.

The percentage distribution depending on sinus teeth is as follows (Figure 7 and Figure 8): right side – 1st I = 0%, 2nd I = 0%, C = 11.48%, 1st PM = 44.44%, 2nd PM = 85.71%, 1st M = 96.15%, 2nd M = 96.08%, 3rd M = 82.76%; left side – 1st I = 0%, 2nd I = 0%, C = 11.48%, 1st PM = 31.25%, 2nd PM = 82.22%, 1st M = 96.23%, 2nd M = 90%, 3rd M = 84.62%.

Comparing the same teeth in the upper arch on both sides, there were no statistically significant differences: 1st PM ($p = 0.755$), 2nd PM ($p = 0.572$), 1st Molar ($p = 1.00$), 2nd Molar ($p = 1,000$), 3rd Molar ($p = 0.607$), but it was observed that on the left upper teeth arch, the average distance was smaller than on the right side.

DISCUSSIONS

Knowing the relationship between the maxillary sinus floor and the roots of the teeth in the upper arch is essential, especially in the correct diagnosis and treatment of odontogenic maxillary sinusitis, which represents between 10 and 12% of all cases

of maxillary sinusitis².

The best way to assess the distance between the dental roots and the floor of the maxillary sinus is the computed tomography (CT) examination and, more recently, the cone-beam computed tomography (CBCT) examination. CBCT scan has several advantages, such as lower radiation exposure, rapid examination and higher resolution³. Different software programs allow subsequent computerized analysis of these CT exams⁴.

Several types of relationships of dental roots with the maxillary sinus have been proposed, some as qualitative type and others as quantitative. Kwak et al.⁵ (2004) and Jung et al.⁶ (2009) proposed several types of relationships, among which we mention: type 0 - the maxillary sinus floor is located above the root apex; type 1 - the root apex touches the floor of the maxillary sinus; type 2 - the floor of the maxillary sinus is interposed between roots; type 3 - apical protrusion is observed over the maxillary sinus floor⁷. The maximum distance between the dental root and the sinus floor taken into account in our study was 3 mm (Figure 9), given that, the closer the two anatomical landmarks are, the

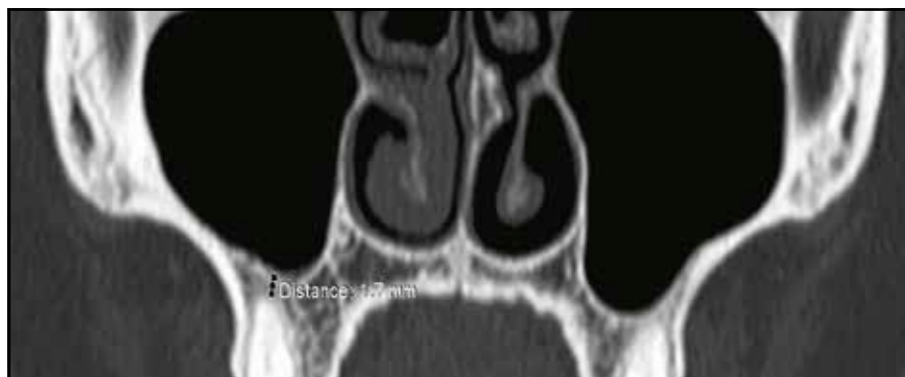

Figure 9. Measurement of the distance between the root apex and maxillary floor (1.7 mm) on a cranio-facial CT scan, axial slice.

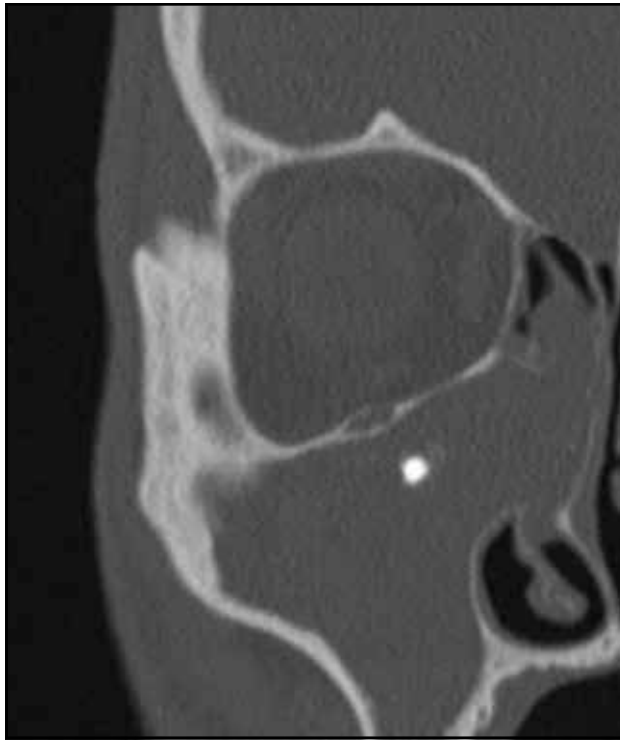


Figure 10. Iatrogenic sinusitis - cranio-facial CT scan (axial slice).

greater the risk of transmitting the dental pathology to the maxillary sinus⁸.

The distance from the floor of the maxillary sinus, in the case of the incisors, was greater than 3 mm in all cases. We can conclude that these are not sinusal teeth. However, in the literature, there are cases of odontogenic sinusitis that had as a starting point the incisors⁹. According to this study, among the present teeth analysed, those with the closest distance were the 1st M (95.15% on the right side and 96.23% on the left side), then the second molars (96.08% on the right side and 90% on the left side). The 2nd and 3rd PM had a similar percentage of the sinusal approach, which varied between 82% and 86%. Our results showed that most of the teeth on the left superior arch were closer to the maxillary sinus floor than the one on the right side, but these differences were not statistically significant ($p > 0.05$). The fact that the first molars are the most common sinusal teeth is confirmed by other studies too⁴.

The above-mentioned data are of great importance, considering the etiology of odontogenic maxillary sinusitis: dental implant and dental extraction complications, periapical infection, foreign bodies, cysts, sinus lift, dental procedures, iatrogenic conditions¹⁰⁻¹³ (Figure 10). In case of unilateral maxillary rhinosinusitis, the ENT doctor must pay attention to the pathology of the sinusal teeth. Eradication of the dental infectious out-

break can lead to the healing of maxillary pathology without the need for any surgical treatment.

The limitation in the design of this study was that no correlations could be made between the relationship of sinusal teeth and maxillary pathology. This was due to the fact that the CT examinations were selected from the ENT Department's own archive and it is assumed that a good part of the patients presented for rhinosinusitis diseases. An ideal study should be performed on a series of CT scans in a Radiology Department and the comparison should be made between the relationship of the sinusal teeth and the maxillary sinus in terms of pathology at this level.

CONCLUSIONS

The closer the root of a tooth to the maxillary sinus, the more easily the dental pathology can spread to the sinus. Knowing these dento-sinusal relationships, there is a win-win situation for both the ENT doctor and the dentist. The paraclinical examination necessary for the analysis of the dento-alveolo-sinusal relation and of the afferent pathology is the imaging one, of choice being the CT and CBCT scans.

By careful radiological examination and the right choice of treatment, the dentist can prevent iatrogenic or even treat odontogenic sinusitis. On the other hand, the ENT doctor must identify the etiology of sinusitis, and treat the condition when the situation requires it. This collaboration is beneficial for both doctors and patients.

Acknowledgements/Financial Disclosure: None

Conflict of interest: The author has no conflict of interest to declare.

Contribution of authors: All the authors have equally contributed to this work.

REFERENCES

1. Alghamdi HS, Jansen JA. The development and future of dental implants. *Dent Mater J.* 2020;39(2):167-72. DOI: 10.4012/dmj.2019-140.
2. Brook I. Sinusitis of odontogenic origin. *Otolaryngol Head Neck Surg.* 2006;135(3):349-55. DOI: 10.1016/j.otohns.2005.10.059.
3. Ludlow JB, Ivanovic M. Comparative dosimetry of dental CBCT devices and 64-slice CT for oral and maxillofacial radiology. *Oral Surg Oral Med Oral Pathol Oral Radiol Endod.* 2008;106(1):106-14. DOI: 10.1016/j.tripleo.2008.03.018.
4. Hameed SK, Santawy AE, Alasmari D. Radiographic evaluation of the anatomical relationship of maxillary sinus floor with maxillary posterior teeth apices in the population of Al-Qassim, Saudi Arabia, using cone beam computed tomography. *The Saudi Dental Journal.* [Inter-

- net]. 2020. Published online 19 March 2020. Available from: <https://www.sciencedirect.com/science/article/pii/S1013905219312155>. DOI: 10.1016/j.sdentj.2020.03.008.
5. Kwak HH, Park HD, Yoon HR, Kang MK, Koh KS, Kim HJ. Topographic anatomy of the inferior wall of the maxillary sinus in Koreans. *Int J Oral Maxillofac Surg.* 2004;33(4):382-8. DOI: 10.1016/j.ijom.2003.10.012.
 6. Jung YH, Cho BH. Comparison of panoramic radiography and cone beam computed tomography for assessing the relationship between the maxillary sinus floor and maxillary molars. *Korean Journal of Oral and Maxillofacial Radiology.* 2009;39(2):69-73.
 7. Fry RR, Patidar DC, Goyal S, Malhotra A. Proximity of maxillary posterior teeth roots to maxillary sinus and adjacent structures using Denta scan®. *Indian J Dent.* 2016;7(3):126-130. DOI: 10.4103/0975-962X.189339.
 8. Abrahams JJ, Glassberg RM. Dental disease: a frequently unrecognized cause of maxillary sinus abnormalities? *AJR.* 1996;166(5):1219-23.
 9. Gehlot PM, Manjunath V, Manjunath MK. Maxillary sinusitis as a complication of infected dens invaginatus in maxillary lateral incisor: A case report. *Dent Hypotheses.* 2015;6(3):117-22. DOI: 10.4103/2155-8213.163817.
 10. Lee KC, Lee SJ. Clinical features and treatments of odontogenic sinusitis. *Yonsei Med J.* 2010;51(6):932-7. DOI: 10.3349/ymj.2010.51.6.932.
 11. Chemli H, Mnejja M, Dhoubi M, Karray F, Ghorbel A, Abdelmoula M. Sinusites maxillaires d'origine dentaire: traitement chirurgical. *Revue de Stomatologie et de Chirurgie Maxillo-faciale.* 2012;113(2):87-90. DOI: 10.1016/j.stomax.2011.12.013.
 12. Longhini AB, Ferguson BJ. Clinical aspects of odontogenic maxillary sinusitis: a case series. *International Forum of Allergy & Rhinology.* 2011;1(5):409-15. DOI: 10.1002/alr.20058.
 13. Fadda GL, Berrone M, Crosetti E, Succo G. Monolateral sinonasal complications of dental disease or treatment: when does endoscopic endonasal surgery require an intraoral approach? *Acta Otorhinolaryngol Ital.* 2016;36(4):300-9. DOI: 10.14639/0392-100X-904.

© 2021 Daniel Lupoi, Mihai Dragomir, Gabriela Coadă, Alexandra Sanda, Vlad Budu, published by Romanian Rhinologic Society



This is an open access article published under the terms and conditions of the Creative Commons Attribution-NonCommercial-NoDerivatives 4.0 International (CC BY-NC-ND 4.0) License (<https://creativecommons.org/licenses/by-nc-nd/4.0/>). CC BY-NC-ND 4.0 license requires that reusers give credit to the creator by citing or quoting the original work. It allows reusers to copy, share, read, download, print, redistribute the material in any medium or format, or to link to the full texts of the articles, for non-commercial purposes only. If others remix, adapt, or build upon the material, they may not distribute the modified material.