

SHORT SCIENTIFIC COMMUNICATION

Pneumatization and extensions of the sphenoid sinus: a CT overlook

Vlad Budu^{1,2}, Silviu Crac², Cristina Goanta^{1,3}, Patricia Delia Farcasanu⁴, Tatiana Decuseara⁵, Daniel Lupoi^{1,6}

¹“Carol Davila” University of Medicine and Pharmacy, Bucharest, Romania

²“Prof. Dr. D. Hociota” Institute of Phono-Audiology and Functional ENT Surgery, Bucharest, Romania

³ENT Department, “Sf. Pantelimon” Clinical Emergency Hospital, Bucharest, Romania

⁴ENT Department, Noblesse Medical Clinique, Bucharest, Romania

⁵ENT Department, CHU de Lyon - Groupement Hospitalier Edouard Herriot, Lyon, France

⁶ENT&HNS Department, "Sfanta Maria" Hospital, Bucharest, Romania

ABSTRACT

The sphenoid bone has a specific development during fetal life, until it reaches its complete dimensions. The sphenoid cavities are usually undeveloped at birth and they reach their full volume only after puberty. Pneumatization of the sphenoid sinus is unpredictable and different for each person.

The authors do not intend to develop a literature review or to compare their experience with data already published. The paper is not an original imagistic study of the authors, it only represents a short communication on the imagistic anatomy of the sphenoid sinus, in order to avoid complications during surgery in the area.

Based on their patients own CT-scan examination, the authors try to classify the anterior, lateral and posterior extensions in close connection with the surgical endoscopic approach of the sphenoid sinus.

KEYWORDS: sphenoid sinus, sphenoid extensions, FESS.

INTRODUCTION

The sphenoid bone represents a complex structure, situated in the middle of the skull, between the ethmoid bone and the basilar part of the occipital bone. This unpaired bone has the shape of a bat or butterfly with its wings wide open and consists of a median part (the body of the sphenoid), the greater wings situated laterally, the lesser wings situated anteriorly and the pterygoid processes directed downwards^{1,2}. The body of the sphenoid contains the sella turcica region and the sphenoid sinuses, which are osseous cavities, usually with asymmetric pneumatization.

During fetal development, the body of the sphenoid has two parts: the presphenoid, anterior to the tuberculum sellae with ossifying centers for the lesser wings, and the postsphenoid consisting of the sella turcica and the dorsum sellae, with

ossifying centers for the great wings and the pterygoid processes^{1,2}. Usually, at birth, the sphenoid cavities are undeveloped, but the pneumatizing process advances slowly, and the sphenoid sinuses reach their full size only after puberty.

The pneumatization of the sphenoid sinus is different from one person to another, which creates different types of sphenoid sizes. During the bony development, anterior, lateral and inferior extensions of the sphenoid cavity may appear. While performing an endoscopic surgical approach of the sphenoid pathology, it is compulsory to know exactly the dimensions and extensions of the sphenoid in order to avoid complications which may occur¹⁻⁶. The gold standard of the sphenoid sinus investigation is represented by the computed tomography (CT) imaging, which is mandatory for every endoscopic approach of the region⁴⁻¹⁵.

Corresponding author: Vlad Budu, MD, PhD, Lecturer, “Prof. Dr. D. Hociota” Institute of Phono-Audiology and Functional ENT Surgery 21 Mihail Cioranu Street, District 5, 061344, Bucharest, Romania

e-mail: vladbudu@yahoo.com

Received for publication: September 7, 2020 / **Accepted:** November 2, 2020

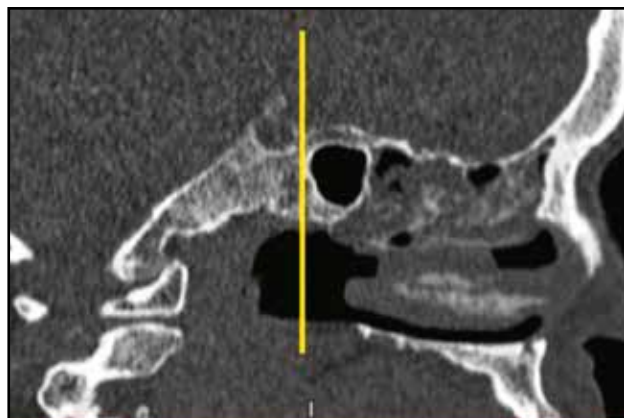


Figure 1. Conchal type pneumatization of the sphenoid sinus (cranio-facial CT scan, sagittal slice).

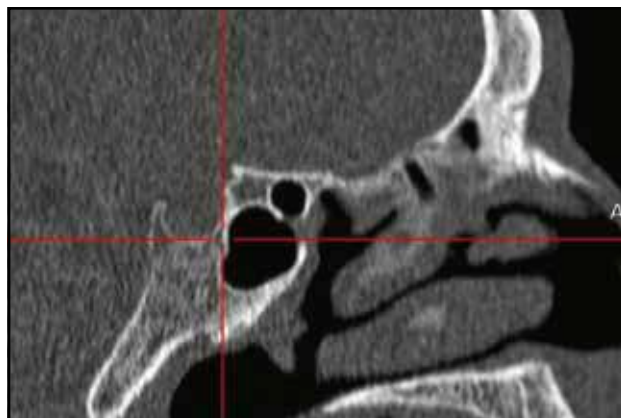


Figure 2. Presellar type pneumatization of the sphenoid sinus (cranio-facial CT scan, sagittal slice).

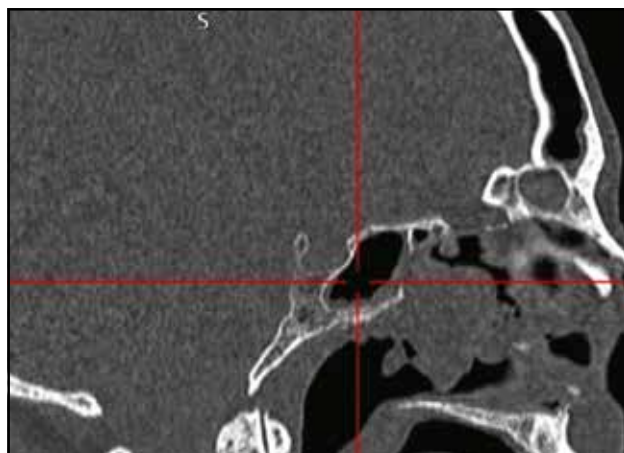


Figure 3. Incomplete sellar type pneumatization of the sphenoid sinus (cranio-facial CT scan, sagittal slice).

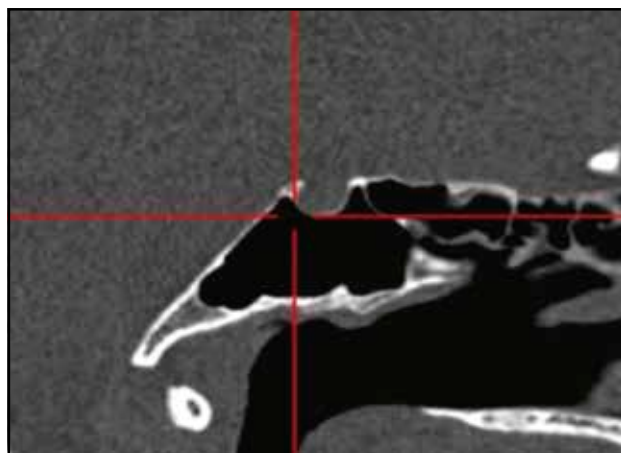


Figure 4. Complete sellar type pneumatization of the sphenoid sinus (cranio-facial CT scan, sagittal slice).

PNEUMATIZATION OF THE SPHENOID SINUS

Conchal type

In the conchal type of the sphenoid, the distance from the pneumatized cavity to the anterior wall of the sella is greater than 10mm^{11,13-15}. On CT scan examination, the images point out the presence of bony tissue between the posterior wall of the sphenoid sinus and the anterior wall of the sella (Figure 1). This anatomic configuration makes very difficult the endoscopic approach of the sellar region during pituitary surgery, with a high risk of complications.

Presellar type

In the presellar type of sphenoid sinus, the posterior margin of the sinus pneumatization is situated just anterior to the anterior wall of the sella^{10,13-15}.

In this particular situation, during sphenoid surgery, the posterior wall of the sphenoid, in its superior part, is considered the anterior wall of the sella turcica. Examining the CT images, we can al-

ways find vertical collinearity from the anterior wall of the sella and the posterior wall of the sphenoid sinus (Figure 2).

Incomplete sellar type

In the incomplete sellar type, the posterior margin of sphenoid pneumatization is situated beneath the sella, in between the two sellar walls (anterior and posterior).

On CT examination, the posterior wall of the sphenoid will never lie beyond the posterior wall of the sella^{10,13-15}. This is a quite friendly surgical situation for the interdisciplinary surgical team, first of all because of the wide dimensions of the sphenoid sinus and second because of the safe distance to the important anatomic elements (internal carotid artery, optic nerve, etc) which may be damaged during the endoscopic sinus approach (Figure 3).

Complete sellar type

In the complete sellar type, the posterior margin of pneumatization lies posterior to the posterior

wall of the sella. In this anatomic situation, the anterior wall of the sphenoid is usually found on CT images lying higher than the posterior wall, which is always situated posterior to the posterior wall of the sella, reaching the clivus (Figure 4).

During pituitary surgery, the endoscopic technique will approach the superior wall of the sphenoid, but surgery for the pathology situated in the inferior part of the sphenoid will carefully approach the anterior sphenoid wall, in order to avoid complications that may occur (vidian nerve, sphenopalatine artery)^{11,13-15}.

EXTENSIONS OF THE SPHENOID SINUS

During the bony development process, the volume of the sphenoid sinus may increase due to the pneumatized extensions towards anterior, lateral or posterior sinus walls^{11,14,15}. In order to accurately examine the CT scan images, it is important to use the triplanar view, and to check the axial plane for the anterior extensions of the sphenoid sinus, the sagittal images for posterior extension and the coronal plane for the lateral sinus extensions.

Anterior extensions of the sphenoid sinus

The most common anterior extension of the sphenoid sinus following a midline direction ends in the posterior bony part of the nasal septum^{11,15}. In this situation, the rostrum septale appears to be enlarged and the sphenoid ostium will be in an oblique position while performing an endoscopic sphenoidotomy.

The CT images reveal the anterior pneumatization in the vomerian region and the reduction of the sphenoidal recess (Figure 5). In such an anatomical alternative, a transeptal approach of the sphenoid sinus pathology may be the first surgical choice.

Another possibility for an anterior extension of the sphenoid sinus is onto the sphenoidal recess. In this particular case, the CT images reveal the anterior protrusion of the anterior wall of the sphenoid sinus and the complete contact of this wall with the superior turbinate (Figure 6). During an endoscopic approach, the sphenoidotomy must be performed as medially as possible, one cm above the superior border of the choana.

The antero-lateral extension of the sphenoidal pneumatization can reach the posterior wall of the maxillary sinus. Anatomic alternatives are described, in which the lateral part of the anterior wall of the sphenoid sinus is in contact with the posterior wall of the maxillary sinus. In such cases, the CT images reveal the important decrease of the pterygopalatine fossa and the unique wall between maxillary and sphenoid sinuses (Figure 7).

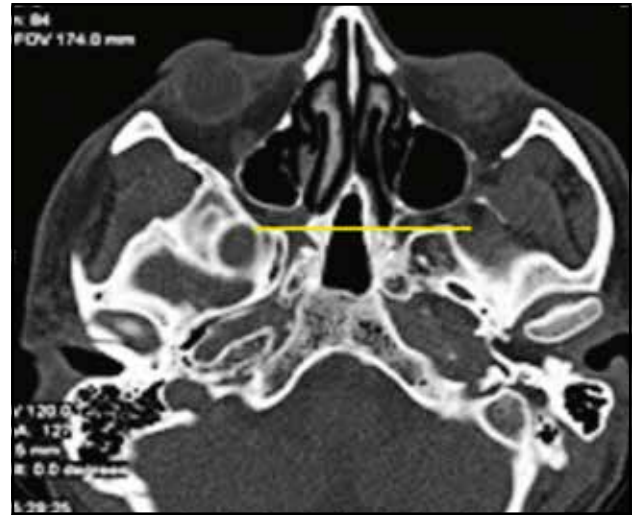

Figure 5. Vomerian extension of the sphenoid sinus (crano-facial CT scan, axial slice).

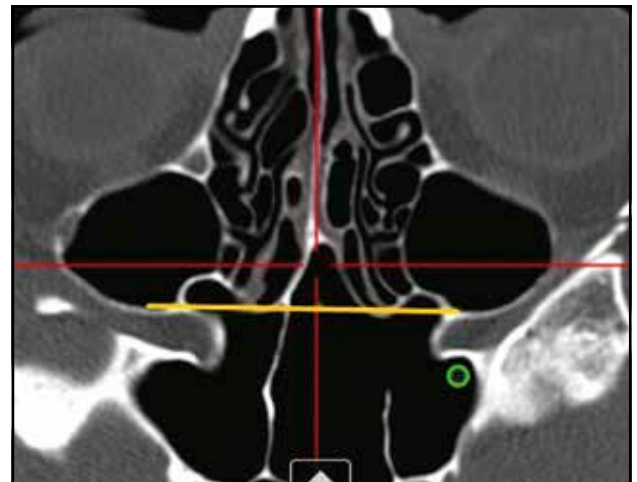


Figure 6. Sphenoidal recess extension (crano-facial CT scan, axial slice).

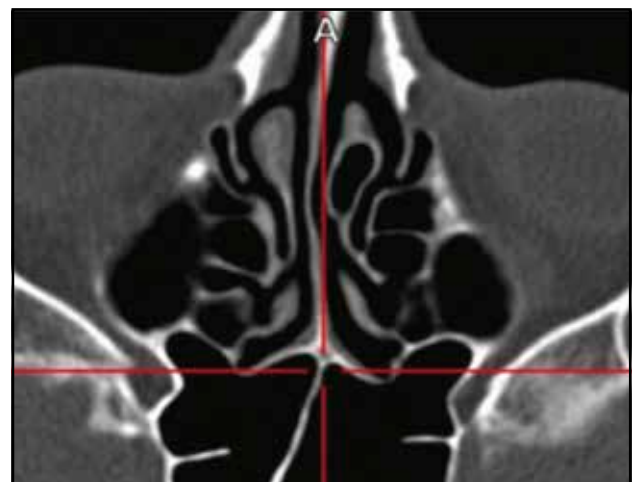

Figure 7. Antero-lateral extension of the sphenoid (crano-facial CT scan, axial slice).

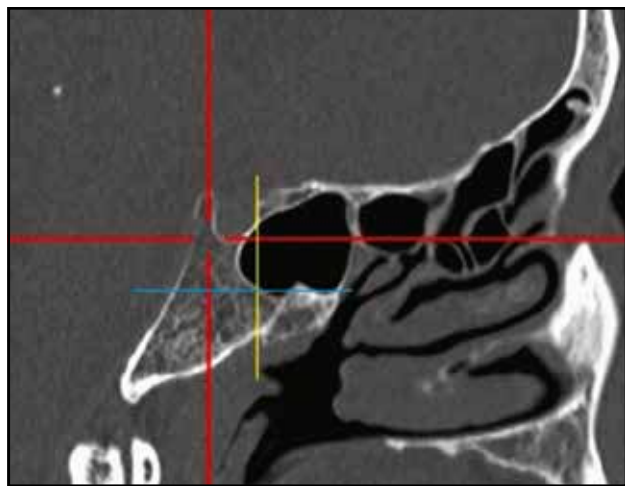


Figure 8. Subdorsal extension (cranio-facial CT scan, sagittal slice; blue horizontal line - the vidian canal, vertical yellow line - along the posterior wall of the sella).

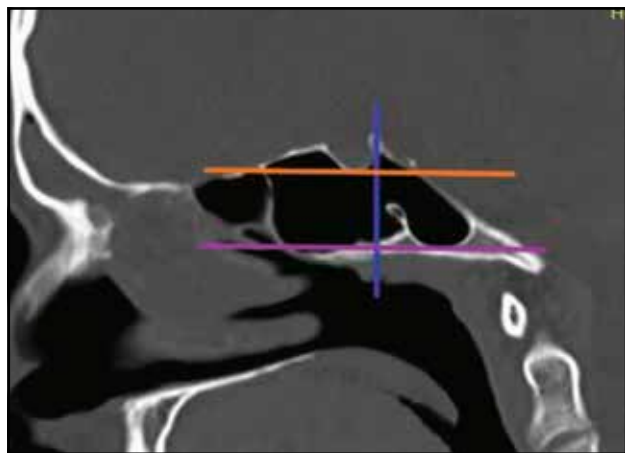


Figure 9. Dorsal extension - superiorly into the dorsum sella (cranio-facial CT scan, sagittal slice; purple horizontal line - the vidian canal, orange horizontal line - the inferior margin of the sella, blue vertical line - the posterior wall of the sella).

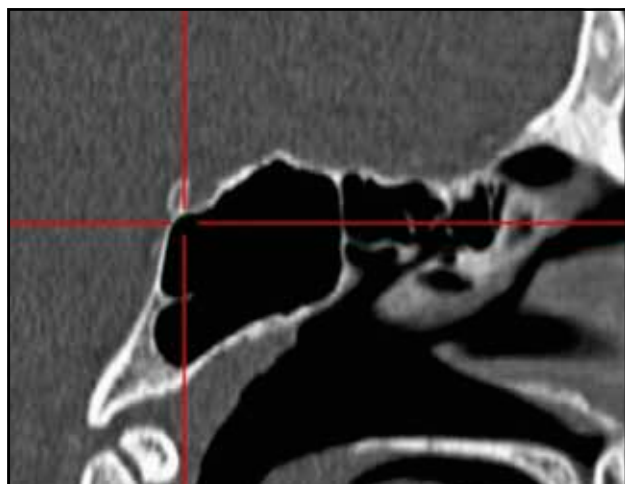


Figure 10. Occipital extension – inferior to the level of the vidian nerve (cranio-facial CT scan, sagittal slice).

Posterior extensions of the sphenoid sinus

In the **subdorsal type** of posterior extension of pneumatization, the posterior wall of the sphenoid sinus is situated under the inferior part of the sella^{9,15}. On the CT images, the pneumatization does not extend posteriorly behind the posterior sellar wall. In this case, pneumatization does not extend below the level of the vidian canal, which assures a low risk of complications during endoscopic surgery (Figure 8).

In the **dorsal type**, the pneumatization extends superiorly into the dorsum sella^{11,15}. The CT examination reveals a highly aerated sphenoid cavity, with pneumatization between the dorsum sella and the posterior wall of the sphenoid (Figure 9). The pathology situated in this region might be more difficult to approach and the use of angulated endoscopes and surgical instruments is indicated in order to avoid skull base injury.

If the pneumatization of the sphenoid sinus extends inferiorly to the level of the vidian canal, we can describe the **occipital type**^{11,15}. It is important to determine on CT examination the position of the vidian canal, the sellar region and the posterior and inferior extension into the clivus (Figure 10). In this anatomic situation, it is useful to perform a large sphenoidotomy, in a safe medial and superior direction.

The **combined type** of pneumatization of the sphenoid sinus shows the posterior extension behind the dorsum sella (dorsal type) and posterior and inferior into the clivus (occipital type)^{11,15}. Even if we discover on CT a highly aerated sinus cavity, it is important to locate the pterygoid canal, which may sometimes protrude into the sphenoid sinus (Figure 11). The pterygoid canal is very important in endoscopic surgery, first because of its

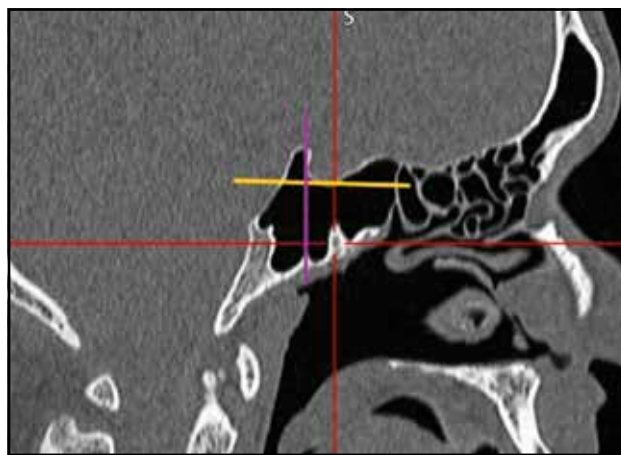


Figure 11. Combined extension (cranio-facial CT scan, sagittal slice; yellow horizontal line- inferior margin of the sella, purple vertical line – the posterior wall of the sella).

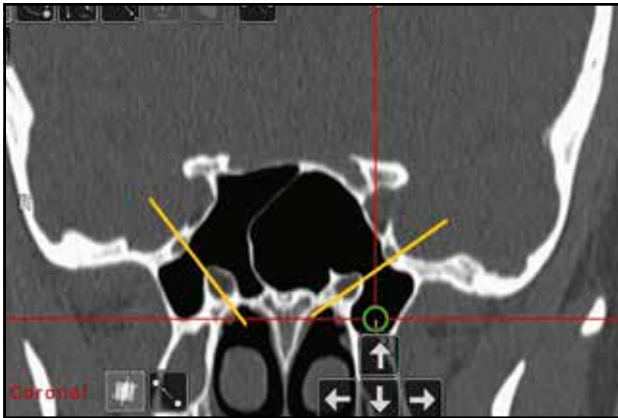

Figure 12. Pterygoidian extension - situated under the level of the vidian canal (green circle) and into the pterygoidian process (cranio-facial CT scan, coronal slice; yellow line – along the vidian canal and the medial margins of the foramen rotundum).

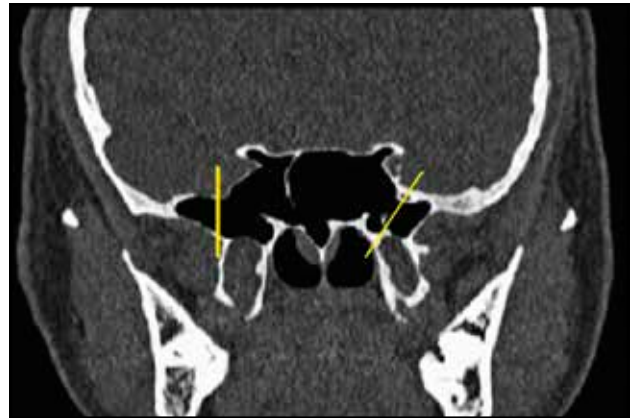

Figure 13. Greater wing extension type on the left side- pneumatization laterally on the sphenoid sinus wall (cranio-facial CT scan, coronal slice; yellow line – along the vidian canal and the medial margins of the foramen rotundum).

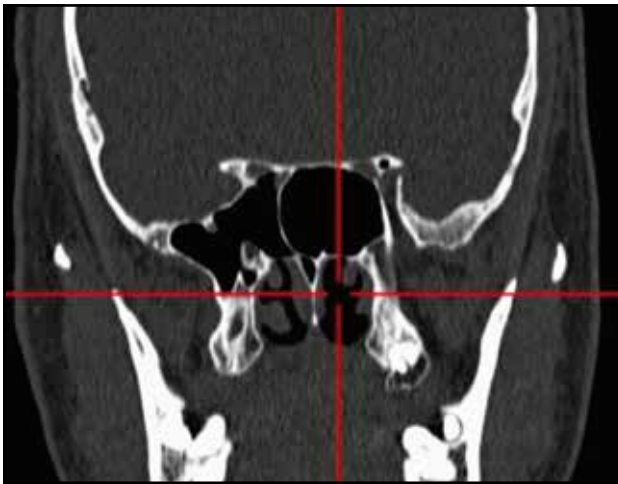

Figure 14. Complete lateral extension- pneumatization which extends in the greater wing and in the pterygoidian process (cranio-facial CT scan, coronal slice).

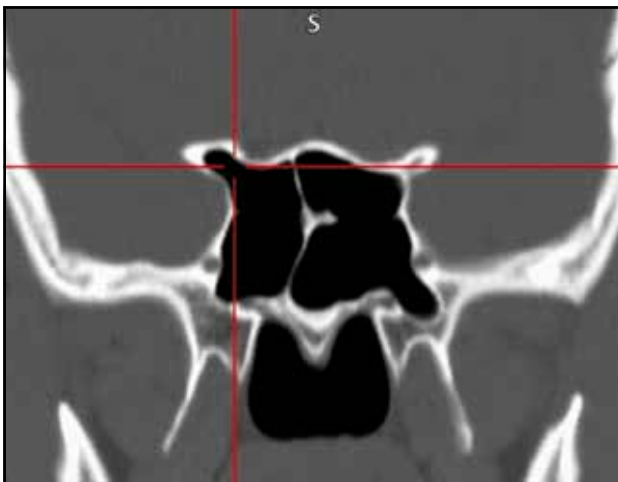

Figure 15. Lesser wing extension (right sphenoid sinus) (cranio-facial CT scan, coronal slice).

content (vidian artery and vidian nerve) and second because it represents an important landmark for the internal carotid artery, which is always situated lateral to the vidian canal.

Lateral extensions of the sphenoid sinus

The **pterygoidian type** of a lateral pneumatization is situated under the level of the vidian canal and extends into the pterygoid process^{12,15}. The CT images describe the most important landmarks for a lateral extension (the vidian nerve and the maxillary nerve) and reveal the pneumatization of the pterygoid process (left side) (Figure 12). It is one of the most challenging surgical situations, because of the lateral approach (angulated endoscopes and instruments) and the high-risk structures in this anatomic area (vidian and sphenopalatine arteries, maxillary and palatine nerves).

The **greater wing extension type** is described when the pneumatization is found laterally on the sphenoid sinus wall^{12,14,15}. The most significant anatomic landmark on CT is the maxillary nerve (V2) canal (Figure 13), so any pneumatization lateral to this point is considered to invade the greater wing. In this case, surgery must be very carefully performed because of the high-risk anatomic elements of the lateral sphenoid region (internal carotid artery, optic nerve, cavernous sinus).

A **complete lateral extension** of the sphenoid sinus is defined by a pneumatization which extends in the greater wing and in the pterygoid process^{12,15}. In the CT image, the sphenoid of the left side has a complete lateral extension with pneumatization lateral to the maxillary nerve canal and inferior to the pterygoid canal (Figure 14). In such cases, a large opening of the anterior wall of the sphenoid sinus can provide safe surgical conditions in order to avoid all the complications that

may occur during sphenoid endoscopic surgery.

A rare lateral extension of pneumatization can be found into the **lesser wing** of the sphenoid^{11,14,15}. The CT scan must determine the precise position of the sella, of the lateral wall of the sphenoid and its landmarks and the integrity of the skull base (Figure 15). The endoscopic approach of the sphenoid performed in this specific area has to discover as landmarks of major importance the carotid canal, the optic nerve impression on the lateral sphenoid wall and the carotid-optic recess in order to avoid vital

CONCLUSIONS

In conclusion, it is important to be aware of the great anatomic variations of the sphenoid sinus. It is mandatory to have a CT exam before surgery, and, based on imagistic proofs, to decide a strategic surgical plan designated for each unique sphenoid pathology, in order to avoid complications which may occur during endoscopic surgery in this anatomic region.

Acknowledgements/Financial Disclosure: None

Conflict of interest: The author has no conflict of interest to declare.

Contribution of authors: All the authors have equally contributed to this work.

REFERENCES

1. Stammberger H. Functional Endoscopic Sinus Surgery. Mosby Inc. USA; 1991, p. 89-145.
2. Levine H, May M. Endoscopic Sinus Surgery. Thieme Medical Publisher, New York; 1993, p. 29-60.
3. Chong VJ, Fan YF, Tng CH. Radiology of the sphenoid bone. Clin Radiol. 1998;53(12):882-93. DOI: 10.1016/s0009-9260(98)80214-6.
4. Arslan H, Aydinlioglu A, Bozkurt M, Egeli E. Anatomical variations of the paranasal sinuses: CT examination for endoscopic sinus surgery. Auris Nasus Larynx. 1999;26(1):39-48. DOI: 10.1016/s0385-8146(98)00024-8.
5. Haetinger RG. Imaging of the nose and paranasal sinuses. In: Stamm A, Draf W. (eds.) Micro-endoscopic surgery of the paranasal sinuses and the skull base. Springer Verlag, Germany; 2000, p. 53-81.
6. Perez-Pinas I, Sabate J, Carmona A, Catalina-Herrera CJ, Jimenez-Castellanos J. Anatomical variations in the human paranasal sinus region studied by CT. J Anat. 2000;197(Pt 2):221-7. DOI: 10.1046/j.1469-7580.2000.19720221.x.
7. Zinreich SJ, Gotwald T. Radiographic anatomy of the sinuses. In: Kennedy D, Bolger W, Zinreich J. (eds.) Disease of the Sinuses. B.C. Decker, London; 2001, p. 13-29.
8. Kazkayasi M, Karadeniz Y, Arikan OK. Anatomic variations of the sphenoid sinus on computed tomography. Rhinology. 2005;43(2):109-14.
9. Haetinger RG, Navarro JAC, Liberti EA. Basilar expansion of the human sphenoidal sinus: an integrated anatomical and computerized tomography study. Eur Radiol. 2006;16(9):2092-9. DOI: 10.1007/s00330-006-0208-3.
10. Idowu OE, Balogun BO, Okoli CA. Dimensions, septation, and pattern of pneumatization of the sphenoidal sinus. Folia Morphol. 2009;68(4):228-32.
11. Wang J, Bidari S, Inoue K, Yang H, Rhoton A. Extensions of the sphenoid sinus: a new classification. Neurosurgery. 2010;66(4):797-816. DOI: 10.1227/01.NEU.0000367619.24800.B1.
12. Vaezi A, Cardenas E, Pinheiro-Neto C, Paluzzi A, Branstetter BF 4th, Gardner PA, et al. Classification of sphenoid sinus pneumatization: relevance for endoscopic skull base surgery. Laryngoscope. 2015;125(3):577-81. DOI: 10.1002/lary.24989.
13. Gibelli D, Cellina M, Gibelli S, Oliva AG, Termine G, Sforza C. Anatomical variants of sphenoid sinuses pneumatization: a CT scan study on a Northern Italian population. Radiol Med. 2017;122(8):575-80. DOI: 10.1007/s11547-017-0759-1.
14. Hiremath SB, Gautam AA, Sheeja K, Benjamin G. Assessment of variations in sphenoid sinus pneumatization in Indian population: a multidetector computed tomography study. Indian J Radiol Imaging. 2018;28(3):273-9. DOI: 10.4103/ijri.IJRI_70_18.
15. Budu VA. Imagistica CT in Rinologie. Editura Callisto, Romania; 2020.

© 2021 Vlad Budu, Silviu Crac, Cristina Goanta, Patricia Delia Farcasanu, Tatiana Decuseara, Daniel Lupoi, published by Romanian Rhinologic Society



This is an open access article published under the terms and conditions of the Creative Commons Attribution-NonCommercial-NoDerivatives 4.0 International (CC BY-NC-ND 4.0) License (<https://creativecommons.org/licenses/by-nc-nd/4.0/>). CC BY-NC-ND 4.0 license requires that reusers give credit to the creator by citing or quoting the original work. It allows reusers to copy, share, read, download, print, redistribute the material in any medium or format, or to link to the full texts of the articles, for non-commercial purposes only. If others remix, adapt, or build upon the material, they may not distribute the modified material.