

ORIGINAL STUDY

Factors associated with survival in diabetic patients with rhino-orbito-cerebral mucormycosis

Mario Andrés Sepúlveda Martínez¹, Juan Antonio Lugo-Machado¹, Edwin Canché-Martín¹, Noemí Sainz-Fuentes¹, Roberto Reina-Loaiza¹, Said Rodríguez-Quintana¹, Alfonso Rubio Espinoza¹

¹Otolaryngology Service, “Luis Donaldo Colosio Murrieta” Specialty Hospital No 2, Mexican Institute of Social Service, Ciudad Obregón, Sonora, México

ABSTRACT

BACKGROUND. Mucormycosis is an emerging angioinvasive, potentially fatal infection caused by the ubiquitous filamentous fungi of the order Mucorales of the class Phycomycetes. They occur particularly in metabolically decompensated diabetic patients.

OBJECTIVE. To evaluate the factors associated with survival in a group of diabetic patients with rhino-orbito-cerebral mucormycosis.

MATERIAL AND METHODS. A case-control study of a series of cases from January 2013 to May 2020 was designed. Patients with diabetes mellitus and a diagnosis of rhino-orbito-cerebral mucormycosis were included. The clinical findings were considered, as well as age, gender, laboratory and radiological results, and mortality. For the statistical analysis, we used descriptive statistics, Mann Whitney U test. We considered a p-value equal to or less than 0.05 to indicate a statistically significant association or difference. Likewise, the odds ratio was used to determine the relative risk.

RESULTS. 19 cases were included, with an average age of 60.8 years and female gender predominance. In 100% of the cases, non-septate hyphae were identified in histopathological studies. We had a mortality of 7 (36.8%), where the rhino-orbital complications were the most frequent. The findings of CRP ≤ 23.1 mm/L, an absolute neutrophil count $\geq 13.2 \times 1000 / \mu\text{l}$ and absence of bone erosion in the simple tomography, the rhino-orbital stage, could be related to greater survival.

CONCLUSION. Our series presented mortality close to 40%. Age < 64 years, CRP ≤ 23.1 mm/L, absolute neutrophil count $\geq 13.2 \times 1000 / \mu\text{l}$ and absence of bone erosion in the simple tomography, rhino-orbital stage were associated with a better survival in our series.

KEYWORDS: mucormycosis, diabetes mellitus, survival.

INTRODUCTION

More than 220 million people worldwide were living with Diabetes Mellitus (DM) in 2011, and the World Health Organization (WHO) forecasts that the number of DM deaths is likely to double by 2030. This increasing prevalence has an uneven global distribution, with at least 80% of DM-related deaths in low- and middle-income countries. The increasing trend of mucormycosis associated with diabetes is currently seen very frequently, especially in uncontrolled DM, and has a mortality rate that ranges from 32% to 57%¹.

Sinonasal mucormycosis is a rare disease, and

mainly affects diabetics and immunosuppressed patients; rarely, it can infect normal hosts. Mucor can compromise the lung, the central nervous system, the gastrointestinal tract, and the skin. The most common presentation is rhino-orbito-cerebral mucormycosis, which initially affects the nose and paranasal sinuses, and can progress to the orbit and the brain. The first description of mucormycosis of the upper airways was made in 1885 by Paltauf, who used the term mucorin mycosis, which was later modified to mucormycosis. In the literature, there is an agreement in classifying fungal rhinosinusitis as: invasive and non-invasive. Invasive fungal rhinosinusitis is, in turn, classified as:

acute fulminant, invasive granulomatous and chronic invasive. Non-invasive fungal rhinosinusitis is classified as: mycetoma and allergic fungal².

The term mucormycosis is applied to any fungal infection by the Mucorales order, belonging to the Zygomycetes class. Most of the pathogenic species are members of the Mucoraceae family. *Rhizopus Oryzae* is the predominant pathogen; reaches 60% of all forms of mucormycosis and is found in 90% of rhino-cerebral cases³.

In a series of 179 patients with mucormycosis, 126 (72%) were diabetics⁴. Patients with uncontrolled hyperglycaemia, particularly those with ketoacidosis, are the most susceptible to infection⁵. The most common presenting features were fever, headache, facial swelling and proptosis. Many patients presented blindness, facial paralysis and meningitis. The predisposing causes is uncontrolled diabetes with ketoacidosis⁶.

The mainstay of treatment for rhino-orbito-cerebral mucormycosis is surgical debridement, early medical therapy with amphotericin B, and reversing the host's ketoacidotic or immunosuppressive state⁴. Surgical debridement is part of the cornerstone of the treatment. Hargrove et al. also report that patients with the same symptoms and the same risk factors, but in whom the exenteration of the eyeball is practiced, have a higher survival rate^{7,8}.

Within the imaging studies, the computed tomography of the paranasal sinuses with 4 mm slices has shown a variable degree of mucosal edema, opacification, bone destruction to a different degree, involvement of orbital tissue or meninges. The pterygopalatine fossa generally constitutes the main reservoir of the fungus⁹. The fungus can spread along the nerve orifices, cribriform lamina, the orbit and the ophthalmic artery to the meninges and the brain. Fungal vascular invasion leads to infarction and necrosis of the brain and imminent death. Wiatrac et al. found that CT scans in fungal sinusitis did not correlate well with surgical and histopathological findings¹⁰. However, other authors like Thomas J. Walsh indicate that early CT findings may reveal lesions before presenting symptoms in immunocompromised patients with high risk of invasive sinopulmonary mucormycosis¹¹.

It has been reported that cases of localized mucormycosis have a low mortality rate (10%), while the ones associated with a worse prognosis are those with brain involvement. However, the general prognosis has improved considerably in recent years^{12,13}.

Chronic hyperglycemia has been documented to cause polymorphonuclear leucocytosis, a series of alterations characterized by decreased adherence and chemotaxis to the vascular endothelium, phagocytosis, intracellular bactericidal activity, op-

sonization, and cell-mediated immunity. All these phenomena decrease the function of the neutrophils. A significant improvement in the adherence of neutrophils has been demonstrated in diabetic patients with poor control, by reducing the glycemia from 294 ± 20 mg/dl to 198 ± 29 mg/dl. This demonstrated that an average plasma glycemia value of 200 mg/dl can cause leukocyte dysfunction¹⁴. Neutropenia is defined as an absolute neutrophil count of less than 1,500/ μ l in adult peripheral blood¹³. It is classified according to its intensity as: mild neutropenia - 1,000 to 1,500 neutrophils/ μ l; moderate - 500 to 1,000 neutrophils/ μ l; severe - less than 500 neutrophils/ μ l¹⁵. Immunocompromised hosts with granulocyte deficiency are at higher risk of developing opportunistic bacterial and fungal infection¹⁶.

Some authors report that C-reactive protein (CRP) and erythrocyte sedimentation rate (ESR) have a positive association with acute and chronic medical conditions. However, elevated ESR was observed more frequently in acute medical conditions compared to CRP¹⁷. Some other authors, such as Wu D., have associated an elevation in ESR of 77mm/h and CRP of 12 mg/l, with the severity of the condition^{18,19}. Park et al. observed elevated levels of CRP (> 0.14 mg/dL) and ESR (> 15 mm/h) related to general survival in a group of patients with sarcoma²⁰.

We believe that these results could be transported to our cases and evaluate their correlation with mortality.

MATERIAL AND METHODS

A retrospective case-control study was designed at the Specialty Hospital no. 2, Northwestern National Medical Center (UMAE) in a period from January 01, 2013 to May 30, 2020, with a view to determining the risk factors associated with mortality in patients with rhino-orbito-brain mucormycosis.

Patients with diabetes mellitus who had been diagnosed with the different clinical presentations of rhino-orbito-brain mucormycosis were integrated in the study. Clinical, laboratory, radiological and mortality findings were considered, as well as age, gender. Entity cases of incomplete files and those that did not have a histopathological report or that were found to be different from mucormycosis were excluded.

For the statistical analysis, Student or Mann Whitney U tests will be used and a p-value equal to or less than 0.05 will be considered for statistical significance, likewise we will use odd ratio to determine relative risk.

RESULTS

In the period of time reviewed, that comprised from January 2013 to May 2020, 24 files were located, excluding 5 for not meeting the inclusion criteria, remaining 19 cases that were considered for the study. In 100% of the cases, non-septate hyphae with right-angle branches were identified and the histopathological studies reported mucormycosis in haematoxylin-eosin staining. The types of presentation were: rhinosinusal in 6 cases, rhino-

orbital in 7 cases and rhino-orbito-cerebral in 6 cases. We had a mortality of 7 (36.8%) of 19 cases.

The average age in the study group was 60.8 years (range 44 to 82), the predominant gender being female with 12 patients (63.16%), while 7 patients were male (36.84%) (Figure 1). Considering only the patients who died, in this group the average age was of 64 years, while in the survival group was of 58 years.

During the entire study period, the highest number of cases was in 2017 (Figure 2).

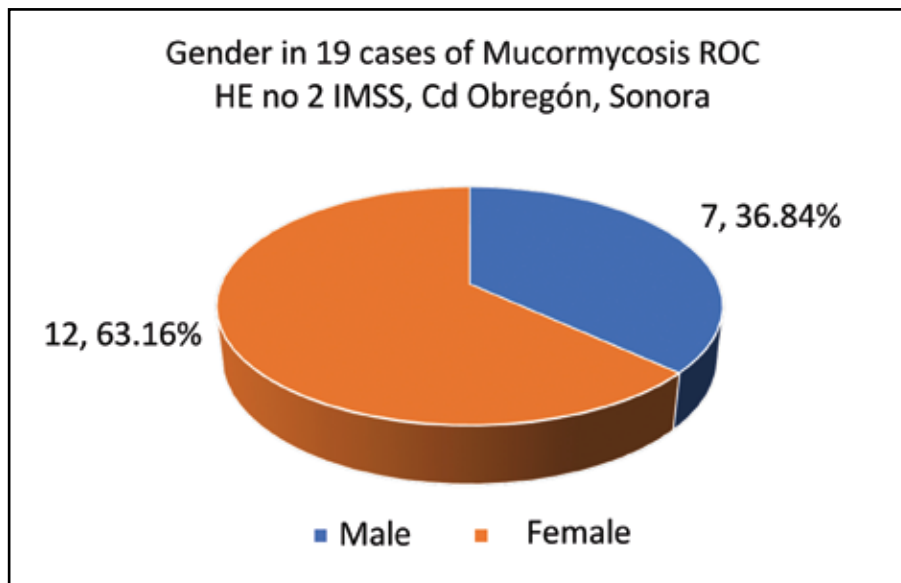


Figure 1. Gender repartition in the study group. (Source: clinical records from the clinical file at Specialty Hospital No. 2, UMAE, IMSS, Ciudad Obregon, Sonora, Mexico)

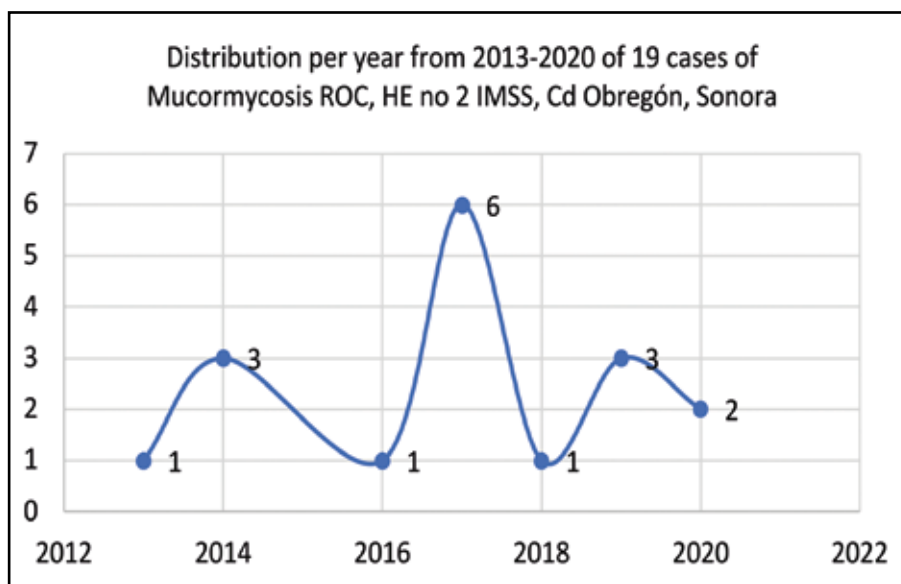


Figure 2. Patients' distribution per year from 2013 to 2020. (Source: clinical records from the clinical file at Specialty Hospital No. 2, UMAE, IMSS, Ciudad Obregon, Sonora, Mexico)

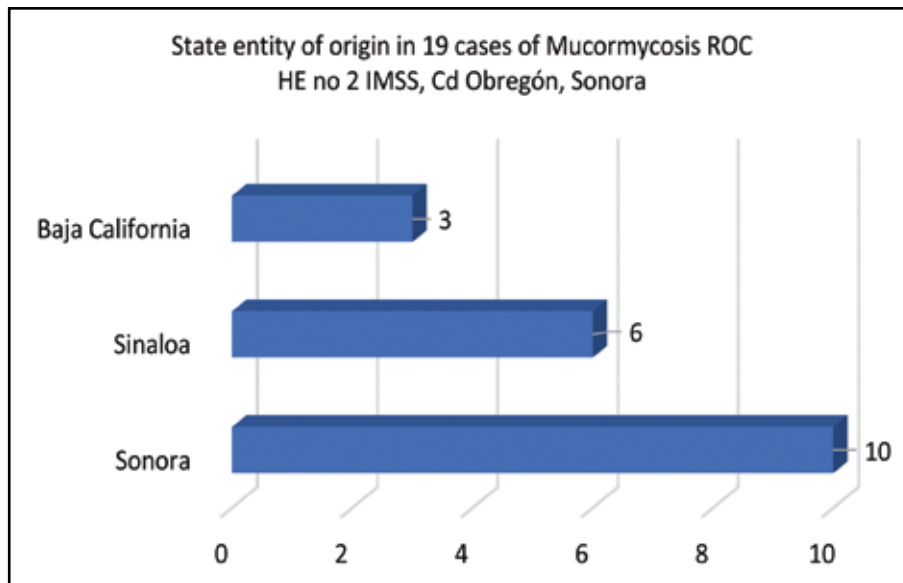


Figure 3. The distribution by state in the study group. (Source: clinical records from the clinical file at Specialty Hospital No. 2, UMAE, IMSS, Ciudad Obregón, Sonora, Mexico)

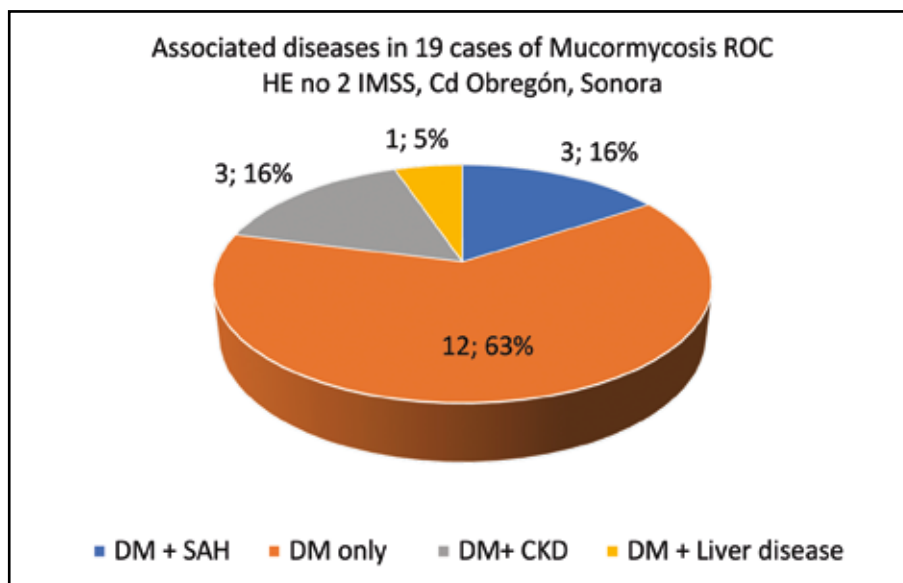


Figure 4. Associated diseases in the study group (Acronyms: DM = Type 2 Diabetes Mellitus, SAH = Systemic Arterial Hypertension, CKD = Chronic kidney disease). (Source: clinical records from the clinical file at Specialty Hospital No. 2, UMAE, IMSS, Ciudad Obregón, Sonora, Mexico)

Regarding the distribution by state, 10 patients were from Sonora, 6 from Sinaloa and 3 from Baja California (Figure 3).

Among the associated diseases, type 2 Diabetes Mellitus (type 2 DM) alone or in association with other pathologies was present in all patients. 12 patients had only type 2 DM and 7 patients had type 2 DM associated with arterial hypertension (3 cases), chronic kidney disease (3 cases), chronic liver disease (1 case) (Figure 4).

When using the nonparametric Mann-Whitney U test to compare two groups regarding stage and survival, no significant difference was found between stage advancement and survival (p -value = 0.28914). However, when performing the comparison of C-reactive protein (CRP) between the deceased and the survivors, a significant difference was found (p -value = 0.01684), where the lower the CRP elevation the greater the chance of survival. When comparing the erythrocyte sedimentation

rate (ESR) between the two groups, we did not find a significant statistical difference (p -value = 0.11642). However, when comparing the absolute neutrophil count between the deceased and the survivors, a significant difference was found when using the Mann-Whitney U test (p -value = 0.00108), where a count $\geq 13\mu\text{l}$ presents a greater chance of survival compared to those with a count $\leq 2\mu\text{l}$.

When using odds ratio (OR) to assess risk among patients with bone lysis on the CT scans, it was found that those without lytic bone lesions had an odd ratio of 0.17 compared to those with lytic bone lesions with an odd ratio of 6.

When we used the odds ratio to evaluate the rate of survival according to the location of the infection, we evaluated two groups of mucormycosis, one rhino-orbital (ROM) and the other rhino-cerebral (RCM). It was evidenced that patients with ROM had a greater survival rate, with an OR = 0.44, compared to RCM with an odd ratio of 2.25. When comparing survival among patients with ocular exenteration, the cases of exenteration had lower survival OR = 4, in comparison with the exenterates OR = 0.25, possibly due to the fact that the exenterated patients had greater progression of the disease.

DISCUSSIONS

The estimated annual incidence of mucormycosis in the United States is 1.7 cases / million²¹. In our 8-year study period (2013-2020), we found a prevalence of 24 cases, higher than that reported by Nan Jiang et al. with 11 cases between 2006 to 2013²².

The average age in our study group was 60.8 years (range 44 to 82), higher than that reported by Jiang et al. with 53.7 years (range 45-60 years) and Jeong et al. with 51 years (39 to 61 years)^{22,23}. Death cases had an average age higher than 64 years, while those who survived had an average age of 58 years. Our findings are similar to those described by Jayalakshmi et al.²⁴. In a study performed in 2007 on 38 patients, they concluded that age greater than 60 years presented a higher risk of death. However, in our series, there was not a statistically significant difference between the average age of death and survival group (p -value = 0.33204), similar to that reported by Jayalakshmi²⁴.

In our study, the predominant gender was female (12 patients, 63.16%), different from that reported by Corzo-Leon et al. in a systematic review where they indicated a higher number in men (54%)²⁵. Our results are similar to those reported by Abdollahi et al. (26.7% men and 73.3% women)²⁶.

In our case series, we had a mortality of 7 (36.84%) of 19 cases. Our results are between those reported by Abdollahi et al. with 26.6% of 15 cases²⁶ and Jayalakshmi et al. with 47.4% in a series of 46 patients²⁴.

Talmí Y. et al. established a staging of rhino-orbito-cerebral mucormycosis associating this with mortality: Stage I - rhinosinusal disease localized only in the nose with minimal tissue invasion, with 100% survival rate; Stage II - disease limited to the nose, ipsilateral sinuses and orbit, with 80% survival rate; Stage III - disease involving intracranial structures with intact or limited impaired cognition, with 67% survival rate; Stage IV - disease involving intracranial structures with unconsciousness or hemiplegia, bilateral disease, skin necrosis, palatal involvement, with 0% survival rate²⁷.

Within Yoav Talmi's classification, the varieties were more or less homogeneous represented in the present study where the rhino-orbital involvement was the most common with 7 cases (36.84%), followed by the rhino-orbito-cerebral with 6 cases (31.58%) and rhinosinusal with 6 cases (31.58%)²⁷. These findings are a little different from those reported by Mallis et al.¹² and Upender et al.²⁸ who described the rhino-orbito-cerebral as the most common, but similar to what Abdollahi et al. reported (rhino-orbital as the most common with 13 (86.7%))²⁶.

Among the associated diseases, type 2 Diabetes Mellitus continues to be the main predisposing disease, similar to that reported in the literature^{12,22,25}.

In the literature, there are several studies stating the role of C-reactive protein and erythrocyte sedimentation level as a positive association with acute inflammatory processes and prognostic. Performing the comparison of C-reactive protein (CRP) between the deceased and the survivors, we found a value $p = 0.01684$, where the lower the CRP elevation the greater the chance of survival. Our results are similar to those reported by Cho et al. in a series of 45 patients²⁹. According to them, associating more than 55.0 mg/L CRP with this event is an independent factor for poor prognosis. CRP levels and erythrocyte sedimentation rate (ESR) are non-specific but commonly used laboratory markers of the systemic inflammatory response. When comparing the erythrocyte sedimentation rate (ESR) between the two groups, we found no significant difference with a value of $p = 0.11642$, in the same way some authors relate it as a monitor of response to treatment³⁰.

It is noted in the literature that some of the traditional risk factors include long-term neutropenia³¹. In our series of cases, the cases of death presented drops in the absolute neutrophil count, however, they did not fall within the neutropenic

range. Cho et al.²⁹ reported higher mortality in cases of severe neutropenia, similar to that found in our study, with only a reduction in the absolute neutrophil count, without falling into significant neutropenia.

When using odds ratios to assess the risk among patients with bone lysis in the tomography findings, it was found that those without lytic lesions had an odd ratio of 0.17 compared to those with lytic bone lesions in the imaging study with an odd ratio equal to 6. Authors such as McCarthy, who describes a series of neurological patients with fungal pathology, report that the surviving patients had an encapsulated and easily resectable lesion on CT or MRI, while those who died had a less circumscribed lesion; however, he indicates that bone erosion is not a sensitive marker of extension to the brain³².

Jung indicates that the destructive lesions observed in imaging studies can give us additional information, but the diagnosis of rhino-cerebral mucormycosis cannot be ruled out even with a negative imaging study³³.

Skull base osteomyelitis and bone involvement due to sinonasal mucormycosis is usually absent despite the deep extension of the disease and, when present, occurs at the last stage of the course of advanced disease^{34,35}. Considering all the above, we can relate it to an advanced degree disease, however, we did not find studies that related it to mortality.

When dividing the patients into two groups, based on location, in rhino-orbital mucormycosis (ROM) and rhino-cerebral mucormycosis (RCM), it was evidenced that patients with ROM had a longer survival rate (odd ratio = 0.44) compared to those with RCM (odd ratio = 2.25). Our results are similar to those of Yoav Talmi²⁷, who points this out in his staging.

When comparing survival among patients with ocular exenteration, the cases with exenteration had lower survival (OR = 4), in comparison without the exenterates (OR = 0.25), possibly due to the fact that the exenterated patients had greater progression in the disease (P = 0, 0468)³⁶. On the other hand, Kashkoui et al. describe that exenteration did not affect the survival of patients in a series of cases³⁷. Authors such as Badea⁸ report on their experience on cases of mucormycosis with orbital extension treated successfully without orbital exenteration.

CONCLUSIONS

Our series presented mortality close to 40%. Age <64 years, CRP \leq 23.1mm / L, absolute neutrophil

count \geq 13.2 1000 / μ l and absence of bone erosion in the simple tomography, rhino-orbital stage were associated with a better survival in our series.

Our study has its limitations. It is a retrospective study design with a small population, which provides us with limitations to forcefully generalize our results.

Conflict of interest: All authors declare that there are no conflicts of interest in this work.

Contribution of authors: All authors have equally contributed to this work.

Acknowledgments: We want to thank the Mexican Institute of Social Security, the Hospital de Especialidades No 2, our nurses who constantly support us in caring for patients, mainly: Karla and Aracely.

REFERENCES

1. Rammaert B, Lanternier F, Poirée S, Kania R, Lortholary O. Diabetes and mucormycosis: A complex interplay. *Diabetes Metab.* 2012;38(3):193-204. DOI: 10.1016/j.diabet.2012.01.002.
2. deShazo RD, O'Brien M, Chapin K, Soto-Aguilar M, Gardner L, Swain R. A new classification and diagnostic criteria for invasive fungal sinusitis. *Arch Otolaryngol Head Neck Surg.* 1997;123(11):1181-8. DOI: 10.1001/archotol.1997.01900110031005.
3. Ferguson BJ. Mucormycosis of the nose and paranasal sinuses. *Otolaryngol Clin North Am.* 2000;33(2):349-65. DOI: 10.1016/s0030-6665(00)80010-9.
4. Blitzer A, Lawson W, MEYERS BR, Biller HF. Patent survival factor in paranasal sinus mucormycosis. *Laryngoscope.* 1980;90(4):635-48. DOI: 10.1288/00005537-198004000-00010.
5. Petrikos G, Skiada A, Lortholary O, Roilides E, Walsh TJ, Kontoyannis DP. Epidemiology and clinical manifestations of mucormycosis. *Clin Infect Dis.* 2012;54 Suppl 1:S23-34. DOI: 10.1093/cid/cir866.
6. Sohail MA, Al Khabori M, Hyder J, Verma A. Acute fulminant fungal sinusitis: clinical presentation, radiological findings and treatment. *Acta Trop.* 2001;80(2):177-85. DOI: 10.1016/s0001-706x(01)00174-7.
7. Meas T, Mouly S, Kania R, Hervé D, Herman P, Kévorkian JP, et al. Zygomycosis: an uncommon cause for peripheral facial palsy in diabetes. *Diabetes Metab.* 2007;33(3):227-9. DOI: 10.1016/j.diabet.2006.12.001. Epub 2007 Mar 27.
8. Badea C, Sarafoleanu C, Marza A. Rhinosinusal mucormycosis: Literature review and some particular cases. *Romanian Journal of Rhinology.* 2019;9(35):129-37. DOI: 10.2478/rjr-2019-0015.
9. Hosseini SMS, Borghei P. Rhinocerebral mucormycosis: pathways of spread. *Eur Arch Otorhinolaryngol.* 2005;262(11):932-8. DOI: 10.1007/s00405-005-0919-0. Epub 2005 May 13.
10. Wiatrak BJ, Willging P, Myer CM 3rd, Cotton RT. Functional endoscopic sinus surgery in the immunocompromised child. *Otolaryngol Head Neck Surg.* 1991;105(6):818-25. DOI: 10.1177/019459989110500608.
11. Walsh TJ, Skiada A, Cornely OA, Roilides E, Ibrahim A, Zaoutis T, et al. Development of new strategies for early diagnosis of mucormycosis from bench to bedside. *Mycoses.* 2014;57(s3):2-7. DOI: 10.1111/myc.12249.
12. Mallis A, Mastronikolis SN, Naxakis SS, Papadas AT. Rhinocerebral mucormycosis: an update. *Eur Rev Med Pharmacol Sci.* 2010;14(11):987-92.

13. Nithyanandam S, Jacob MS, Battu RR, Thomas RK, Correa MA, D'Souza O. Rhino-orbito-cerebral mucormycosis. A retrospective analysis of clinical features and treatment outcomes. *Indian J Ophthalmol.* 2003;51(3):231-6.
14. Ramírez C, Hernández AF, Méndez V, Trejo S, Contreras R, Espinosa Monteros AL, et al. Mucormycosis en un paciente con agranulocitosis secundaria a metimazol. Informe de un caso. *Gac Med Mex.* 2009;145(3):235-8.
15. García Insausti C, Majado Martínez MJ, García Hernández AM, Morales Jiménez JM. Protocolo diagnóstico de la neutropenia. *Med.* 2012;11(21):1309-12. DOI: 10.1016/S0304-5412(12)70454-7.
16. Frey Gutiérrez ME, Martínez GW, Alvarez Milán D, Acuña Vassallo JP, Trinajstić EM. Mucormycosis cutánea-presentación de caso clínico, recuerdo de etiopatogenia diagnóstico y tratamiento. *Rev la Fac Ciencias Médicas.* 2016;73(4):302-5. DOI: 10.31053/1853.0605.v73.n4.15687.
17. Ali A, Abbasi AS, Amjad T, Saleem F. Erythrocyte Sedimentation Rate and C-Reactive Protein as marker of acute versus chronic medical conditions. *J Ayub Med Coll Abbottabad.* 2019;31(1):39-45.
18. Wu D, Zhang LM, Jiang Y. Clinical features of mucormycosis. *Acta Acad Med Sin.* 2010;32(4):461-4.
19. Méndez-Tovar LJ, Mejía-Mercado JA, Manzano-Gayosso P, Hernández-Hernández F, López-Martínez R, Silva GI. Frecuencia de micosis invasivas en un hospital mexicano de alta especialidad. Experiencia de 21 años. *Rev Med Inst Mex Seguro Soc.* 2016;54(5):581-7.
20. Park G, Song SY, Ahn JH, Kim WL, Lee JS, Jeong SY, et al. The pretreatment erythrocyte sedimentation rate predicts survival outcomes after surgery and adjuvant radiotherapy for extremity soft tissue sarcoma. *Radiat Oncol.* 2019;14(1):116. DOI: 10.1186/s13014-019-1331-z.
21. Rees JR, Pinner RW, Hajjeh RA, Brandt ME, Reingold AL. The epidemiological features of invasive mycotic infections in the San Francisco bay area, 1992-1993: results of population-based laboratory active surveillance. *Clin Infect Dis.* 1998;27(5):1138-47.
22. Jiang N, Zhao G, Yang S, Lin J, Hu L, Che C, et al. A retrospective analysis of eleven cases of invasive rhino-orbito-cerebral mucormycosis presented with orbital apex syndrome initially. *BMC Ophthalmol.* 2016;16:10. DOI: 10.1186/s12886-016-0189-1.
23. Jeong W, Keighley C, Wolfe R, Lee WL, Slavin MA, Kong DCM, et al. The epidemiology and clinical manifestations of mucormycosis: a systematic review and meta-analysis of case reports. *Clin Microbiol Infect.* 2019;25(1):26-34. DOI: 10.1016/j.cmi.2018.07.011.
24. Jayalakshmi SS, Reddy RG, Borgohain R, Subramanyam C, Panigrahi M, Sundaram C, et al. Predictors of mortality in rhinocerebral mycosis. *Neurol India.* 2007;55(3):292-7. DOI: 10.4103/0028-3886.35692.
25. Corzo-León DE, Chora-Hernández LD, Rodríguez-Zulueta AP, Walsh TJ. Diabetes mellitus as the major risk factor for mucormycosis in Mexico: Epidemiology, diagnosis, and outcomes of reported cases. *Med Mycol.* 2018;56(1):29-43. DOI: 10.1093/mmy/myx017.
26. Abdollahi A, Shokohi T, Amirrajab N, Poormosa R, Kasiri A, Motahari SJ, et al. Clinical features, diagnosis, and outcomes of rhino-orbito-cerebral mucormycosis: A retrospective analysis. *Curr Med Mycol.* 2016;2(4):15-23. DOI: 10.18869/acadpub.cmm.2.4.15.
27. Talmi YP, Goldschmied-Reouven A, Bakon M, Barshack I, Wolf M, Horowitz Z, et al. Rhino-orbital and rhino-orbito-cerebral mucormycosis. *Otolaryngol Head Neck Surg.* 2002;127(1):22-31. DOI: 10.1067/mhn.2002.126587.
28. Wali U, Balkhair A, Al-Mujaini A. Cerebro-rhino orbital mucormycosis: An update. *J Infect Public Health.* 2012;5(2):116-26. DOI: 10.1016/j.jiph.2012.01.003.
29. Cho HJ, Jang MS, Hong SD, Chung SK, Kim HY, Dhong HJ. Prognostic factors for survival in patients with acute invasive fungal rhinosinusitis. *Am J Rhinol Allergy.* 2015;29(1):48-53. DOI: 10.2500/ajra.2015.29.4115.
30. Millon L, Herbrecht R, Grenouillet F, Morio F, Alanio A, Letscher-Bru V, et al. Early diagnosis and monitoring of mucormycosis by detection of circulating DNA in serum: retrospective analysis of 44 cases collected through the French Surveillance Network of Invasive Fungal Infections (RESSIF). *Clin Microbiol Infect.* 2016;22(9):810.e1-810.e8. DOI: 10.1016/j.cmi.2015.12.006.
31. Sun HY, Singh N. Mucormycosis: its contemporary face and management strategies. *Lancet Infect Dis.* 2011;11(4):301-11. DOI: 10.1016/S1473-3099(10)70316-9.
32. McCarthy M, Rosengart A, Schuetz AN, Kontoyiannis DP, Walsh TJ. Mold infections of the central nervous system. *N Engl J Med.* 2014;371(2):150-160. DOI: 10.1056/NEJMra1216008.
33. Jung SH, Kim SW, Park CS, Song CE, Cho JH, Lee JH, et al. Rhinocerebral Mucormycosis: consideration of prognostic factors and treatment modality. *Auris Nasus Larynx.* 2009;36(3):274-9. DOI: 10.1016/j.anl.2008.07.003. Epub 2008 Sep 10.
34. Chan LL, Singh S, Jones D, Diaz EM, Ginsberg LE. Imaging of mucormycosis skull base osteomyelitis. *AJNR Am J Neuroradiol.* 2000;21(5):828-31.
35. Gamba JL, Woodruff WW, Djang WT, Yeates AE. Craniofacial mucormycosis: assessment with CT. *Radiology.* 1986;160(1):207-12. DOI: 10.1148/radiology.160.1.3715034.
36. Hargrove RN, Wesley RE, Klippenstein KA, Fleming JC, Haik BG. Indications for orbital exenteration in mucormycosis. *Ophthalmic Plast Reconstr Surg.* 2006;22(4):286-91. DOI: 10.1097/01.iop.0000225418.50441.1e.
37. Kashkouli MB, Abdolalizadeh P, Oghazian M, Hadi Y, Karimi N, Ghazizadeh M. Outcomes and factors affecting them in patients with rhino-orbito-cerebral mucormycosis. *Br J Ophthalmol.* 2019;103(10):1460-5. DOI: 10.1136/bjophthalmol-2018-312688.

