

ORIGINAL STUDY

Foreign body of endodontic origin in the maxillary sinus

Mihai Preda^{1,2} , Codrut Sarafoleanu^{1,2,3} 

¹“Carol Davila” University of Medicine and Pharmacy, Bucharest, Romania

²ENT&HNS Department, “Sfanta Maria” Hospital, Bucharest, Romania

³Center of excellence for research of sensorial and sensitive disorders, study of infecto-inflammatory, tumoral and obstructive aero-digestive pathology, ENT&HNS Department, “Sfanta Maria” Hospital, Bucharest, Romania

ABSTRACT

Displacement of foreign bodies into the maxillary sinus is still a rare pathology, but the incidence is increasing continuously with the development of dental procedures. Most cases of foreign bodies are associated with dental procedures. These can be of varying natures, such as dental implants, fractured teeth roots, endodontic materials and tools, dental burs, dental impression materials or dental fillings materials. Less frequent are the foreign bodies of non-dental origin, which are related to facial injuries in accidents or assaults. The diagnosis is based on careful clinical and radiological examinations. Foreign bodies should be diagnosed and treated on time in order to prevent complications, mainly acute or chronic rhinosinusitis.

In this article, we review the main characteristics regarding the incidence, etiology, diagnosis and treatment options – endoscopic and an external approach for the removal of a displaced foreign body into the maxillary sinus. Also, we present our personal experience and treatment options, highlighting the importance of pre-operative evaluation, proper imaging assessment, adequate access and visibility and adequate surgical technique, in order to prevent later sinonasal infectious complications.

KEYWORDS: dental procedures, foreign body, maxillary sinus, endoscopic surgery, Caldwell-Luc.

INTRODUCTION

In the recent years, the development of dental procedures has brought a lot of benefits in the treatment and quality of life for patients, but has also led to an increase in the number of sinonasal complications. Paranasal sinuses foreign bodies are a rare pathology, but with a growing incidence. Generally, females are more frequently affected than men (57.7% versus 42.82%)¹.

Although foreign bodies found in other parts of the body can cause significant symptoms, foreign bodies displaced into the maxillary sinus can remain asymptomatic for a long period of time. Despite this characteristic of signs and symptoms evolution, it is recommended to remove them in order to avoid potential complications².

In the literature, various surgical procedures

are described for the removal of a foreign body from the maxillary sinus. Among the different methods, there are two treatment modalities proposed both to remove the foreign body and to treat the associated complications (if these exists): the transnasal approach with functional endoscopic sinus surgery (FESS) and an intraoral approach, through the anterior maxillary wall. In selected cases, these two modalities can be combined³⁻⁵.

The purpose of this paper is to raise awareness upon the increasing incidence of the maxillary sinus foreign bodies with endodontic origin by summarising the diagnosing and treatment methods and presenting some cases of foreign bodies displaced into the maxillary sinus, surgically treated in our Department. The aim is to highlight the importance of pre-operative evaluation, proper

Corresponding author: Mihai Preda, MD, ENT & HNS Department “Sfanta Maria” Hospital, 37-39 Ion Mihalache Blvd., District 1, Bucharest, Romania

ORCID: <https://orcid.org/0000-0003-0172-5962>

e-mail: mihai_2201@yahoo.com

Received for publication: March 18, 2021 / **Accepted:** April 23, 2021

imaging assessment, adequate access and visibility and proper surgical technique, in order to prevent later sinonasal infectious complications.

INCIDENCE AND ETIOPATHOGENESIS

The most common etiology of intrasinus foreign bodies is iatrogenic in more than 60% of cases (dental, otorhinolaryngologic and ophthalmic procedures) or accidental in 25% of cases. The most commonly involved is the maxillary sinus (75%), followed by the frontal sinus (18%)^{6,7}. Depending on the affected tooth, the most commonly involved is the first molar (22.51%), followed by the second molar (17.21%), the second premolar (2.2%) and the canines in 0.66% of cases.

A poor knowledge of the anatomy of the alveolar and antral regions, an insufficient imaging preparation of the patient and the physician's superficiality can lead to mistakes during the dental procedures. The anatomical features of the maxillary sinus, such as antrum pneumatization, roots length or alveolar process, width, increase the risk of complications in this area during dental manipulation. Also, the anatomical proximity of the maxillary antrum with the roots of the maxillary molars, premolars and, in some cases, canines, increase the risk of many complications in this area. Determinant factors that may influence the penetration of foreign bodies into the maxillary sinus during dental procedures are severe atrophy of the maxillary bone, poor anatomical structure of the area, bone resorptions and changes in the sinus pressure⁸.

The most frequent cause of the foreign bodies found in the maxillary sinus are associated with iatrogenic dental manipulation⁹. These can be of varying natures such as dental implants, fractured teeth roots, endodontic materials and tools^{10,11}, dental burs¹², dental impression materials¹³, dental fillings materials (e.g. amalgam)^{14,15}. Less frequent are the foreign bodies of non-dental origin, which are related to facial injuries such as those from car accidents or assaults. In the latter case, the foreign bodies are directly introduced into the maxillary through an open wound and may be represented by gunshot pellets, pieces of glass, bullets, wooden sticks, penetrating metal bodies, such as metal door handle, sewing needle or knife¹⁶.

It is difficult to accurately estimate the incidence of odontogenic foreign bodies, firstly because of the rarity of this pathology, and secondly because of the lack of published research findings. According to a three-year prospective study performed in our clinic with results published in 2015, the most common foreign body encoun-

tered in the maxillary sinus were dental implants (38.77%) followed by dental fillings materials (28.57%), gutta-percha (10.20%), pieces of gauze used for nasal or sinus packing (8.16%), tooth fragments (6.12%), dental burr (4.08%) and Kerr needles (4.08%)¹⁰.

DIAGNOSIS AND THERAPEUTIC STRATEGY OF MAXILLARY SINUS FOREIGN BODY

Detailed medical history, ENT examination and imaging investigations (panoramic radiography, plain X-rays, CBCT, CT) are important in establishing the correct diagnosis and treatment in order to prevent rhinosinus complications.

The presence of a maxillary sinus foreign body should be suspected in case of a unilateral chronic maxillary rhinosinusitis resistant to medical treatment and a history of dental manipulation.

Foreign bodies are generally detected only when a patient presents sign and symptoms of chronic rhinosinusitis, or the discovery is purely incidental during a radiological examination. Common symptoms, if present, are pain or discomfort during palpation of the maxillary sinus area, headache, nasal discharge, nasal obstruction or stuffiness. A unilateral fetid mucopurulent nasal discharge is the most common symptom in patients with sinonasal foreign bodies¹⁷.

Radiological investigations are important tools in establishing the correct diagnosis of foreign bodies of paranasal sinuses. Panoramic radiographic examination together with plain sinus X-rays taken in Water's view are some of the most widely used imaging techniques for verifying the location of displaced elements in the maxillary sinus¹⁸. A more precise examination is the cone-beam computed tomography (CBCT) which requires a lower radiation dose and which has been proven to be an important tool to assist dentists in diagnosing the presence of a foreign body in the maxillary antrum⁸. Computed tomography (CT), in axial and coronal views, is the gold standard for adequate paranasal sinus imaging to determine the presence of any foreign body and rhinosinusitis¹⁹. Magnetic resonance imaging (MRI) can also be useful to identify an organic foreign body, being superior to CT scan for soft tissue evaluation, but it is essential to be sure that metallic foreign bodies are not magnetic (danger of shifting)¹⁸.

According to Mladina²⁰, a foreign body displaced into the maxillary sinus should always be removed, even in asymptomatic cases, in order to avoid sinonasal complications, mainly acute or

chronic rhinosinusitis or even malignancy. The pathophysiological mechanism of how foreign bodies can cause sinonasal complications is still unclear. It is believed that size, weight and chemical composition of the foreign body produce a chronic irritation of the sinus mucosa, causing ciliary insufficiency, ostial blockage, improper drainage and stagnation of sinus secretions. Stagnant endosinusal secretions stimulate the anaerobic environment and development of endosinusal germs such as bacteria or fungi leading to secondary infections^{21,22}.

It has been demonstrated that perforation of the sinus membrane during dental procedures can cause a massive fungal inoculation of the maxillary antrum¹⁴. Along with that, dental materials displaced into the maxillary antrum during dental procedures that contain heavy metals (e.g. zinc, titanium, salts of calcium, barium, sulfur, bismuth) such as gutta-percha, silver cones, root canal sealer and amalgam can provide favourable conditions for fungal growth, especially of *Aspergillus* and mycetoma formation^{23,24}. Although eugenol in dental materials has an antifungal effect, Mensi et al.²⁵ demonstrated that eugenol gradually loses its inhibitory function enabling heavy metals to promote fungal growth. From a clinical point of view, aspergillosis of the maxillary antrum caused by the presence of a foreign body is undiagnosed in early phases, because the patient becomes symptomatic after a long period of fungal proliferation or in case of bacterial superinfection that may cause acute rhinosinusitis episodes.

Removal of a paranasal foreign body can be challenging, especially for an unexperienced surgeon. Depending on the size, location, complications, relation to adjacent structures and the surgeon's preference, there are several methods which can be used to remove a foreign body: endoscopic endonasal surgery, external approach or a combined technique. Small foreign bodies can be spontaneously expelled, but in most cases, they require removal. Sometimes it is possible that the foreign body may be transported by cilia of the sinus mucosa to the natural ostium and finally even in the nose. In the past decades, the endoscopic sinus surgery (ESS) has been replacing the radical Caldwell-Luc technique in the treatment of maxillary sinus pathology. It has the advantages of being less invasive and non-traumatic, with decreased morbidity, decreased risk of tooth root injury, allows full visualization of the maxillary sinus, short recovery time and little or no risk of injury to the infraorbital nerve. This method is more suitable for the removal of foreign bodies located anteriorly in the maxillary sinus^{12,26,27}. Re-

gardless of its advantages, endoscopic surgery is not effective in removing larger foreign bodies or those located posteriorly or inferiorly. In these cases, the Caldwell-Luc technique is more suitable. Nevertheless, depending on the location and nature of the foreign body, a Caldwell-Luc approach combined with ESS can be used in order to remove all the fragments²⁸. The proper treatment plan has to take into consideration three other details: the presence of an oroantral fistula, the ostium permeability and the inflammatory damage of the sinus mucosa^{29,30}.

OUR EXPERIENCE

To illustrate and emphasize the presented aspects and to highlight the importance of a correct pre-operative evaluation, proper imaging assessment, adequate access and visibility and proper surgical technique, we detail two cases.

The first patient, a 38-year-old female, referred to our ENT Department with complaints of headache, right nasal obstruction, right nasal discharge and postnasal drip for approximately two years. She received antimicrobial therapy for rhinosinusitis four times, but the symptomatology persisted. She had a history of root canal therapy (three years prior) and she had no history of surgery for nasal or sinus pathology.

The ENT examination revealed hypertrophy of the inferior turbinates, purulent and fetid secretions on the right nostril. Doing the nasal endoscopy, we observed edema of mucosa in the right middle meatus, purulent secretion draining from the maxillary sinus through the right middle meatus and into the nasopharynx (Figure 1a).

Due to the characteristics of the disease (unilateral and resistant to medical therapy), a craniofacial CT scan was performed. The imaging examination revealed a soft tissue dense opacity in the right maxillary sinus and an oval metal-dense structure in the proximity of the sinus ostium. Considering the root canal therapy performed in the recent history, we considered that the oval structure may represent an extruded root filler (Figure 1b).

Endoscopic surgery was planned in order to remove the foreign body. The patient was informed about both the benefits and the possible risks of the procedure. Under general anaesthesia, we performed a right middle meatal antrostomy. Intraoperatively, we observed the sinus cavity filled with purulent secretions and a brownish mass in the proximity of the maxillary sinus ostium, which was removed by saline irrigation and

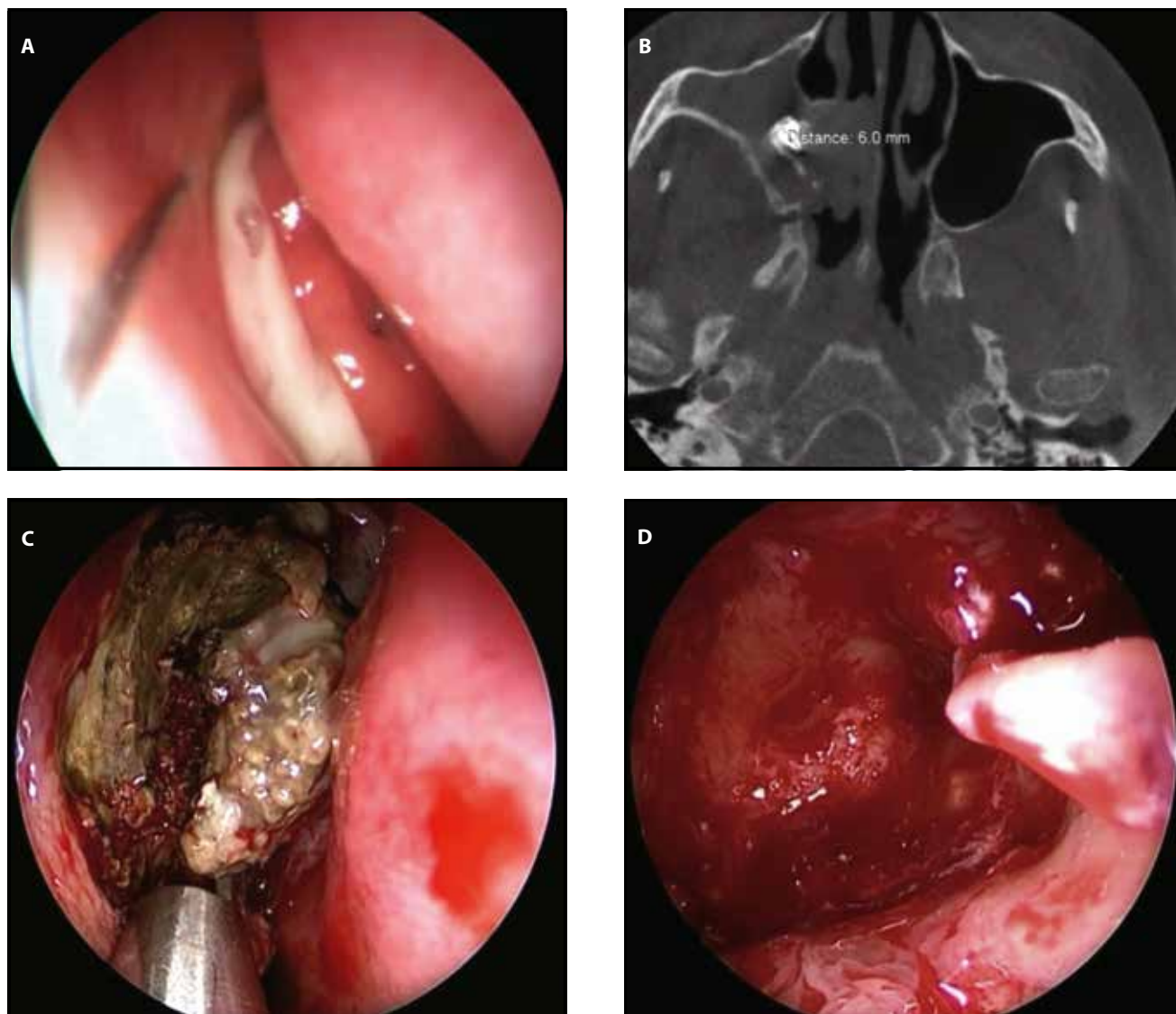


Figure 1. **A** Nasal endoscopy showing edema and purulent secretions in the right middle meatus. **B** Axial cranio-facial CT scan - radiopaque foreign body in the right maxillary sinus (filling material) covered by fungal material, located close to the ostium of the maxillary sinus. **C** Intraoperative view: after saline irrigation, a small brownish mass is observed in the area of the maxillary sinus. **D** Intraoperative view of the maxillary sinus at the end of the surgery.

suctioning (Figure 1c). Then, a 70° endoscope allowed us to visualize inside the maxillary sinus. There was no evidence of residual foreign body at the end of the surgery (Figure 1d). The endoscopic surgery and the histopathologic findings showed a right maxillary fungal rhinosinusitis with a foreign body attached (a root canal filling material - dental paste).

The postoperative evolution was favourable, and the patient experienced no complications. At the first-year follow-up, the ENT examination and radiological investigations were normal.

Another example is the case of a 34-year-old male patient, who referred to our ENT Department on the recommendation of his dentist. The patient described that he had a tooth extraction

(the second molar) nearly 1 week ago. He also described the procedure as being complicated, the extracted tooth being fractured into several pieces during the dental manipulation. His general dental practitioner informed him about the intraoperative accident and the possibility of a tooth fragment displacement into the sinus cavity. The patient received antibiotic, anti-inflammatory and nasal decongestant treatment. The panoramic radiographic examination performed after the medical treatment confirmed the apparent presence of a tooth root inside the right maxillary sinus (Figure 2a).

The therapeutic possibilities were discussed with the patient and the removal of the foreign body was performed under general anaesthesia by a di-

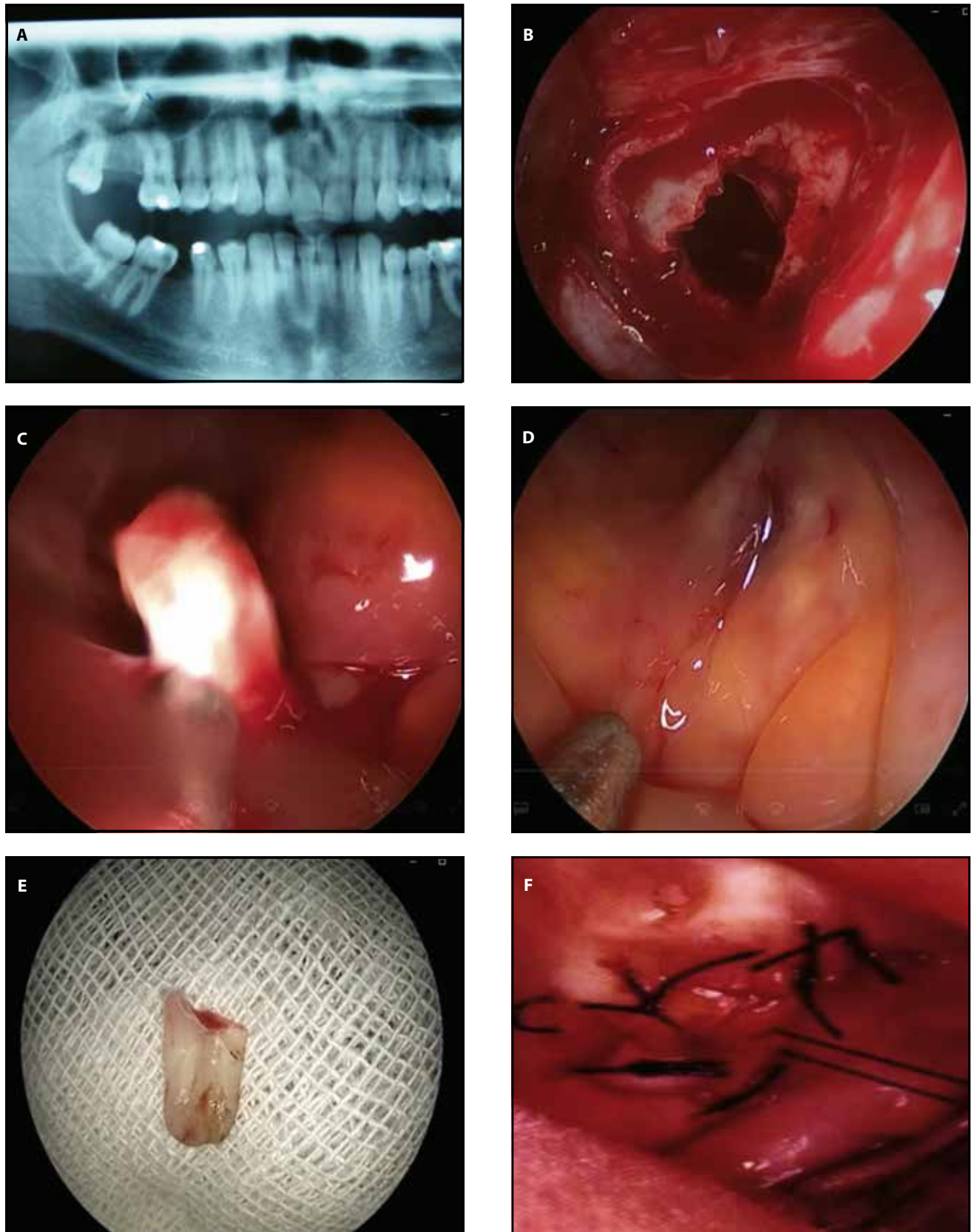


Figure 2. A Preoperative panoramic radiography demonstrates a tooth root fragment migrated into the maxillary sinus; B Surgical approach with a Caldwell-Luc procedure; C Removal of the foreign body; D Endoscopic view after removal of the foreign body; E Foreign body in detail; F Wound closure through suture.

rect open approach by creating a bone window flap through the anterior wall of the maxillary antrum. The intraoral approach showed the presence of the tooth fragment in the alveolar recess; it was removed by negative pressure of the suction pump (Figure 2b, 2c). The most astonishing event was the aggressive inflammatory reaction of the sinus mucosa despite the medical treatment, the only method of treatment being the removal of the foreign body. The patient's immediate and long-term recovery was uneventful, with no subjective and objective signs of infraorbital nerve injury.

These cases emphasize the potential impact that an involved maxillary sinus may have on endodontic therapy. The patients should always be informed previously about the risks of potential complications that may occur during the procedure. The best way to prevent penetration of a foreign body into the maxillary sinus during dental procedures is a careful preoperative evaluation even during a relatively non-invasive treatment.

CONCLUSIONS

The intrusion of a foreign body into the maxillary sinus should be considered in case of a unilateral chronic maxillary rhinosinusitis resistant to medical treatment and with a history of dental manipulation. Radiologic imaging, especially computed tomography, plays a major role in the diagnosis and treatment of this pathology. The treatment consists in the surgical removal of the foreign body, even if the patients are asymptomatic, because they can produce inflammatory and infectious rhinosinusitis, such as bacterial or fungal rhinosinusitis, or even abscesses of the surrounding structures. In the recent years, endoscopic surgical techniques have replaced the classic open approach, being preferred by most of surgeons and patients.

Conflict of interest: All authors declare that there are no conflicts of interest.

Contribution of authors: All authors have equally contributed to this work.

Funding statement: None.

REFERENCES

- Omezli MM, Torul D, Sivrikaya EC. The prevalence of foreign bodies in jaw bones on panoramic radiography. *Indian J Dent.* 2015;6(4):185-9. DOI: 10.4103/0975-962X.170371.
- Kobayashi A. Asymptomatic aspergillosis of the maxillary sinus associated with foreign body of endodontic origin. Report of a case. *Int J Oral Maxillofac Surg.* 1995;24(3):243-4. DOI: 10.1016/s0901-5027(06)80138-4.
- Wojtera B, Wozna A, Komisaruk O. The management of foreign body displacement into the maxillary sinus as a complication of maxillofacial interventions: systematic review. *Indian J Otolaryngol Head Neck Surg.* 2020. <https://doi.org/10.1007/s12070-020-02153-9>. Available from: <https://link.springer.com/article/10.1007%2Fs12070-020-02153-9>.
- Friedlich J, Rittenberg BN. Endoscopically assisted Caldwell-Luc procedure for removal of a foreign body from the maxillary sinus. *J Can Dent Assoc.* 2005;71(3):200-1.
- Agusti EB, Puiggros IV, Figuerola CR, Vecina M. Foreign bodies in maxillary sinus. *Acta Otorhinolaringol Esp.* 2009;60(3):190-3.
- Liston PN, Walters RF. Foreign bodies in the maxillary antrum: a case report. *Aust Dent J.* 2002;47(4):344-6. DOI: 10.1111/j.1834-7819.2002.tb00549.x.
- Nataraj RV, Jagade M, Chavan R, Kar R, Pandare M, Parelkar K, et al. An unusual maxillary sinus foreign body and its endoscopic assisted removal. *Int J Otolaryngol Head Neck Surg.* 2015;4(1):38-43. DOI: 10.4236/ijohns.2015.41007.
- Shao L, Qin X, Ma Y. Removal of maxillary sinus metallic foreign body like a hand sewing needle by magnetic iron. *Int J Clin Pediatr Dent.* 2014;7(1):61-4. DOI: 10.5005/jp-journals-10005-1237.
- Thevoz F, Arza A, Jaques B. Dental foreign body sinusitis. *Schweiz Med Wochenschr.* 2000;Suppl 125:30S-34S.
- Manea C, Sarafoleanu C. Iatrogenic foreign bodies in the maxillary sinus: between malpractice and medico-legal consequences. *Rom J Leg Med.* 2015;23(1):14-8. DOI: 10.4323/rjlm.2015.14.
- Tanasiewicz M, Bubilek-Bogacz A, Twardawa H, Skucha-Nowak M, Szklarski T. Foreign body of endodontic origin in the maxillary sinus. *J Dent Sci.* 2017;12(3):296-300. DOI: 10.1016/j.jds.2013.02.033.
- Smith JL, Emko P. Management of a maxillary sinus foreign body (dental bur). *Ear Nose Throat J.* 2007;86(11):677-8.
- Deniz Y, Zengin AZ, Karli R. An unusual foreign body in the maxillary sinus: Dental impression material. *Niger J Clin Pract.* 2016;19(2):298-300. DOI: 10.4103/1119-3077.164367.
- Burnham R, Bridle C. Aspergillosis of the maxillary sinus secondary to a foreign body (amalgam) in the maxillary antrum. *Br J Oral Maxillofac Surg.* 2009;47(4):313-5. DOI: 10.1016/j.bjoms.2009.01.015.
- Krishnan S, Sharma R. Iatrogenically induced foreign body of the maxillary sinus and its surgical management: a unique situation. *J Craniofac Surg.* 2013;24(3):e283-4. DOI: 10.1097/SCS.0b013e31828f2a5a.
- Agarwal S, Kumar S. Foreign bodies in maxillary sinus: Causes and management. *Astrocyte.* 2014;1(2):89-92.
- Werman HA. Removal of foreign bodies of the nose. *Emerg Med Clin North Am.* 1987;5(2):253-63.
- Macan D, Cabov T, Kobler P, Bumber Z. Inflammatory reaction to foreign body (amalgam) in the maxillary sinus misdiagnosed as an ethmoid tumor. *Dentomaxillofac Radiol.* 2006;35(4):303-6. DOI: 10.1259/dmfr/42499904.
- Brook I. Sinusitis of odontogenic origin. *Otolaryngol Head Neck Surg.* 2006;135(3):349-55.
- Mladina R. Endoscopic sinus surgery: a metallic foreign body at the sphenothmoidal junction. *J Laryngol Otol.* 1992;106(11):998-9. DOI: 10.1017/s0022215100121589.
- Stammberger H. Complications of inflammatory paranasal sinus diseases including iatrogenically-induced complications. *Eur Arch Otorhinolaryngol Suppl.* 1993;1:61-102.

22. Pagella F, Emanuelli E, Castelnuovo P. Endoscopic extraction of a metal foreign body from the maxillary sinus. *Laryngoscope*. 1999;109(2 Pt 1):339-42. DOI: 10.1097/00005537-199902000-00030.
23. Rode M, Podboj J, Kogoj-Rode M. Sinus maxillary mycetoma of odontogenic origin: case report. *Braz Dent J*. 2004;15(3):248-50.
24. Khongkhunthian P, Reichart PA. Aspergillosis of the maxillary sinus as a complication of overfilling root canal material into the sinus: report of two cases. *J Endod*. 2011;27(7):476-8. DOI: 10.1097/00004770-200107000-00011.
25. Mensi M, Piccioni M, Marsili F, Nicolai P, Sapelli PL, Latronico N. Risk of maxillary fungus ball in patients with endodontic treatment on maxillary teeth : a case-control study. *Oral Surg Oral Med Oral Pathol Oral Radiol Endod*. 2007;103(3):433-6. DOI:10.1016/j.tripleo.2006.08.014.
26. Costa F, Robiony M, Toro C, Sembronio S, Politi M. Endoscopically assisted procedure for removal of a foreignbody from the maxillary sinus and contemporary endodontic surgical treatment of the tooth. *Head Face Med*. 2006;2:37. DOI: 10.1186/1746-160X-2-37.
27. Chandrasema F, Singh A, Visavadia B. Removal of a root from the maxillary sinus using functional endoscopic sinus surgery. *Br J Oral Maxillofac Surg*. 2010;48(7):558-9. DOI: 10.1016/j.bjoms.2009.09.007.
28. Dodson KM, Bridges MA, Reiter ER. Endoscopic transnasal management of intracranial foreign bodies. *Arch Otolaryngol Head Neck Surg*. 2004;130(8):985-8. DOI: 10.1001/archotol.130.8.985.
29. Nemeč SF, Pelosček P, Koelblinger C, Mehraín S, Krestan CR, Czerny C. Sinonasal imaging after Caldwell-Luc surgery: MDCT findings of an abandoned procedure in time of functional endoscopic sinus surgery. *Eur J Radiol*. 2009;70(1):31-4. DOI: 10.1016/j.ejrad.2008.01.007.
30. Nakamura N, Mitsuyasu T, Ohishi M. Endoscopic removal of a dental implant displaced into the maxillary sinus: Technical note. *Int J Oral Maxillofac Surg*. 2004;33(2):195-7. DOI: 10.1054/ijom.2003.0470.

© 2021 Mihai Preda, Codrut Sarafoleanu, published by Romanian Rhinologic Society



This is an open access article published under the terms and conditions of the Creative Commons Attribution-NonCommercial-NoDerivatives 4.0 International (CC BY-NC-ND 4.0) License (<https://creativecommons.org/licenses/by-nc-nd/4.0/>). CC BY-NC-ND 4.0 license requires that reusers give credit to the creator by citing or quoting the original work. It allows reusers to copy, share, read, download, print, redistribute the material in any medium or format, or to link to the full texts of the articles, for non-commercial purposes only. If others remix, adapt, or build upon the material, they may not distribute the modified material.