

ORIGINAL STUDY

Anthropometric aspects used to treat fractures of the naso-orbito-ethmoido-maxillary (NOEM) complex in cases of facial trauma

Andrei Mihail Rosu¹, Daniela Sulea², Oana Cristina Rosu³, Mihail Dan Cobzeanu¹, Geanina Bandol¹, Liliana Gheorghe Moisiu⁴, Luiza Maria Cobzeanu⁴, Victor Vlad Costan², Dragos Octavian Palade¹, Bogdan Mihail Cobzeanu¹

¹Department of Otorhinolaryngology, “Grigore T. Popa” University of Medicine and Pharmacy, Iasi, Romania

²Department of Oro-Maxillo-Facial Surgery, “Grigore T. Popa” University of Medicine and Pharmacy, Iasi, Romania

³Department of Pneumology, Emergency Clinical County Hospital, Vaslui, Romania

⁴Department of Radiology and Imaging, “Grigore T. Popa” University of Medicine and Pharmacy, Iasi, Romania

ABSTRACT

BACKGROUND. Fractures of the naso-orbito-ethmoido-maxillary (NOEM) complex are frequently acquired post-traumatic lesions, with both aesthetic and functional consequences, if the diagnosis is not promptly established and the surgical correction is delayed.

OBJECTIVES. This study was conducted in order to facilitate the diagnosis of NOEM complex fractures by using anthropometric measures. The aim was to obtain normal mean values of the evaluated parameters from a lot of healthy volunteers.

MATERIAL AND METHODS. The measurements were conducted on patient-specific three-dimensional models obtained from processing the CT scan images and building further stereolithographic models. 64 Caucasian patients were enrolled, with ages between 19 and 93 years, both female and male volunteers, without previous surgical history of the middle floor of the face. Measurements were performed between certain craniometric points (Nasion, Dacryon, Infraorbital foramen, Rhinion and Frontomolare orbitale) and a database was created.

RESULTS. Although some expected variation arised, we have obtained normal-considered intervals for each of the defined and measured segments between the mentioned craniometric points. We find these measurements useful especially for elaborating a presurgical plan for the best outcome.

CONCLUSION. Simple measurements could orient a fast diagnosis, could help establish a surgical plan, an optimal surgical timing by combining clinical and imaging data.

KEYWORDS: fractures of the naso-orbito-ethmoido-maxillary (NOEM) complex, anthropometric measures, craniometric points.

INTRODUCTION

Fractures of the naso-orbito-ethmoido-maxillary (NOEM) complex are difficult to diagnose and manage due to the complex anatomy and fragility of the bone structures involved, with the medial canthal ligament being the most important soft tissue affected in these fractures. A good result requires early intervention, open reduction and internal fixation with the evaluation of the medial

canthal attachment and, when necessary, medial canthopexy, with other available procedures, if the optimal time for reconstruction is missed. Even though the naso-orbito-ethmoidal (NOE) complex and the maxilla are different anatomical entities, this study treats them as one due to the fact that clinically, NOE complex fractures are often associated with maxillary fractures.

This study aims to perform anthropometric measurements in the virtual environment, in order to

Corresponding author: Dr. Mihail Dan Cobzeanu, Professor, Department of Otorhinolaryngology, “Grigore T. Popa” University of Medicine and Pharmacy, 16 Universitatii Street, Iasi, Romania

ORCID: <https://orcid.org/0000-0003-3319-5564>

e-mail: cobzeanu_dan@yahoo.com

Received for publication: January 31, 2022 / **Accepted:** February 20, 2022

establish the normal values necessary for both the diagnosis and individualized treatment of NOEM complex fractures.

MATERIAL AND METHODS

Starting with 2018, within the ENT and OMF Surgery Clinic of the “Sfantul Spiridon” Emergency Clinical Hospital, Iasi, a study has started on the use of three-dimensional printing technology to make stereolithographic models.

To obtain patient-specific three-dimensional (3D) models, Digital Imaging and Communications in Medicine (DICOM) data from CT scans and cone beam computed tomography (CBCT) scans are exported using the DICOM Viewer program as a .STL file to a 3D modelling program. At this stage, care must be taken to preserve the original dimensions of the model. Artifacts from the scanning process are removed and, for trauma patients, reconstructive procedures can be applied, such as mirror modelling or individual repositioning of each bone fragment. This step of obtaining the 3D model requires anatomical knowledge as well as the skill to manipulate the model in 3D modelling software. Once this is done, either the original representation or the one obtained after applying the reconstruction procedures can be distributed electronically for review or sent to the 3D printer software, where it is converted into a file type that the printer can use. At this point, the printer settings, such as the support structure, fill degree and print resolution, are

entered. These settings, as well as the material to be used and the type of actual 3D printing process, dictate the time and amount of material required to obtain the model. The 3D replica can be modelled by an off-site person and sent to the printer by electronic means of communication.

To establish a starting point, an anthropometric study was performed based on the measurement of different craniometric points in a virtual environment on three-dimensional models of patients. These points were chosen to be easily observable and identifiable on both standard antero-posterior radiographs of the skull and anterior sinuses of the face.

The points chosen were:

- Nasion (N): the point located at the midline of the frontonasal suture.
- Dacryon (D:): point located at the suture between the anterior edge of the lacrimal bone and the frontal bone.
- Infraorbital foramen (IOF).
- Rhinion (Rhi): the lowest point located at the suture between the nasal bones.
- Frontomalare Orbitale (FMO): the point located at the level of the fronto-malar suture.

These dimensions can be used later to correlate with the measurements obtained in patients with traumatic pathology in the naso-orbito-ethmoido-maxillary complex, which will make diagnosing these lesions much easier and earlier.

At the same time, using the same algorithm for obtaining three-dimensional models, a faithful replica of a patient who suffered a fracture of the

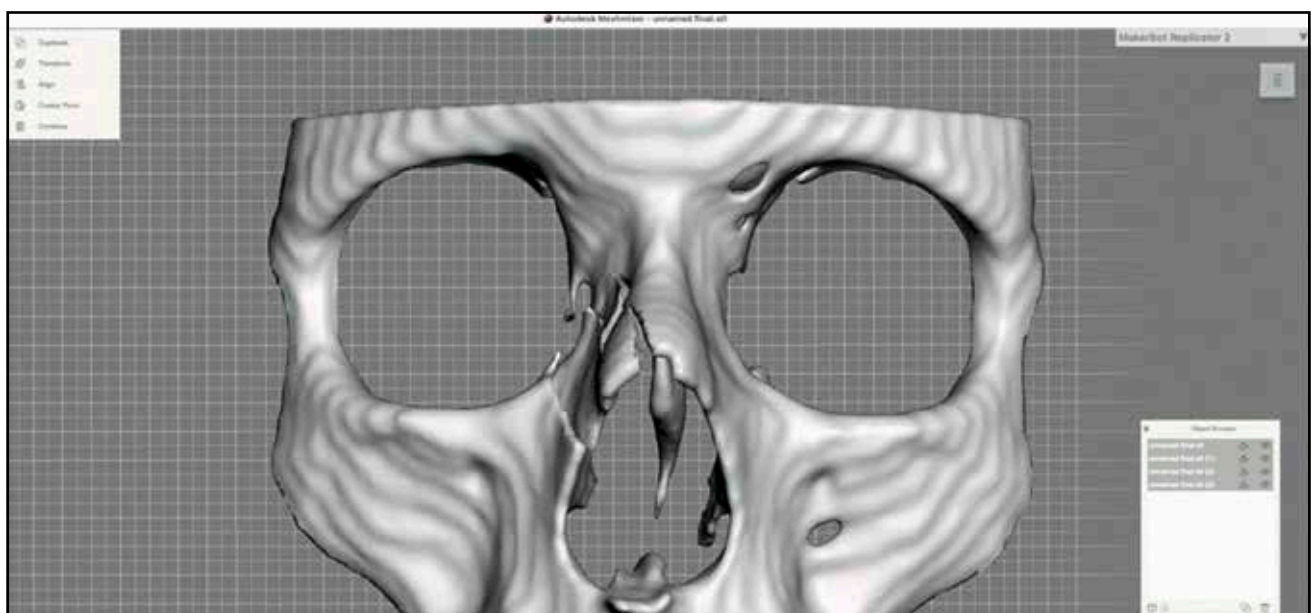


Figure 1. 3D model useful for teaching purpose.

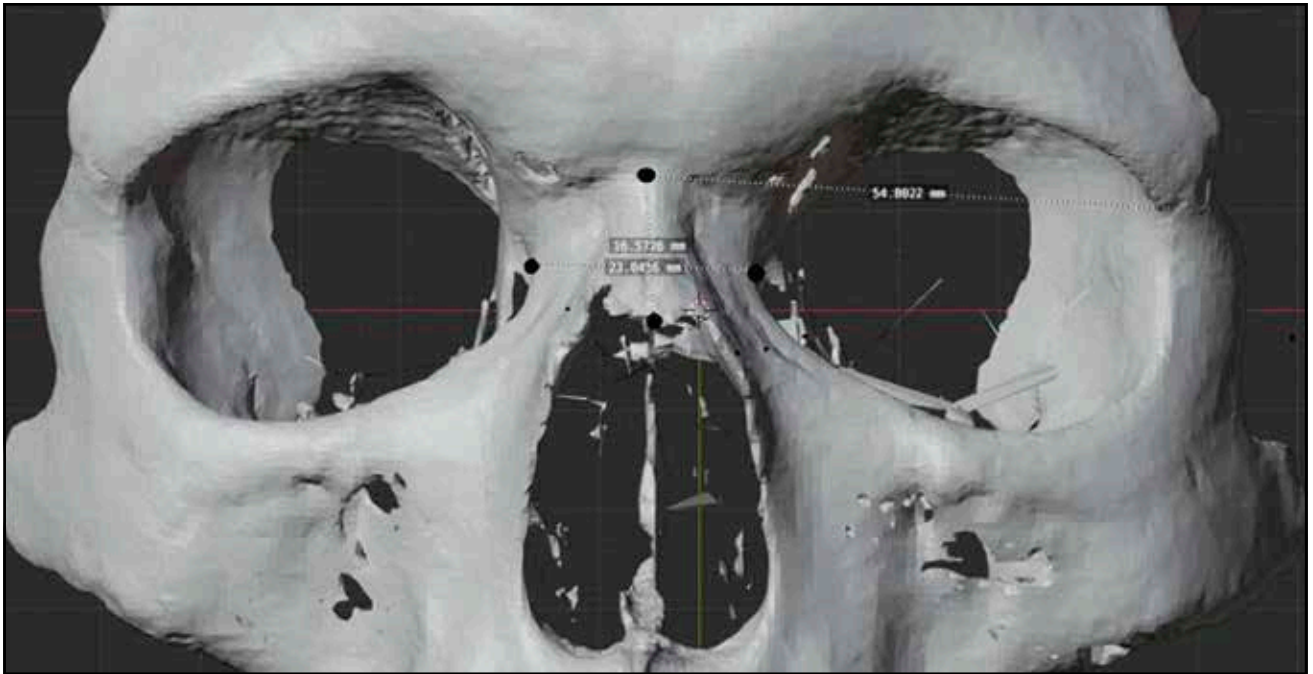


Figure 2. Measurements between: N-Rhi, D-D, N-FMO.

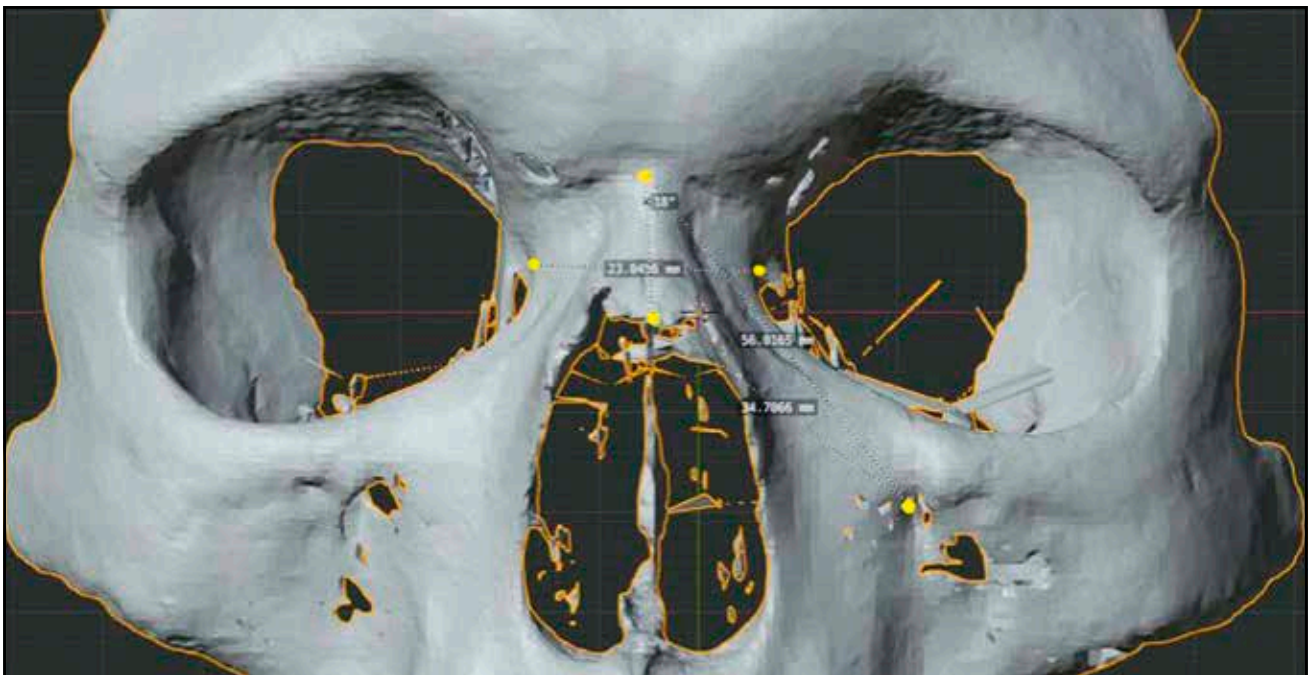


Figure 3. Measurements between: N-IOF, Rhi-IOF.

naso-orbito-ethmoid-maxillary complex was obtained (Figure 1), which is useful for both preoperative planning, presentation and explaining to the patient the pathology he suffers from as well as teaching material.

The study was performed with the informed consent of the patients as well as with the opinion of

the ethics commission of the “Sfantul Spiridon” Emergency Clinical Hospital, Iasi, and the “Grigore T. Popa” University of Medicine and Pharmacy, Iasi.

Patients who underwent a computed tomography (CT) or cone beam computed tomography (CBCT) examination, adults (men and women)

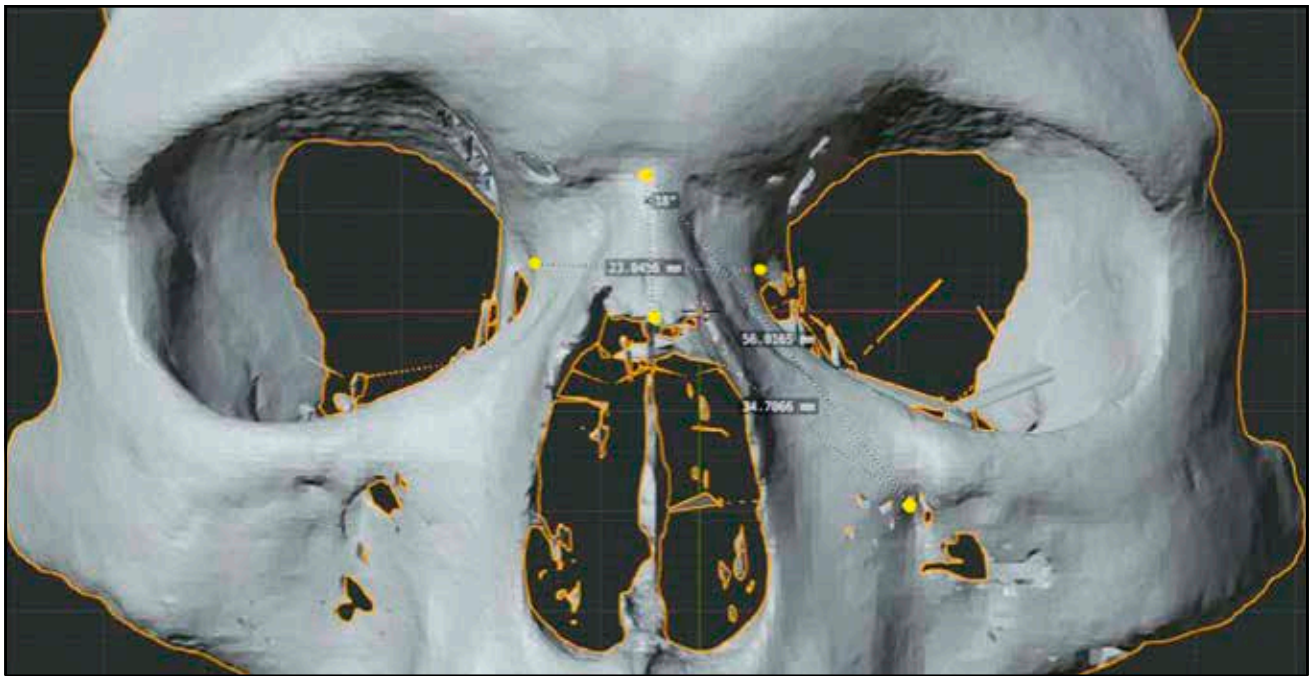

Figure 4. Measurements between: Rhi-FMO, Rhi-D, N-D.

who had no history of trauma to the viscera and neurocranium and had no pathology were selected for inclusion in the study. Patients with tumors at this level or any other condition that could change the anatomy of the naso-orbito-ethmoidal complex were excluded from the study.

Criteria for inclusion in the study:

- Age > 18 years old
- Patients with CT or CBCT examination performed
- No history of viscera and neurocranium pathology or traumatism.
- Exclusion criteria from the study:
- The patient's refusal
- CT or CBCT examination showing artifacts resulting from scanning that overlap over areas of interest
- History of orbital or nasal surgery
- History of malignant or benign tumours in the middle and / or upper floor of the face
- History of trauma to the middle and / or upper floor of the face.

RESULTS

The following average values were obtained from the measurements (Table 1):

- N-FMO: 53.03 mm, with max of 58.33 mm and min of 46.28 mm (Figure 2),
- N-Rhi: average of 22.41 mm, with max of 30.76

mm and min of 13.61 mm (Figure 2),

- N-IOF: average of 44.86 mm, with max of 56.01 mm and min of 38.48 mm (Figure 3),
- N-D: average of 14.64 mm, with max of 18.87 mm and min of 10.6 mm (Figure 4),
- Rhi-FMO: average of 60.45 mm, with max of 68.21 mm and min of 55.48 mm (Figure 4),
- Rhi-D: average of 26.50 mm, with max of 32.57 mm and min of 21.19 mm (Figure 4),
- Rhi-IOF: average of 39.44 mm, with max of 47.27 mm and min of 32.29 mm (Figure 3),
- D-D: average of 19.42 mm, with max of 25.64 mm and min of 15.63 mm (Figure 2).

DISCUSSIONS

Although FMO and IOF craniometric points are not considered by all authors, they were chosen because they are relatively stable during human life and easily recognized on standard antero-posterior radiographs of the skull and anterior sinuses of the face. The results we obtained coincide with the average obtained by other authors who measured the distance between these craniometric points. Przygocka et al.¹ obtained from the measurements made on human skulls, the average N-IOF distance of 45.00 mm, 39.00 mm Rhi-IOF, 19.00 mm N-Rhi.

The topography of the infraorbital foramen represented in this study by the IOF point represents an important landmark in facial surgery²⁻⁴. This

Table 1. Measurement results (in mm).

Age	Sex	N-FMO	N-Rhi	N-IOF	N-D	Rhi-FMO	Rhi-D	Rhi-IOF	D-D
19	m	54.8	16.57	56.01	17.58	59.84	21.21	34.7	23.04
78	f	50.46	17.54	42.66	16.2	56.75	24.15	34.73	25.64
28	m	49.05	18.62	49.05	13.74	57.01	29.12	32.34	18.23
74	m	52.42	21.79	41.65	15.33	58.69	26.22	35.01	22.26
59	m	52.34	24.28	46.3	17.21	59.23	26.13	46.3	18.05
33	f	50.75	22.4	41.77	16.64	56.31	26.39	35.89	21.4
56	m	54.87	27.17	48.77	14.89	63.46	25.78	40.33	19.3
35	m	54.31	13.61	43.22	17.13	57.47	21.85	38.37	17.43
45	f	50.73	20.39	41.66	13.74	57.21	24.55	34.56	16.39
85	f	51.39	22.25	42.9	14.03	59.56	26.95	38.03	16.37
62	f	50.57	21.89	40.83	16.1	55.65	22.74	39.15	17.69
59	f	54.19	22.89	45.5	16.07	60.33	25.43	39.89	21.8
86	f	53.44	28.18	45.28	15.13	60.56	27.62	38.55	19.36
75	m	55.81	25.7	43.26	16.02	63.57	28.17	35.54	19.58
77	m	55.53	29.73	45.61	17.73	68.21	32.08	38.7	21.8
47	m	55.34	21.33	41.95	17.21	62.46	27.16	35.43	19.88
70	f	54.05	20.58	44.34	16.24	60.05	26.49	37.98	19.76
23	m	51.37	19.38	46.65	14.88	55.98	26.12	47.24	16.37
24	m	52.35	21.60	44.70	13.89	61.17	27.33	43.98	19.56
27	m	56.80	22.76	44.32	15.67	66.61	27.65	41.65	16.65
28	m	54.16	20.03	46.01	13.32	58.91	25.31	40.14	17.06
32	m	54.96	22.14	47.10	14.96	64.71	30.56	42.77	23.72
34	m	53.98	22.76	42.33	13.13	62.58	26.55	38.61	19.47
34	m	53.03	24.09	47.17	13.18	61.43	27.63	41.80	19.99
35	m	58.33	18.64	45.64	16.07	61.24	26.49	42.33	21.56
35	m	54.71	22.49	43.52	15.57	63.03	28.73	41.89	17.69
38	m	56.04	22.13	46.40	13.98	62.24	24.92	39.41	19.60
41	m	55.93	27.34	48.22	14.51	63.74	30.50	42.08	20.41
44	m	51.83	21.96	50.22	12.51	56.39	23.46	42.44	17.55
45	m	52.20	23.38	44.88	15.51	59.74	25.63	40.37	18.82
47	m	55.64	21.01	45.30	18.87	62.94	31.11	43.21	21.83
53	m	56.53	23.24	48.39	18.38	64.90	30.55	41.79	19.96
53	m	53.88	26.13	45.18	15.08	60.15	25.80	39.93	21.91
53	m	53.09	22.76	46.86	16.49	60.53	29.19	42.14	21.83
54	m	51.40	24.31	43.70	13.04	58.96	27.56	43.27	18.39
62	m	52.12	18.28	49.61	14.23	58.13	21.76	40.22	20.00
66	m	55.32	25.39	46.31	17.78	62.38	29.94	45.21	21.17
71	m	53.35	26.64	46.03	14.88	62.52	30.71	42.45	19.90
77	m	50.76	22.82	45.61	14.50	56.81	25.24	39.26	18.91
83	m	56.04	17.98	47.66	14.65	61.43	21.19	40.87	22.62
92	m	52.13	30.76	44.55	14.12	64.62	32.57	42.50	18.45
22	f	51.83	25.57	39.21	10.60	60.87	27.70	33.90	15.63
22	f	52.08	22.40	43.03	11.66	60.82	26.01	38.00	17.26
30	f	54.50	21.45	45.64	12.49	62.59	25.88	40.66	17.61

33	f	51.50	18.90	38.94	13.96	57.56	26.27	32.29	15.92
34	f	55.01	20.94	46.06	14.43	62.77	24.69	41.22	18.70
36	f	50.58	26.29	42.42	13.94	61.86	30.67	38.70	18.94
37	f	52.22	20.27	46.54	13.23	58.77	24.50	42.78	18.02
37	f	56.00	25.45	43.95	13.91	66.61	28.67	40.11	19.14
38	f	51.88	21.89	46.09	13.77	59.29	25.03	40.51	18.63
41	f	49.25	21.34	43.17	12.37	58.96	26.50	40.11	18.33
44	f	53.28	23.47	45.79	14.81	61.11	26.86	40.52	19.67
49	f	46.28	22.69	38.48	11.37	55.48	26.33	34.50	17.33
49	f	49.60	25.21	41.6	10.87	57.19	25.34	35.39	19.28
50	f	50.57	21.89	40.83	16.1	55.65	22.74	39.15	17.69
51	f	54.19	22.89	45.5	16.07	60.33	25.43	39.89	21.8
51	f	53.44	28.18	45.28	15.13	60.56	27.62	38.55	19.36
53	m	55.81	25.7	43.26	16.02	63.57	28.17	35.54	19.58
62	m	55.53	29.73	45.61	17.73	68.21	32.08	38.7	21.8
65	m	55.34	21.33	41.95	17.21	62.46	27.16	35.43	19.88
69	f	54.05	20.58	44.34	16.24	60.05	26.49	37.98	19.76
74	m	51.37	19.38	46.65	14.88	55.98	26.12	47.24	16.37
80	m	52.35	21.60	44.70	13.89	61.17	27.33	43.98	19.56
93	m	56.80	22.76	44.32	15.67	66.61	27.65	41.65	16.65
Media		53.0390625	22.4103125	44.8642188	14.6420469	60.4586875	26.5023281	39.4496094	19.4240625
Min		46.28	13.61	38.48	10.6	55.48	21.19	32.29	15.63
Max		58.33	30.76	56.01	18.87	68.21	32.57	47.24	25.64

study attempted to establish relationships between the IOF point and other craniometric points. It can be used as a reference for further reconstruction in case of trauma.

Regarding the inter-dacrial (D-D) distance, other studies that realized a two-dimensional (2D) analysis on standard CT slices found similar dimensions ranging from 18 to 25 mm⁵.

Most complications associated with NOEM complex fractures (telechantus, nasal deformity, epiphora diplopia, enophthalmos and the deformation of the midface)^{6,7} result from inadequate treatment or failure of the optimal time for surgery, misdiagnosis, patient condition or his refusal for general anaesthesia. Correction for such complications requires either corrective surgery or can be performed by static reanimation by suture techniques⁸ for patients who refuse or whose condition does not allow general anaesthesia.

Detailed physical examination is difficult in the acute phase due to significant facial oedema that will distort facial features⁹. However, palpation may show a fracture of the nasal bones, often comminuted, with epistaxis, enlargement of the root of the nose, ophthalmic symptoms (diplopia, telecan-

thus, epiphora, enophthalmia) and sometimes rhinorrhea with cerebrospinal fluid. The average distance between the left and the right medial canthal ligaments is about half the interpupillary distance. Traumatic telecanthus is suspected when the intercanthal distance is greater than 35 mm; a measurement larger than 40 mm is suggestive of a NOEM complex fracture^{9,10}.

One limitation of this study was the inability to determine the points of interest on the 3D reconstruction due to the artefacts present after the CT scan. In this case, the CT and thus the 3D replica were discarded.

Reconstructive principles for solving complex cases of NOEM complex fracture involve osteotomy, repositioning and fixation of all bone fragments. For an optimal result, both aesthetically and functionally, the correct surgical planning, the clinical examination and the radiological results are important. While imaging diagnosis is essential for defining details of bone displacement and soft tissue injury, clinical examination is important for assessing functional injury caused by trauma and is essential for assessing recovery from surgical treatment^{5,11}. A CT examination with axial, coronal, sag-

ittal and 3D reconstructions is essential, not only for the confirmation of bone lesions, but also for the planning of surgical treatment. CBCT, with a very short exposure, allows the reconstruction of the facial skeleton both in 3D and in the three standard planes¹². Thanks to the 3D reconstructions, an overview of the position of the bone fragments is possible and, together with the information obtained from the measurements, offers the possibility to elaborate the optimal surgical plan for the best functional and aesthetic outcome.

CONCLUSIONS

This study, which required the measurement of distances between bone points, relatively stable, some visible on standard radiographs, tries to guide the diagnosis in the case of initial consultations in patients with trauma in the NOEM complex.

A database has been set up, which in the future may be useful in creating individualized splints depending on gender and age for simple NOEM complex fractures.

These measurements with different anthropometric variants can be used in the case of surgeries necessary for complex cases of panfacial fractures and NOEM complex for an optimal aesthetic and functional outcome.

The 3D reconstructions together with the information obtained from the measurements offer the possibility to elaborate the optimal surgical plan for the best functional and aesthetic outcome.

The correlation of these measurements with those performed clinically on patients will allow a diagnosis as early as possible, thus deciding the optimal time for surgery.

Conflicts of interest: The authors declare there is no conflict of interest.

Contribution of authors: All the authors have equally contributed to this work.

REFERENCES

1. Przygocka A, Podgórski M, Jędrzejewski K, Topol M, Polgaj M. The location of the infraorbital foramen in human skulls, to be used as new anthropometric landmarks as a useful method for maxillofacial surgery. *Folia Morphol (Warsz)*. 2012;71(3):198-204.
2. Apinhasmit W, Chompoopong S, Methathathip D, Sansuk R, Phetphunphiphat W. Supraorbital notch/foramen, infraorbital foramen and mental foramen in thais: anthropometric measurements and surgical relevance. *J Med Assoc Thai*. 2006;89(5):675-82.
3. Aziz SR, Marchena JJ, Puran A. Anatomic characteristics of the infraorbital foramen: a cadaver study. *J Oral Maxillofac Surg*. 2000;58(9):992-6. DOI: 10.1053/joms.2000.8742.
4. Boopathi S, Chakravarthy Marx S, Dhalapathy S, Anupa S. Anthropometric analysis of the infraorbital foramen in South Indian population. *Singapore Med J*. 2010;51(9):730-5.
5. Pagnoni M, Marengo M, Ramieri V, Terenzi V, Bartoli D, Amodeo G et al. Late treatment of orbital fractures: a new analysis for surgical planning. *Acta Otorhinolaryngol Ital*. 2014;34(6):439-45.
6. Baril SE, Yoon MK. Naso-orbito-ethmoidal (NOE) fractures: a review. *Int Ophthalmol Clin*. 2013;53(4):149-55. DOI: 10.1097/IIO.0b013e31829cf077.
7. Fraioli RE, Branstetter B, Deleyiannis FWB. Facial fractures: beyond Le Fort. *Otolaryngol Clin North Am*. 2008;41(1):51-76. DOI: 10.1016/j.otc.2007.10.003.
8. Costan VV, Popescu E, Sulea D, Stratulat IS. A new indication for barbed threads: static reanimation of the paralyzed face. *J Oral Maxillofac Surg*. 2018;76(3):639-45. DOI: 10.1016/j.joms.2017.07.176.
9. Gruss JS. Naso-ethmoid-orbital fractures: classification and role of primary bone grafting. *Plastic Reconstr Surg*. 1985;75(3):303-17.
10. Paskert JP, Manson PN, Iliff NT. Nasoethmoidal and orbital fractures. *Clin Plast Surg*. 1988;15(2):209-23.
11. Nkenke E, Benz M, Maier T, Wiltfang J, Holbach LM, Kramer M, et al. Relative en- and exophthalmometry in zygomatic fractures comparing optical non-contact, non-ionizing 3D imaging to the Hertel instrument and computed tomography. *J Craniomaxillofac Surg*. 2003;31(6):362-8. DOI: 10.1016/j.jcms.2003.07.001.
12. Torres MGG, Campos PSF, Segundo NPN, Navarro M, Crusoe-Rebello I. Accuracy of linear measurements in cone beam computed tomography with different voxel sizes. *Implant Dent*. 2012;21(2):150-5. DOI: 10.1097/ID.0b013e31824bf93c.

