

CASE REPORT

Sinonasal non-intestinal-type adenocarcinoma with isolate lagophthalmos and abducens nerve palsy: Case report

Ionut Isaia Jeican^{1,2,3} , Marius Cristian Nistor⁴, Monica Muntean³, Mihai Dumitru⁵ , Silviu Albu¹ 

¹Department of Otorhinolaryngology and Head and Neck Surgery, University Clinical Hospital of Railway Company, “Iuliu Hatieganu” University of Medicine and Pharmacy, Cluj-Napoca, Romania

²Department of Anatomy and Embryology, “Iuliu Hatieganu” University of Medicine and Pharmacy, Cluj-Napoca, Romania

³Infectious Disease Clinical Hospital, “Iuliu Hatieganu” University of Medicine and Pharmacy, Cluj-Napoca, Romania

⁴Department of Ophthalmology, University Clinical Hospital of Railway Company, “Iuliu Hatieganu” University of Medicine and Pharmacy, Cluj-Napoca, Romania

⁵ENT Department, Bucharest University Emergency Hospital, “Carol Davila” University of Medicine and Pharmacy, Bucharest, Romania

ABSTRACT

Sinonasal non-intestinal-type adenocarcinoma is a rare malignancy, with limited large-scale studies available in the medical literature. We present a case report of a 60-year-old male patient with sinonasal non-intestinal-type adenocarcinoma, isolate lagophthalmos and abducens nerve palsy, who had been exposed for 30 years to hard wood dust.

KEYWORDS: non-intestinal sinonasal adenocarcinoma, lagophthalmos, abducens nerve palsy.

INTRODUCTION

Sinonasal adenocarcinoma is a rare malignancy (approximately 3% of all head and neck malignancies¹) arising from mucus-secreting glandular tissue. Due to its rarity, only limited large-scale studies are available in the medical literature². Sinonasal adenocarcinoma can occur anywhere in the sinonasal tract, the nasal cavity being the most commonly affected, followed by the ethmoid and maxillary sinuses³. The patients are often men, around 60 years of age, with a long professional history in the wood or leather industry⁴.

In the early stages of the disease, sinonasal adenocarcinoma typically presents with vague and nonspecific symptoms, such as epistaxis and nasal obstruction, often leading to late stage diagnosis⁵. In advanced cases, locoregional invasion may occur towards the orbit⁶, the pterygopalatine fossa, the infratemporal fossa and the cranial cavity⁶. The presence of orbital invasion is an important prognostic predictor⁷.

Histologically, sinonasal adenocarcinomas can be described as salivary-type adenocarcinomas and non-salivary-type adenocarcinomas. The non-salivary-type adenocarcinoma is divided into intestinal-type and non-intestinal-type⁸.

The treatment is based on complete surgical excision and radiotherapy with or without chemotherapy reserved for extensive forms of the disease.

CASE REPORT

A 60-year-old male patient presented to the ENT clinic for left frontal headache (previously started one year before), recurrent epistaxis and left nasal obstruction, upper left hemilabial paresthesia (previously started one month before). The patient also complained of eye pain, retroocular pressure and a progressive decrease in visual acuity in the left eye leading to blindness, symptoms that started about a month before the visit to the clinic. For these symptoms, the patient

Corresponding author: Mihai Dumitru, MD MSc PhD, Assistant Professor, ENT Department, Bucharest University Emergency Hospital, “Carol Davila” University of Medicine and Pharmacy, Bucharest, Romania

ORCID: <https://orcid.org/0000-0003-1373-2510>

e-mail: orldumitrumihai@yahoo.com

Received for publication: March 10, 2022 / **Accepted:** April 15, 2022

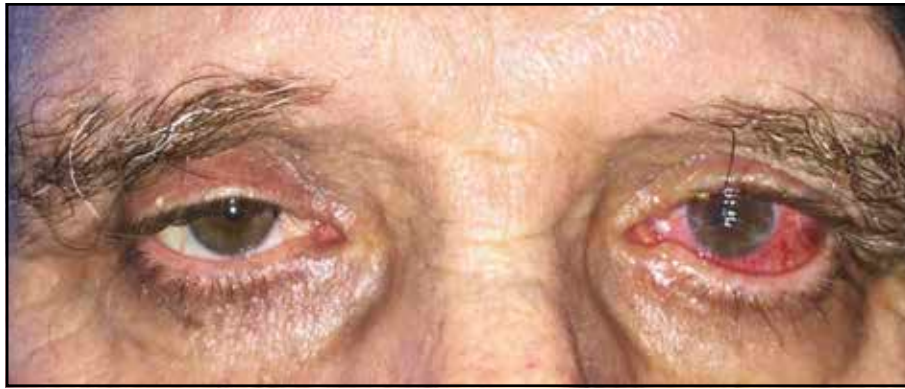

Figure 1. Clinical aspect – lagophthalmia, conjunctival chemosis in the left eye.

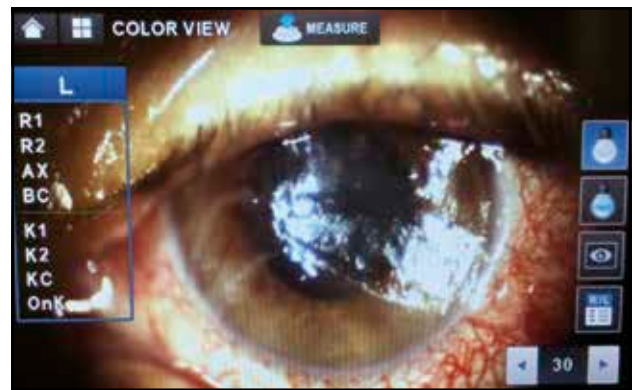
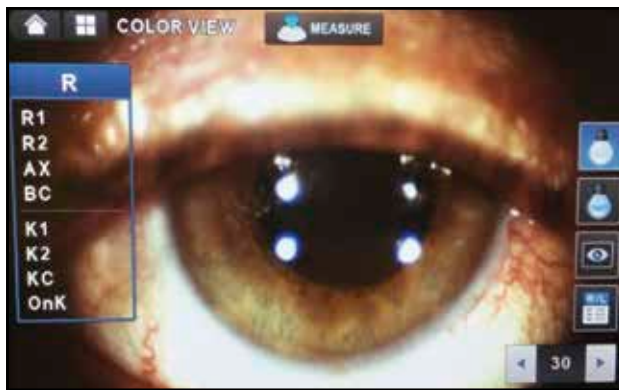
Figure 2. Ocular biomicroscopy: anterior pole of the right eyeball – normal appearance; the anterior pole of the left eyeball – accentuated lower epithelialization of the cornea.

saw the ophthalmologist in his area and received a prescription for eyeglasses for vision correction.

Also, the patient mentioned a negative weight curve (20 kg lost in the last 12 months). A very important detail from the anamnesis was that the patient has been professionally exposed to wood dust for about 30 years.

The ophthalmological examination indicated the following: asymmetric facies, ocular asymmetry and lagophthalmia in the left eye with conjunctival chemosis (Figure 1), sixth nerve palsy, stromal and epithelial keratoconjunctivitis with accentuated inferior deepithelialization (Figure 2), absent pupillary reflexes. The fundus of the left eye could not be visualized.

The nasal endoscopic examination showed the presence of a polypoid tumor mass occupying the superior part of the left nasal cavity and extending into the left anterior sphenoid wing.

On the cranio-cerebral MRI examination without contrast agent, performed about 2 months before the visit to the clinic, a polypoid tumor mass was observed in the left nasal fossa, extended into the anterior wall of the left sphenoid sinus (Figure 3A). The cranio-cerebral CT scan without contrast agent performed 2 weeks before the visit identified a left orbital inflammatory reaction, bilateral opacified ethmoid, opacification of

the left sphenoid sinus (Figure 3B) and of bilateral frontal sinuses.

Considering the endoscopic and imagistic appearances, endoscopic nasal surgery was performed with general anesthesia with orotracheal intubation, performing the bilateral opening of the anterior and posterior ethmoid cells, left sphenoidotomy (Figure 4), the opening of the bilateral frontal sinuses (Draf III type). The tumor had an exophytic appearance, occupied the entire middle meatus, reached the level of the lower turbinate; the periorbita was not infiltrated at all. The tumor showed only obstruction of the sphenoid and frontal sinus ostium with purulent sphenoid and frontal sinusitis. The entire tumor was removed in a piecemeal manner with moderate bleeding. No tumor extension has been identified in the orbit. Bioptic material was collected from the periorbita.

The histopathological examination of the tumoral intraoperative pieces revealed fragments of the mucosa lined with respiratory epithelium with reactive changes, edema in the lamina propria (lymphocytes and eosinophils). In most fragments a polymorphic epithelial tumor proliferation was observed, with tubular, cribriform, adenoid-cystic, and solid architecture. Some tumor cell nests contained central areas of necrosis. The resection margins could not be appreciated. The histopathological aspect

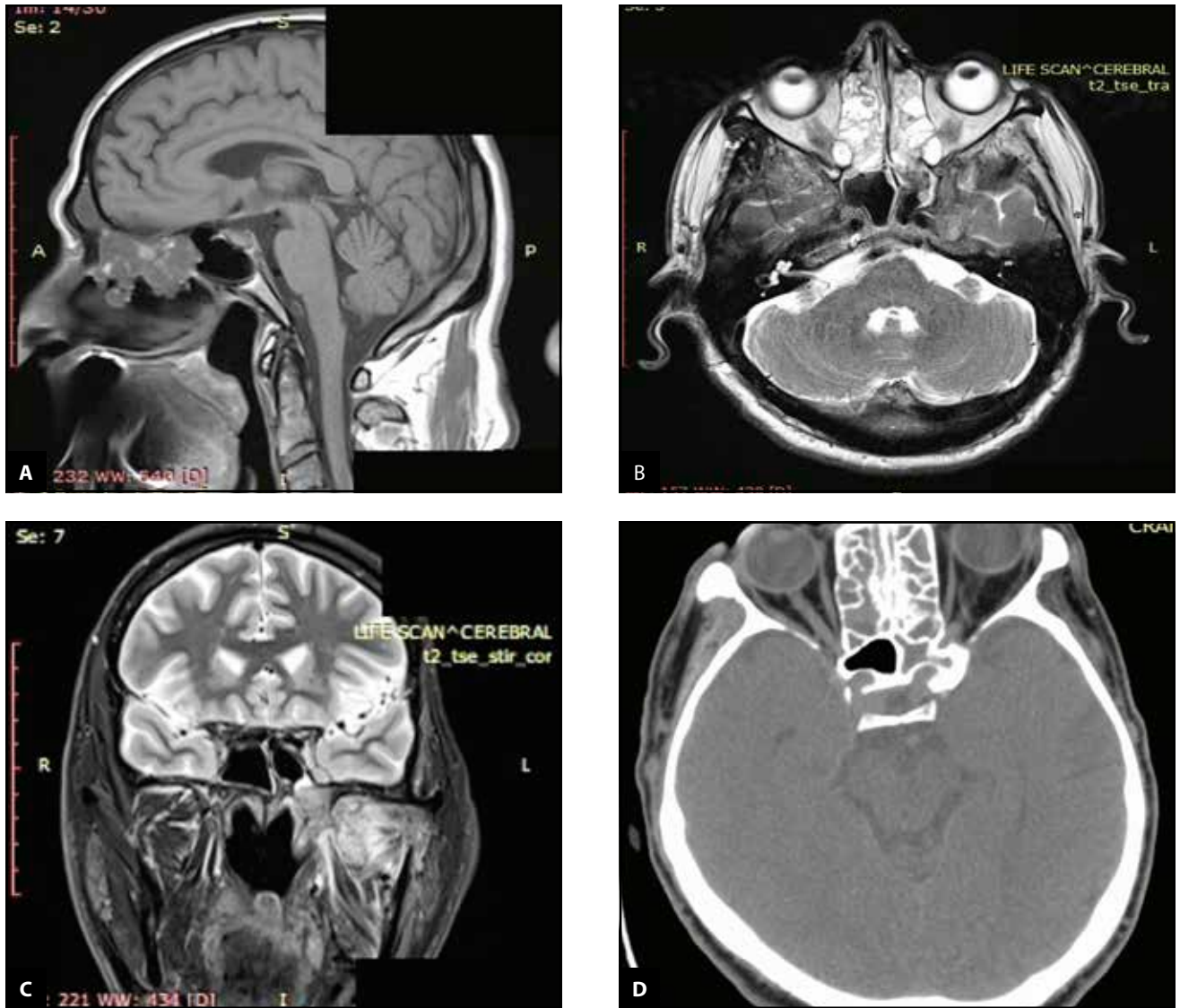


Figure 3. A-C. Cranio-cerebral MRI: polypoid tumor mass extending into the anterior wall of the left sphenoid sinus (A-B) and left pterygopalatine fossa (C); D. Cranio-cerebral CT scan, axial slice: opacification of bilateral ethmoid cells and left sphenoid sinus.

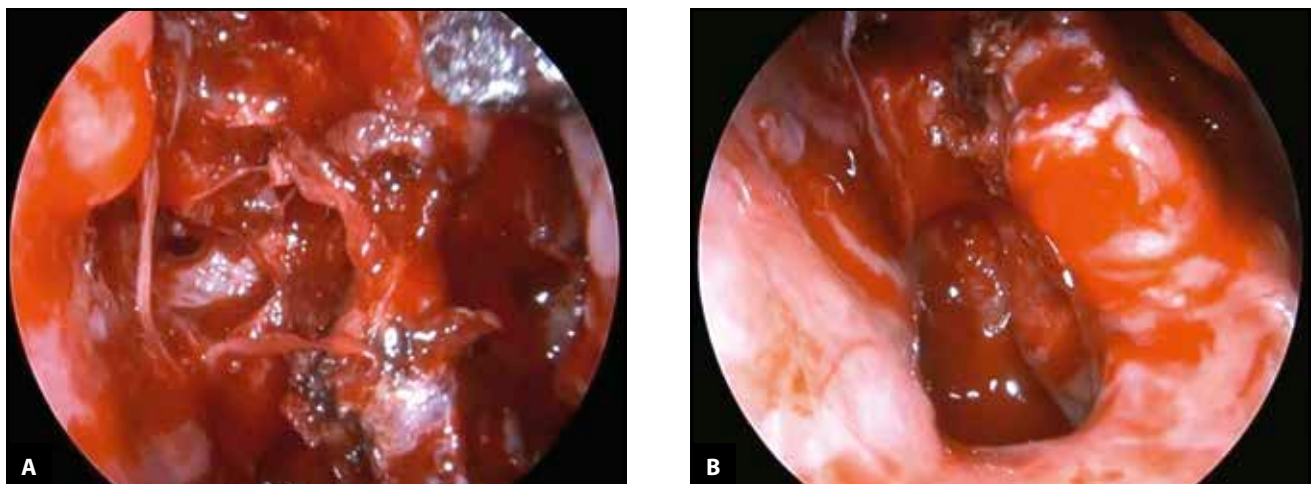


Figure 4. Intraoperative nasal endoscopy: A. partial endoscopic excision of the tumor, sphenoidotomy; B. tumor-free choana and entrance in the nasopharynx.

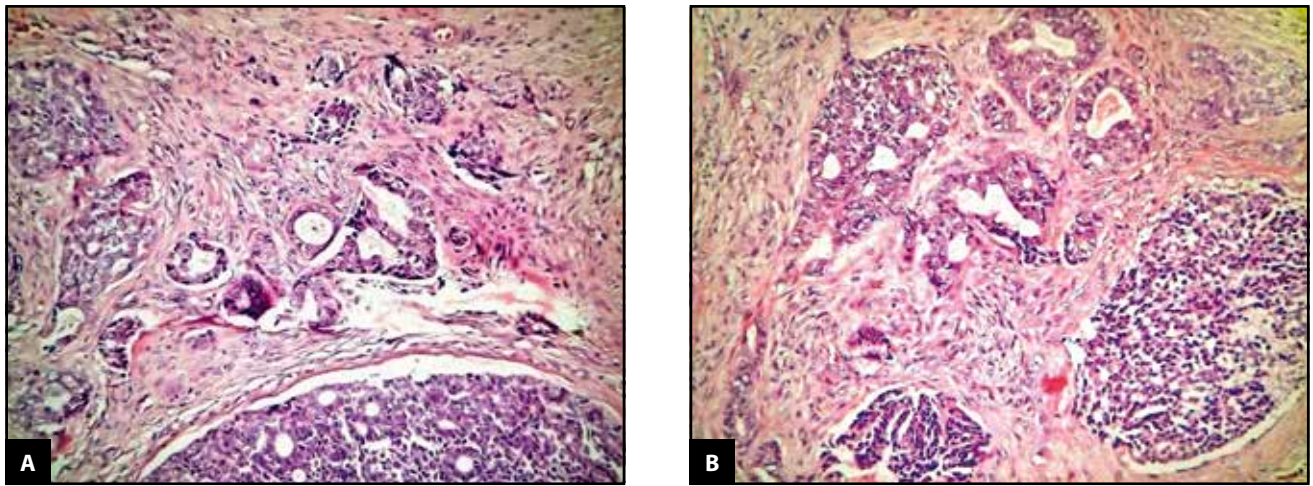


Figure 5. Histopathological results: **A.** mixture of back-to-back glands, anastomosing cords, and solid areas (HEX40); **B.** compact acini, back-to-back glands, cystic dilatation; and intraglandular mucin (HEX100).

advocated a high-grade non-intestinal sinus and nasal adenocarcinoma (Figure 5). The histopathological examination of the periorbital specimen was negative.

The patient received a recommendation for urgent left eyelid suture, antibiotic eye drops and was referred to the Oncology Department.

The patient avoided further check-ups due to the unfolding of the COVID-19 pandemic.

DISCUSSIONS

Sinonasal adenocarcinomas are rare diseases of the sinonasal tract that are professionally associated with exposure to wood and/or skin dust. The ethmoid sinuses appear to be the most commonly involved⁹.

Sinonasal non-intestinal-type adenocarcinoma is less common and less known, its correlation with exposure to wood dust still being incompletely understood. Recent studies have linked it to softwood dust exposure¹⁰. In our case, the patient was mainly exposed to hardwood dust. Clearly, histopathological variations reflect different pathogenetic circumstances in the risk factor exposure model.

If at first patients may be asymptomatic or have a non-specific nasal syndrome (predominantly unilateral nasal obstruction, unilateral epistaxis), then the clinical picture includes headache that progressively increases in intensity, decreased visual acuity to amaurosis and cranial neuropathies¹¹. Tumors of the sphenoidal sinus present cranial neuropathies, headaches and visual disturbances¹². In our patient, the left frontal headache (previously started a year before) can be explained by the irritation exerted by the inflammation on the ethmoidal branches (from the ophthalmic nerve). Even if the bone continuity of the orbit's medial wall is not identified to be disrupted by tumor inva-

sion, the sinus inflammatory reaction can spread through the ethmoid orifices.

The abducens nerve has a high vulnerability to direct and indirect injuries. The sixth nerve palsy is commonly caused by tumors located close to the nerve, such as tumors in the cavernous sinus. The nerve compression can be caused directly by the tumor or indirectly by the peritumoral edema¹³. Although in our case we did not find definite imaging evidence for the invasion of the cavernous sinus, the peritumoral edema in the left lateral wall of the sphenoid could be responsible for the abducens nerve palsy. Also, the orbital inflammatory reaction can cause sixth nerve palsy, through compression and hypoxia.

Lagophthalmia is rare and has a varied etiology (infections, traumas, tumors, metabolic and toxic factors, iatrogenic, neurological, congenital and idiopathic causes)^{14,15}. In our patient, lagophthalmia is a peculiarity and can be explained by the local compressive-hypoxic mechanism exerted by the orbital edema on the orbicularis muscle and on its nerve branches (lagophthalmia secondary to the orbital inflammatory reaction, although it is not pronounced).

The imaging evaluation of the patients with sinonasal tumors plays a crucial role in the diagnosis and it can include the cranio-cerebral nuclear magnetic resonance imaging (MRI) or computed tomography (CT) with contrast enhancement as a secondary/complementary choice. Preoperative imaging assesses the local extension of the tumor and the chances of resection. The MRI evaluation differentiates the tumor from obstructive nasal secretions, assesses adjacent soft tissue and intracranial invasion¹⁶. The pretreatment assessment of orbital invasion is difficult, even with the combination of CT and MRI, due to frequent discrepancies between CT imaging, intraoperative evaluation and histopathological examination of orbital extensions¹⁷.

In our patient, radiographic imaging did not confirm tumor invasion of the orbit or cavernous sinus.

Ultrasound of the neck may be part of the imaging assessment to assess latero-cervical lymph nodes¹⁸ in order to establish the tumor extension.

Biopsy under general or local anaesthesia is recommended in all cases where there is clinical and/or imaging suspicion, especially in patients with a history of occupational exposure to wood and/or skin dust¹⁸.

Histologically, sinonasal non-intestinal-type adenocarcinoma is classified into high-grade and low-grade types. The high grade can show a great deal of morphological heterogeneity: blastomatous, apocrine, oncocytic/mucinous, poorly differentiated/undifferentiated, with cytologic and nuclear pleomorphism, mitotic activity, and necrosis. These tumors have been reported to lack CDX-2 and CK20 immunoreactivity, but their specificities remain unknown. The heterogeneous features of these tumors may overlap with those of other primary or metastatic malignancies in this anatomical region. The prognosis of high-grade non-intestinal adenocarcinomas is poor^{4,8}.

The current elective treatment is curative-intent surgical resection performed through the least invasive method that allows the removal of the tumor to the negative resection margins, supplemented with postoperative radiotherapy. Due to comparable oncological results and lower morbidity, the transnasal endoscopic approach is preferred to the trans-facial approach (with craniofacial resection in cases of skull-base involvement)^{19,20}.

Transnasal endoscopic resection is a safe and effective surgical option in selected cases and in the presence of an experienced surgical team²¹. Endoscopic endonasal surgery can be effective as a single treatment modality for early-stage (T1–T2) low-grade lesions, which can be radically resected with negative margins²².

The tumoral multifocality was observed in different mucosal area of the nasal cavities, even distant to each other; that is why some authors such as Castelnuovo et al. recommend “a bilateral ethmoid labyrinth resection because the contralateral ethmoid may be exposed to the same carcinogenic risk factors”²³.

Surgical treatment can raise technical problems burdened by the local aggressivity of the tumor that causes changes in the local anatomy, as well as the proximity of critical anatomical structures (the orbit, the skull base, vascular-nervous elements). Contraindications to curative surgery, detectable by imaging, are orbital invasion requiring exenteration, dural invasion over the orbital roof, invasion of the walls of the maxillary sinus (except the medial one), invasion of the internal carotid artery or cavernous sinus²⁴.

Adjuvant radiotherapy is indicated for locally advanced, high-grade tumors and/or positive margins. Neoadjuvant chemotherapy (cisplatin, 5-fluorouracil,

leucovorin) is reserved for palliative stages²⁵. The advanced-stage tumors carry a poor prognosis given the difficulty in achieving a surgical cure and variable sensitivity to adjuvant treatments¹¹.

The studies show that between orbital preservation and orbital exenteration there are no significant differences in local recurrence or survival⁷.

Unfortunately, the patient avoided further check-ups due to the unfolding of the COVID-19 pandemic. For sinonasal malignancies, the survival rates are small²⁶. 5-year survival rates after endoscopic resection of sinonasal malignancy can be greater than after open craniofacial resection. Also, the rate is influenced by cancer grade²⁷.

CONCLUSIONS

Malignant pathology of the rhino-orbital border can easily be missed during diagnostic, especially in the early stages. The presence of a nasal syndrome detected by a short assessment of ENT history during the ophthalmological exam may raise the suspicion of a cancer located in the rhino-orbital border area.

Conflicts of interest: The authors declare there is no conflict of interest.

Contribution of authors: All the authors have equally contributed to this work.

REFERENCES

1. Lund VJ, Stammberger H, Nicolai P, Castelnuovo P, Beal T, Beham A, et al. European position paper on endoscopic management of tumours of the nose, paranasal sinuses and skull base. *Rhinol Suppl.* 2010;22:1-143.
2. Patel NN, Maina IW, Kuan EC, Triantafyllou V, Trope MA, Carey RM, et al. Adenocarcinoma of the sinonasal tract: a review of the national cancer database. *J Neurol Surg B Skull Base.* 2020;81(6):701-8. DOI: 10.1055/s-0039-1696707.
3. Perez-Ordoñez B. Hamartomas, papillomas and adenocarcinomas of the sinonasal tract and nasopharynx. *J Clin Pathol.* 2009;62(12):1085-95. DOI: 10.1136/jcp.2007.053702.
4. Stelow EB, Jo VY, Mills SE, Carlson DL. A histologic and immunohistochemical study describing the diversity of tumors classified as sinonasal high-grade nonintestinal adenocarcinomas. *Am J Surg Pathol.* 2011;35(7):971-80. DOI: 10.1097/PAS.0b013e31821cbd72.
5. Tukul MR, Adelman MJ, Gladstone GJ, Appleford C. Nonintestinal type adenocarcinoma of the ethmoid sinus with unusual cribriform histologic pattern. *Ophthalmic Plast Reconstr Surg.* 2021;37(3):e123. DOI: 10.1097/IOP.0000000000001736.
6. Leivo I. Update on sinonasal adenocarcinoma: classification and advances in immunophenotype and molecular genetic make-up. *Head Neck Pathol.* 2007;1(1):38-43. DOI: 10.1007/s12105-007-0025-2.
7. Suárez C, Ferlito A, Lund VJ, Silver CE, Fagan JJ, Rodrigo JP, et al. Management of the orbit in malignant sinonasal tumors. *Head Neck.* 2008;30(2):242-50. DOI: 10.1002/hed.20736.
8. Leivo I. Sinonasal adenocarcinoma: Update on classification, immunophenotype and molecular features. *Head Neck Pathol.* 2016;10(1):68-74.

- DOI: 10.1007/s12105-016-0694-9.
9. Choussy O, Ferron C, Védrine PO, Toussaint B, Liétin B, Marandas P, et al. Adenocarcinoma of Ethmoid: a GETTEC retrospective multicenter study of 418 cases. *Laryngoscope*. 2008;118(3):437-43. DOI: 10.1097/MLG.0b013e31815b48e3.
 10. Leivo I, Holmila R, Luce D, Steiniche T, Dictor M, Heikkilä P, et al. Occurrence of sinonasal intestinal-type adenocarcinoma and non-intestinal-type adenocarcinoma in two countries with different patterns of wood dust exposure. *Cancers (Basel)*. 2021;13(20):5245. DOI: 10.3390/cancers13205245.
 11. Travers S, Vazmitsel M, Parrett T, Litofsky NS. Isolated primary sinonasal adenocarcinoma of the sphenoid sinus. *Cureus*. 2021;13(3):e14127. DOI: 10.7759/cureus.14127.
 12. DeMonte F, Ginsberg LE, Clayman GL. Primary malignant tumors of the sphenoidal sinus. *Neurosurgery*. 2000;46(5):1084-91; discussion 1091-2. DOI: 10.1097/00006123-200005000-00012.
 13. Marza A, Manea C. Abducens nerve palsy on a patient with sphenoid fungal rhinosinusitis and cavernous sinus meningioma – Case report. *Romanian Journal of Rhinology*. 2018;8(31):193-6. DOI: 10.2478/rjr-2018-0022.
 14. Fu L, Patel BC. Lagophthalmos. 2021. In: StatPearls [Internet]. Treasure Island (FL): StatPearls Last Update: November 2, 2021. Available from: <https://www.ncbi.nlm.nih.gov/books/NBK560661/>.
 15. MacVie OP, Majid MA, Hussin HM, Ung T, Manners RM, Ormerod I, et al. Idiopathic isolated orbicularis weakness. *Eye (Lond)*. 2012;26(5):746-8. DOI: 10.1038/eye.2012.5.
 16. Amin MB, Greene FL, Edge SB, Compton CC, Gershewald JE, Brookland RK, et al. The Eighth Edition AJCC Cancer Staging Manual: Continuing to build a bridge from a population-based to a more “personalized” approach to cancer staging. *CA Cancer J Clin*. 2017;67(2):93-9. DOI: 10.3322/caac.21388.
 17. Salfrent M, Garcia GCTE, Guichard JP, Bidault F, Reizine D, Aupérin A, et al. Imaging of skull base and orbital invasion in sinonasal cancer: correlation with histopathology. *Cancers (Basel)*. 2021;13(19):4963. DOI: 10.3390/cancers13194963.
 18. Ferrari M, Bossi P, Mattavelli D, Ardighieri L, Nicolai P. Management of sinonasal adenocarcinomas with anterior skull base extension. *J Neurooncol*. 2020;150(3):405-17. DOI: 10.1007/s11060-019-03385-8.
 19. Hosemann W, Schroeder HW. Comprehensive review on rhino-neurosurgery. *GMS Curr Top Otorhinolaryngol Head Neck Surg*. 2015;14:Doc01. DOI: 10.3205/cto000116.
 20. Wardas P, Tymowski M, Piotrowska-Seweryn A, Kaspera W, Ślaska-Kaspera A, Markowski J. Endoscopic approach to the resection of adenoid cystic carcinoma of paranasal sinuses and nasal cavity: case report and own experience. *Eur J Med Res*. 2015;20:97. DOI: 10.1186/s40001-015-0189-2.
 21. Alokby G, Casiano RR. Endoscopic resection of sinonasal and ventral skull base malignancies. *Otolaryngol Clin North Am*. 2017;50(2):273-85. DOI: 10.1016/j.otc.2016.12.005.
 22. Bhayani MK, Yilmaz T, Sweeney A, Calzada G, Roberts DB, Levine NB, et al. Sinonasal adenocarcinoma: a 16-year experience at a single institution. *Head Neck*. 2014;36(10):1490-6. DOI: 10.1002/hed.23485.
 23. Castelnovo P, Turri-Zanoni M, Battaglia P, Antognoni P, Bossi P, Locatelli D. Sinonasal malignancies of anterior skull base: histology-driven treatment strategies. *Otolaryngol Clin North Am*. 2016;49(1):183-200. DOI: 10.1016/j.otc.2015.09.012.
 24. Moya-Plana A, Bresson D, Temam S, Kolb F, Janot F, Herman P. Development of minimally invasive surgery for sinonasal malignancy. *Eur Ann Otorhinolaryngol Head Neck Dis*. 2016;133(6):405-11. DOI: 10.1016/j.anorl.2016.06.001.
 25. Vander Poorten V, Jorissen M. A comprehensive update on intestinal and non-intestinal-type adenocarcinomas. *Adv Otorhinolaryngol*. 2020;84:137-53. DOI: 10.1159/000457934.
 26. Kilic S, Kilic SS, Baredes S, Liu JK, Eloy JA. Survival, morbidity, and quality-of-life outcomes for sinonasal and ventral skull base malignancies. *Otolaryngol Clin North Am*. 2017;50(2):467-80. DOI: 10.1016/j.otc.2016.12.018.
 27. Rawal RB, Farzal Z, Federspiel JJ, Sreenath SB, Thorp BD, Zanation AM. Endoscopic resection of sinonasal malignancy: a systematic review and meta-analysis. *Otolaryngol Head Neck Surg*. 2016;155(3):376-86. DOI: 10.1177/0194599816646968.

© 2022 Ionut Isaia Jecan, Marius Cristian Nistor, Monica Muntean, Mihai Dumitru, Silviu Albu, published by Romanian Rhinologic Society



This is an open access article published under the terms and conditions of the Creative Commons Attribution-NonCommercial-NoDerivatives 4.0 International (CC BY-NC-ND 4.0) License (<https://creativecommons.org/licenses/by-nc-nd/4.0/>). CC BY-NC-ND 4.0 license requires that reusers give credit to the creator by citing or quoting the original work. It allows reusers to copy, share, read, download, print, redistribute the material in any medium or format, or to link to the full texts of the articles, for non-commercial purposes only. If others remix, adapt, or build upon the material, they may not distribute the modified material.