

## LITERATURE REVIEW

# Cavernous haemangioma of the nasal pyramid: literature review and our experience

Codrut Sarafoleanu<sup>1,2,3</sup> , Sandra-Maria Camburu<sup>1</sup>, Daniel Lupoi<sup>1,2,3</sup> 

<sup>1</sup>ENT&HNS Department, "Sfanta Maria" Hospital, Bucharest, Romania

<sup>2</sup>"Carol Davila" University of Medicine and Pharmacy, Bucharest, Romania

<sup>3</sup>CESITO Centre, "Sfanta Maria" Clinical Hospital, Bucharest, Romania

## ABSTRACT

Cavernous haemangioma is a slow-growing benign vascular tumor. It arises most frequently from the vertebral bodies or bones of the skull and face, the main affected being the frontal bone, the parietal bone, the orbital bone, the zygoma, maxilla, the mandible and nasal bones. Cavernous haemangioma of the nasal pyramid is very rare. In this review, we discuss the most important characteristics of this rare tumor, while presenting the clinical case of a 15-year-old male patient diagnosed in 2012 with a tumor located in the bones of the nasal pyramid, which turned out to be a cavernous haemangioma. The patient came to our clinic for swelling of the nasal pyramid with overlying skin of normal aspect, which appeared about 4 years before, with progressive evolution. The clinical examination showed a round-oval tumor with approximately 3/3 cm in diameter, hard, painless, without inflammatory signs, located in the region of the nasal pyramid, developed especially on the left side. The surgical treatment consisted in complete removal of the tumor through external approach, by lateral rhinotomy. There was no recurrence in the 10-year follow-up period. The particularity of this case is represented by the age and rare occurrence of cavernous haemangioma in the bones of the face, especially at the level of the nasal pyramid. Complete resection of the tumor represents the "gold standard" treatment.

**KEYWORDS:** intraosseous, cavernous haemangioma, nasal, tumor.

## INTRODUCTION

The causes of chronic nasal obstruction can be multiple, including the inflammation of the nasal turbinates, the presence of tumors in the nasal cavities or paranasal sinuses, congenital malformations, local trauma or the presence of a foreign body<sup>1</sup>.

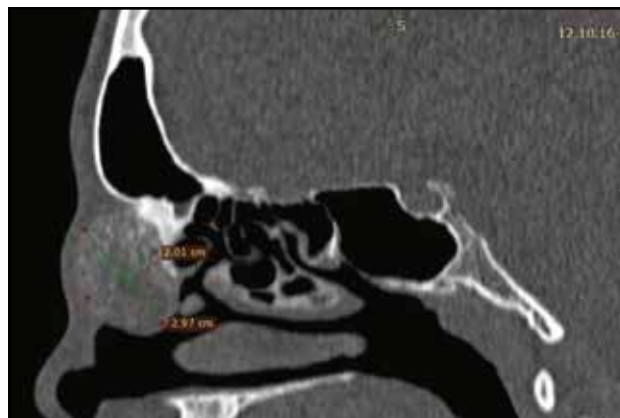
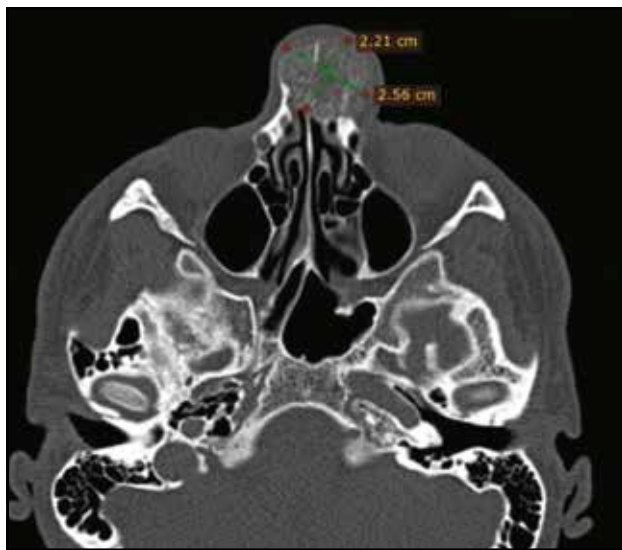
The anatomical regions represented by the nose, paranasal sinuses and the pharynx are frequently the place of occurrence for certain tumors (benign or malignant) of different histopathological origins. However, some of these tumors are very rare, unusual, requiring special attention in diagnosis, paraclinical investigations and therapeutic approach<sup>2</sup>.

Congenital lesions with improper vascular development are known as vascular abnormalities. There are two major groups of vascular abnormalities: vascular malfor-

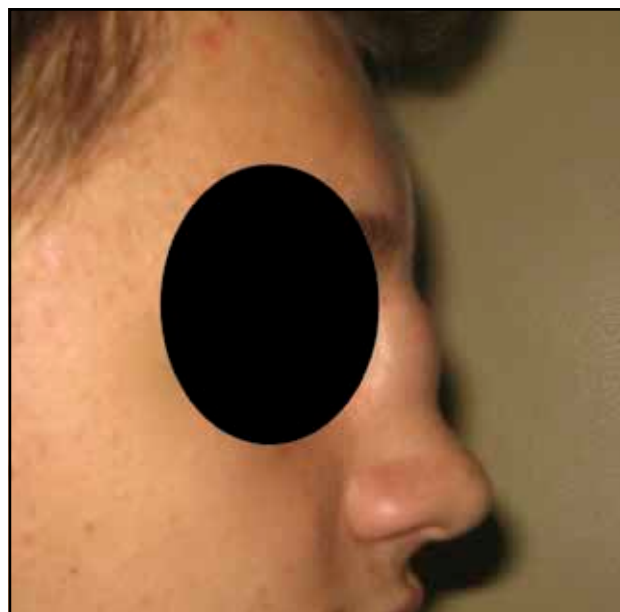
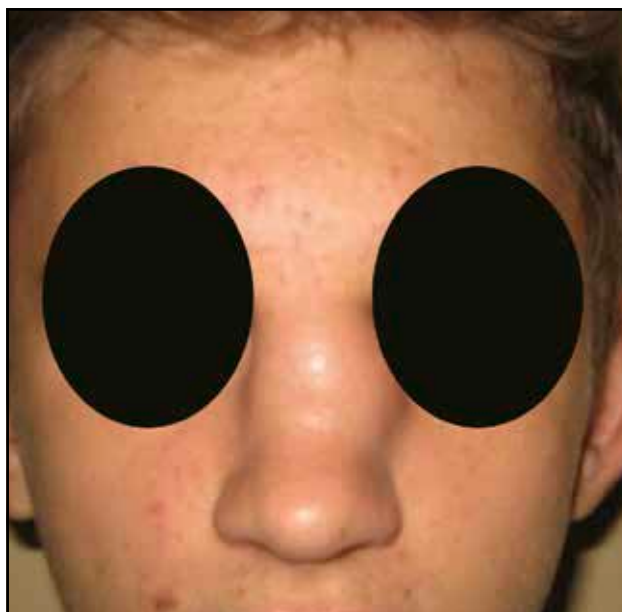
mation, represented by a local defect in vascular development, and vascular tumor (haemangioma), which is abnormal cellular hyperplasia<sup>3</sup>.

Haemangiomas belong to the category of benign vascular tumors and represent about 20% of all benign tumors located in the nasal cavity<sup>4</sup>. They can occur in a variety of tissues such as the skin, mucous membranes, muscles, bones<sup>4</sup> or salivary glands<sup>5</sup>. Intraosseous haemangioma arises most frequently from the vertebral bodies or bones of the skull and face, the main affected being the frontal bone, the parietal bone, the orbital bone, the zygoma, maxilla, the mandible and nasal bones<sup>7-8</sup>. It represents about 0.7-1% of all tumors with bone origin<sup>6,7</sup>. These tumors have a slow growth rate, variably involving the nasal mucosa, the submucosa, the subcutaneous tissue or the skin<sup>9</sup>.

The etiology is not clear, but in the specialized scientific



**Figure 1.** CT scan of the head (axial and sagittal slices): space-replacement process developed at the level of the nasal pyramid, intraosseously, and extension of the disease into the retro-orbital space, with soft-tissue thickening at the level of the orbital apex.



**Figure 2.** The clinical appearance of the tumor: a round, oval growth of about 3.3 cm in diameter, developed at the area of the nasal pyramid (mainly on the left side).

articles, local traumas, especially those produced in vulnerable sites like the nasal bones<sup>8</sup>, are mentioned as a possible predisposing factor. Also, hormonal factors are mentioned as being involved, but their role is not exactly established. There are authors who have suggested that haemangioma is actually a hamartoma that derives from the development of the mesoderm, which is endothelially differentiated and then it is vascularized and canalized<sup>10</sup>.

Environmental and clinical risk factors are not always clear, sometimes they cannot be ruled out, so clinicians must take into account that genetic susceptibility is often intensified and complicated by environmental factors<sup>2</sup>.

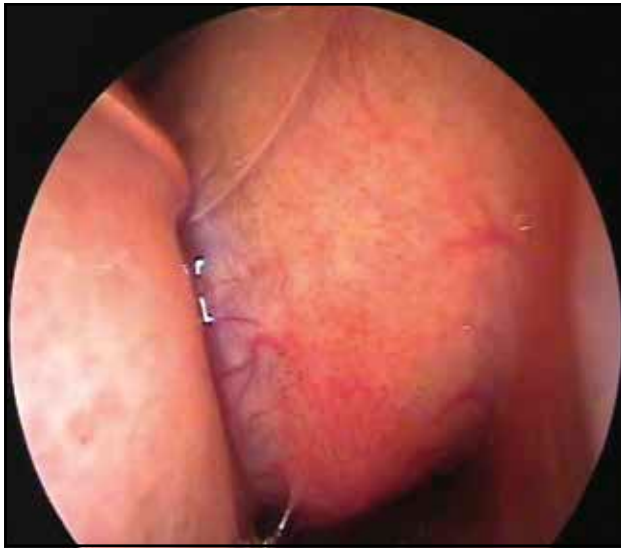
It is more common in the first decades of life and mainly affects women, the ratio being 2:1<sup>11</sup>. However, cases

have also been recorded in new-borns and adults in their ninth decade of life<sup>8</sup>.

From the histopathological point of view, haemangiomas are divided into 3 types: capillary, cavernous and mixed, the cavernous one being the rarest<sup>12</sup>.

The best method of treatment is total excision of the tumor, followed by the primary reconstruction of the defect, if necessary<sup>8</sup>.

To date, few cases of cavernous haemangioma of the nasal bones have been reported, but their number is increasing<sup>13</sup>. We discuss the most important characteristics of this rare tumor while presenting the clinical case of a 15-year-old male patient, who was diagnosed with a cavernous haemangioma of the nasal pyramid.



**Figure 3.** Nasal endoscopic examination: slightly hyperaemic tumor in contact with the nasal septum, covered with serous secretions, partially obstructing the nasal cavity.

## CASE REPORT

We present the case of a 15-year-old male patient, diagnosed in 2012 with a tumor located at the area of the nasal pyramid for which he underwent surgical removal in our ENT Department, who presented to us accusing swelling at the site of the nasal pyramid, with firm consistency, painless spontaneously and on palpation, having superjacent skin of normal appearance. The symptomatology was present for about 4 years, and it had progressive evolution.

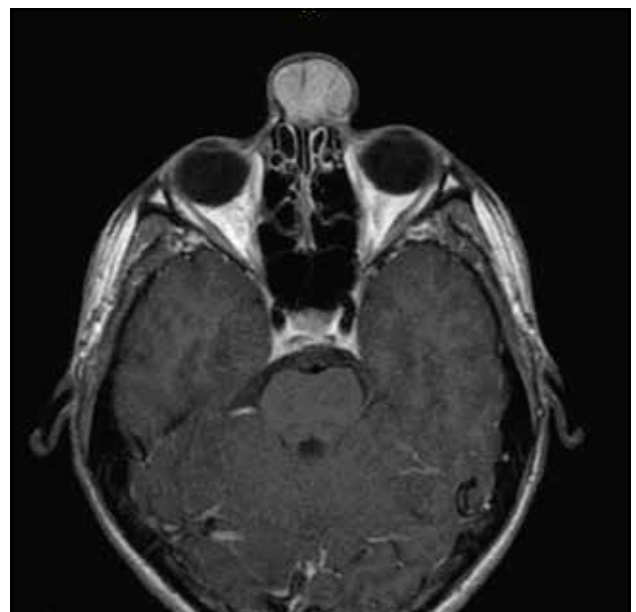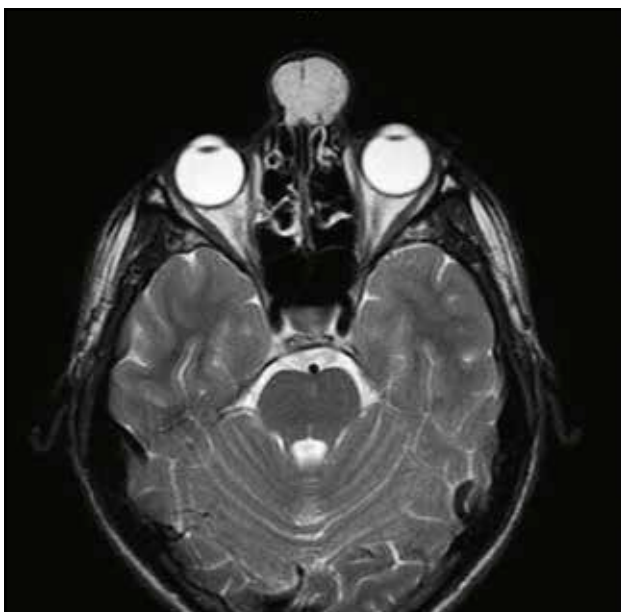During hospitalization, the patient performed a head

and neck native CT scan (Figure 1) that revealed a space replacement process developed at the level of the nasal pyramid, more at the level of the left blade, developed intraosseously; with atrophy by pressure on the cortical bone boundaries, on the nasal process of the jaw, especially the left one; having a diameter of 22/ 25 mm; with the areolar bone structure that sketched the central radial pattern, an aspect suggestive of bone haemangioma. It involved the left nasal cavity, deflected the anterior part of the nasal septum to the right and anteriorly it overcame it, reaching the right nasal blade; internally covered by the mucosa and externally it kept the normal subcutaneous cellular tissue.

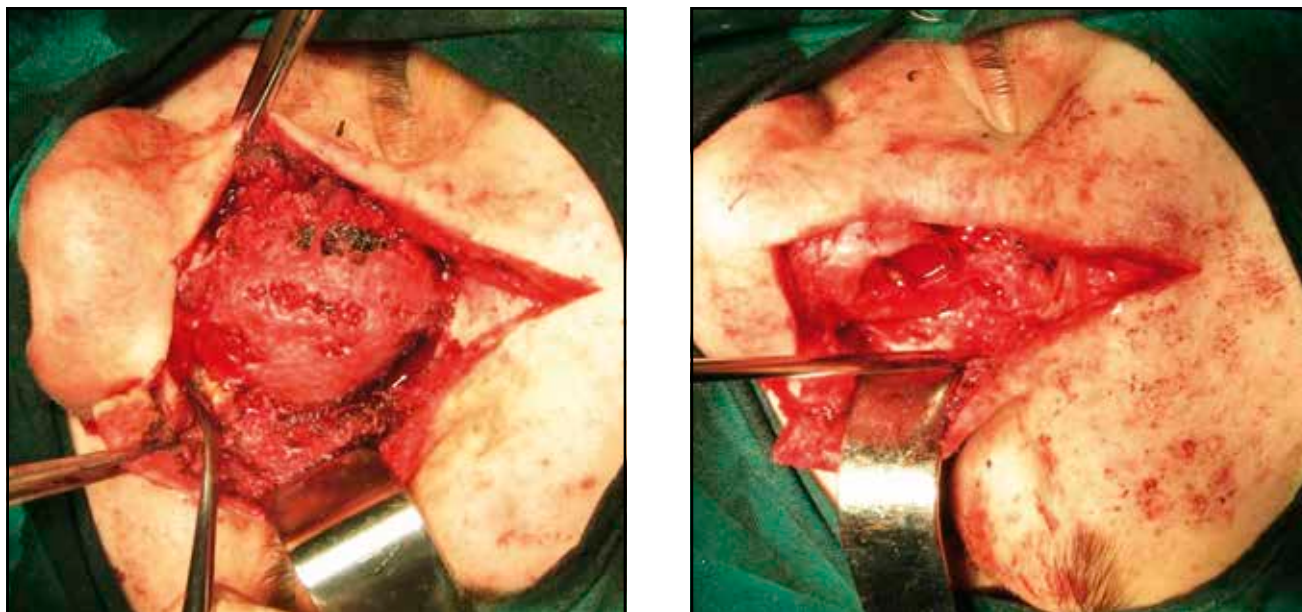
At presentation, the patient was afebrile, with good general condition, normal weight, without palpable lymph nodes in the head and neck region, symmetric chest walls, no wheezing or rhonchi appreciated, with SpO<sub>2</sub> of 98-99%, regular heartbeat, no murmurs or rubs, no jugular venous distention, no cyanosis, clubbing or oedema.

The ENT evaluation revealed at inspection a round oval tumor with approximately 3/3 cm in diameter, located at the level of the nasal pyramid, developed especially on the left side (Figure 2). The nasal endoscopy revealed a slightly hyperaemic tumor, with approximately 1/2 cm in diameter, covered with serous secretions, in contact with the nasal septum, partially obstructing both nasal cavities due to pneumatized superior nasal turbinates (Figure 3). The tympanic membrane was of normal aspect, with present cone-shaped light reflection.

The patient underwent a head and neck native and contrast enhanced MRI (Figure 4) in order to assess the extension of the tumor at the level of the surrounding anatomical structures. No significant differences from the previously performed CT were revealed.



**Figure 4.** Head and neck MRI (axial slices) – Space-replacing process developed at the level of the nasal pyramid outlines a central radial pattern, a suggestive aspect for bone haemangioma



**Figure 5.** Intraoperative appearance of the tumor – 3/3 cm bony tumor with vascular lacunae.

Taking into consideration the symptomatology and the absence of other personal pathological history, no other extensive investigations were made.

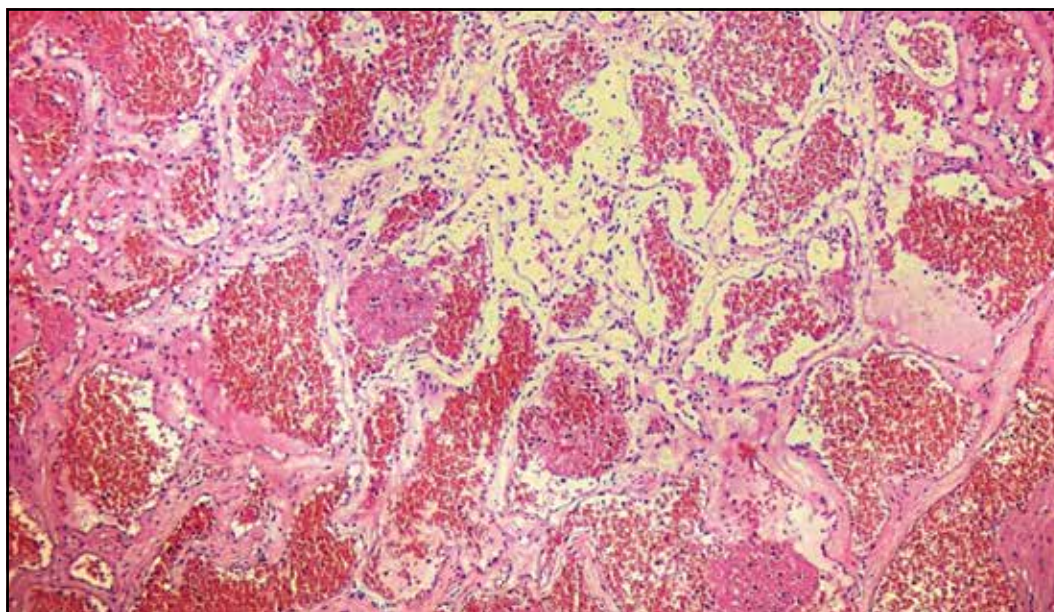
During the hospitalization, the patient received intravenous treatment with antibiotic, corticosteroids, and analgesics periprocedurally. The surgical treatment consisted of complete removal of the tumor under external approach, by lateral rhinotomy (Figure 5). Surgical aspect was of a 3/3 cm bony tumor with vascular lacunae, located at the level of nasal bones, left frontal process of the max-

illa, upper part of the nasal septum, without affecting the lateral nasal cartilage.

The surgery was followed by histopathological analysis of the resected tumor.

The histopathologic examination revealed a proliferation made up of large, dilated vessels, lined by flattened endothelium and numerous agglutinated red blood cells; fibrous septa present and rare fibrinous thrombi; aspect suggestive for cavernous haemangioma (Figure 6).

The patient was monitored for 6 days after the surgery;



**Figure 6.** Magnification 20x: Benign vascular tumor – proliferation made up of large, dilated vessels, lined by flattened endothelium and numerous agglutinated red blood cells; fibrous septa present and rare fibrinous thrombi.

during this time, parenteral treatment was administered. The evolution after the removal of the intraosseous cavernous haemangioma of the nasal pyramid was favourable and the patient was discharged.

Postoperative, 10-year follow-up showed no evidence of tumor relapse (Figure 7).

## DISCUSSIONS

Haemangiomas are benign vascular tumors, which most commonly occur in the skin, soft tissues (muscles, tendons, connective tissue, fatty tissue), synovial tissue or bone. From a pathophysiological point of view, these are abnormal proliferations of endothelial-lined vessels and are labelled as hamartomas rather than as neoplasia<sup>8</sup>.

The cavernous haemangioma of the nasal bones is a rare tumor. Usually, they arise in the mucous membrane of the nasal cavity, the paranasal sinuses and the nasopharynx<sup>14</sup>. Bone haemangiomas generally emerge in the vertebral and calvaria bones<sup>6</sup>, localization in the region of the nasal pyramid being extremely rare. In the medical literature, these types of tumors have also been described at the area of the nasal septum<sup>12</sup>, the inferior nasal turbinate<sup>5</sup>, the middle nasal turbinate<sup>4,7</sup>, the vomer bone<sup>15</sup>, the perpendicular blade of the ethmoid bone<sup>1</sup>, the zygomatic bone<sup>8</sup>, the frontal bone<sup>13</sup>. These lesions can be localized on the surface of the periosteum or inside the cortex.

Although occurrences of multiple cranial cavernomas have been documented, they are often distinct, unique tumors. The dimension varies between 15 - 25 mm at diagnosis, but tumors that reached around 8 cm in diameter have also been reported. The vascularization derives from the vessels of the diploic space. The blood vessels that supply them are usually branches of the external carotid artery. The main arterial sources are represented by the middle and superficial temporal arteries. Inside the lesion, the capillaries are dilated and lined apart by fibrous tissue<sup>13</sup>.

Haemangiomas are benign endothelial lesions with no degenerative potential. The pathogenesis of these tumors remains unclear. Recently, they have been shown to come from late endothelial progenitor cells (EPCs) or differentiated endothelial cells. EPCs are mobilized from the bone marrow or arterial regions to replace dysfunctional endothelial cells and play important roles in blood perfusion into ischemic and tumor tissues using various molecular mechanisms<sup>5</sup>.

The etiology of nasal bone haemangioma is unknown, but previous trauma could act as a predisposing factor<sup>16</sup>. The patient in our case had no history of trauma to the nasal or head area. Also, it has been observed that it affects women more often and the average age of presentation is 40 years<sup>16</sup>. Our patient is a boy, in the second decade of life.



**Figure 7.** Clinical aspect at 10 years after surgery; no evidence of tumor relapse.

### Diagnosis

The diagnosis of intraosseous haemangioma is difficult to establish preoperatively, due to the lack of particular symptoms, such as the purple-blueish colouring seen during nasal examination<sup>7</sup>. Clinically, they are often asymptomatic lesions found incidentally on radiological imaging during an examination performed for another reason<sup>6</sup>. Lesions that are symptomatic manifest as slowly enlarging tumor masses, usually reaching 1-2 cm in diameter<sup>11</sup>. Nasal obstruction may occur due to the mass effect or, more rarely, recurrent epistaxis may also be a sign. In the case of bone haemangiomas, the lesion is covered by normal mucosa, so epistaxis occurs more frequently in the case of mucous haemangiomas. Pain does not usually appear<sup>6</sup>. If pain does occur, it is caused by the haemangioma's enlargement and manifests as a severe headache. The most frequently encountered clinical sign is represented by a solid, symptomatic or not, tumor in the skull<sup>13</sup>. Occasionally, they can cause local tissue destruction and facial asymmetry<sup>10</sup>. In the present case, our patient did not present pain, but the aesthetic aspect was one of the main reasons why he visited our clinic.

Preoperative imaging is mandatory for the correct diagnosis of this affliction, as well as for the evaluation of the tumor formation in relation to the surrounding anatomical structures. Computerized tomography and magnetic resonance imaging are the investigations of election. After these additional investigations, the extent of the lesion, the vascularization, the consistency of the tumor and its relation to the surrounding structures can be established.

Computerized tomography with contrast points out non-homogeneous enhancement in cases of a vascular tumor, whereas the MRI shows hyperintense signal on T2-weighted images. Although imaging investigations help us a lot in the orientation of the diagnosis, it can be established with certainty only after the histopathological examination<sup>17</sup>. Radiological findings usually show a well circumscribed, oval translucent area of expanding nasal bone, containing regular speculated pattern of bone radiating from a central core<sup>18</sup>. It was also described as “soap bubble” pattern with spicules of bone radiating in a “sunburst” manner<sup>11</sup>. Characteristic for this lesion are the bone spicules that extend from the centre to the periphery in the lytic lesion (sunburst pattern or honeycomb)<sup>19</sup>. Sporadically, phleboliths can be found in cavernous haemangiomas<sup>4</sup>. Another paraclinical investigation that can be useful is angiography. This reveals a highly vascularized lesion, without drainage veins. In some cases, preoperative embolization can be used as an adjuvant treatment<sup>13</sup>. Our patient performed preoperatively a cranial CT scan and a cranial MRI, both investigations suggesting the diagnosis of cavernous haemangioma of the nasal bone.

Finally, the diagnosis is suggested by the clinical aspect, the paraclinical investigations and is confirmed by the histopathological examination.

Histopathologically, haemangiomas are divided into three subtypes: capillary, cavernous and mixed. The cavernous haemangiomas are lined by flattened endothelium, which often has some papillae projecting into the lumen, with large spaces between them, filled with blood<sup>6</sup>. Capillary and cavernous subtypes are divided according to the size of the component blood vessels<sup>4</sup>. Most cavernous haemangiomas consist of blood-filled sinusoidal vessels<sup>20</sup>. A proliferation made of mature lamellar bone, with interosseous spaces filled by a fibrovascular lax stroma suggesting a cavernous haemangioma were found upon histopathologic investigation in our case.

#### *Differential diagnosis*

The differential diagnosis includes any firm, slow-growing mass of the skull, with normal overlying skin such as fibrous dysplasia, meningioma, osteoma, osteogenic sarcoma, aneurismal bone cyst, cholesteatoma, osteitis fibrosa cystica, eosinophilic granuloma, dermoid cyst<sup>21</sup>. Nasal dermoids cause unevenness of the skin and do not have the radiological characteristics specific to bone haemangiomas. Sebaceous cysts are localized in the skin, intradermally, without involving the underlying bone. Fibrous dysplasia and ossifying fibroids replace the normal medullary bone with fibrous tissue. Osteomas are lesions of the bone, with a radio dense appearance, which are characterized by the replacement of bone tissue with fibrovascular fatty tissue<sup>22</sup>.

Moreover, haemangiomas developed in the nasal bones must also be differentiated from haemangiomas of the nasal mucosa, which are usually symptomatic, and their surgical approach is completely different<sup>16</sup>.

Obtaining a biopsy sample might be hazardous due to the risk of severe bleeding<sup>23</sup>.

#### *Treatment*

The only method to treat symptomatic haemangioma of the nasal bones is complete surgical excision. Surgical treatment is usually performed by necessity, if the tumor is symptomatic, or for aesthetic reasons, in which case the most common procedure is surgical excision followed by reconstruction of the remaining defect<sup>24</sup>. Because it is bone, hard but fragile enough to be reshaped in the right form, with good long-term outcomes, hydroxyapatite has been utilized extensively in the head and neck region for rebuilding of the cranio-facial bones<sup>25</sup>. Recurrence is extremely rare. There have been described other methods of treatment: angiography with embolization (in the case of highly vascularized tumors), radiation therapy, curettage, injection of sclerosing agents and cryotherapy. Surgical excision “en bloc”, including the edge of the normal bone, is the treatment of choice. The most common intraoperative complication is haemorrhage.

Radiation therapy is very rarely used in the treatment since haemangioma is a benign tumor. This is indicated in cases where excision cannot be performed safely, with the aim of stopping the progression of tumor growth<sup>24</sup>. This therapeutic approach inhibits tumor progression and decreases vascularization, but it has no effect on the lesion's size. Malignant transformation is the greatest risk after radiation treatment<sup>13</sup>.

The surgical procedure, in our case, required performing a lateral rhinotomy to completely remove the tumor under external approach. There were no intraoperative complications.

## CONCLUSIONS

Haemangiomas of the nasal bones are very rare, but they must be taken into account in the differential diagnosis of a slow-growing tumor. The differential diagnosis is very important when this type of haemangioma is suspected, especially considering the atypical location, usually being a diagnosis formulated by excluding other causes.

The particularity of the case is represented by the rare occurrence of central (intraosseous) cavernous haemangioma in the head and neck region, especially at the level of the nasal pyramid, and the age of the patient.

The management of this affliction includes several treatment options. Complete resection with safety margins is the most common and recommended therapeutic approach.

**Conflict of interest:** The authors have no conflict of interest to disclose.

**Contribution of authors:** All the authors have equally contributed to this work.

## REFERENCES

- Graumüller S, Terpe H, Hingst V, Dommerich S, Pau HW. An intraosseous hemangioma in the perpendicular lamina of the ethmoid bone. *HNO*. 2003;51(2):142-5. DOI: 10.1007/s00106-002-0678-9.
- Mocanu H, Mocani AI, Moldovan C, Soare I, Postolache PA, Nechifor A. Rare and unusual benign tumors of the sinonasal tract and pharynx: Case series and literature review. *Exp Ther Med*. 2022;23(5):334. DOI: 10.3892/etm.2022.11263.
- Kadriyan H, Sulaksana MA, Yudhanto D, Ariyani IGAT, Yuliani EA, Ardianti NE, et al. Subcutaneous hemangioma on nasal dorsum: A case report. *J Med Case Rep*. 2020;14(1):128. DOI: 10.1186/s13256-020-02443-4.
- Kim TH, Lim EJ, Lee JK, Lee JG, Han MH. Intraosseous hemangioma of the middle turbinate misdiagnosed as a nasal polyp. *Case Rep Otolaryngol*. 2014;2014:217349. DOI: 10.1155/2014/217349.
- Testa D, Motta S, Massimilla EA, Tafuri D, Russo D, Russo A, et al. Cavernous hemangioma of rhinopharynx: our experience and review of literature. *Open Med*. 2015;10(1):523-8. DOI: 10.1515/med-2015-0089.
- Goomany A, Prowse S, Smith I. Intraosseous cavernous haemangioma of the inferior turbinate. *BMJ Case Rep*. 2015;2015:bcr2015212624. DOI: 10.1136/bcr-2015-212624.
- Akiyama K, Karaki M, Osaki Y, Takeda J, Mori N. Intraosseous cavernous hemangioma of the middle turbinate. *Auris Nasus Larynx*. 2011;38(4):516-8. DOI: 10.1016/j.anl.2010.10.010.
- Pokala A, Devulapally RV, Tejasvi MLA, Nedunooru S. Central hemangioma of Zygoma - A rare case report with CT and MRI features. *Indian J Pathol Microbiol*. 2021;64(2):334-8. DOI: 10.4103/IJPM.IJPM\_707\_20.
- Zizmor J, Robbett WF, Spiro RH, Ganz A, Tawfik B. Hemangioma of the nasal bones: radiographic appearance. *Ann Otol Rhinol Laryngol*. 1978;87(3 Pt 1):360-3. DOI: 10.1177/000348947808700313.
- Parameswaran V, Thirumoorthy C, Sathyamoorthy SKMG, Ramakrishnan P. Differential diagnosis of central hemangioma of maxilla: A rare case report. *J Indian Acad Oral Med Radiol*. 2016;28(2):211-4. DOI:10.4103/0972-1363.195142.
- Kargi E, Babucco O, Hoşnuter M, Babucco B. Hemangioma of the nasal bone: a case report. *Kulak Burun Bogaz İhtis Derg*. 2005;14(1-2):32-4.
- Baki A. Nasal septal cavernous hemangioma. *J Craniofac Surg*. 2018;29(2):e135-e136. DOI: 10.1097/SCS.0000000000004220.
- Sáenz AA, Porto NF, Sánchez MP. Intraosseous cavernous hemangioma: presentation of a clinical case. *Egypt J Neurosurg*. 2018;33(1):22. DOI: 10.1186/s41984-018-0018-3.
- Musat G. Tumorile benigne rinosinusale. In: Popescu I, Ciuce C (su bred.), Sarafoleanu C. (coord.). *Tratat de chirurgie. Editia a II-a. Vol. 1.: Otorinolaringologie si chirurgie cervico-faciala*. Bucuresti. Editura Academiei Romane; 2012, p. 159-89.
- Nakahira M, Kishimoto S, Miura T, Saito H. Intraosseous hemangioma of the vomer: a case report. *Am J Rhinol*. 1997;11(6):473-7. DOI: 10.2500/105065897780914956.
- Masot León B, Escudero Nafá FJ, Ruiz de Azúa Ciria Y, Nieto Ramos H. Cavernous hemangioma of the nasal bones: a case report. *Anales Sis San Navarra*. 2018;41(3):381-5. DOI: 10.23938/ASSN.0370.
- Hamdan AL, Kahwaji G, Mahfoud L, Hussein S. Cavernous hemangioma of the maxillary sinus: a rare cause of epistaxis. *Middle East J Anaesthesiol*. 2012;21(5):757-60.
- Hazra TK, Basu SK, Chowdhury S, Deb P. Haemangioma of the nasal bone. *Indian J Otolaryngol Head Neck Surg*. 2001;53(3):239-42. DOI: 10.1007/BF03028565.
- Atci IB, Albayrak S, Yılmaz N, Uçler N, Durdağ E, Ayden O, et al. Cavernous hemangioma of the parietal bone. *Am J Case Rep*. 2013;14:401-4. DOI: 10.12659/AJCR.889388.
- Adhikary B, Sen S, Banerjee P, Bandyopadhyay S, Mukherjee D, Bandyopadhyay S, et al. Haemangioma of cheek different presentation and management. *Indian J Otolaryngol Head Neck Surg*. 2014;66(2):162-6. DOI: 10.1007/s12070-013-0697-8.
- Kuzeyli K, Usul H, Cakir E, Caylan R, Rei A, Baykal S, et al. Multifocal intradiploic cavernous hemangioma of the skull associated with nasal osteoma. *Acta Neurochir (Wien)*. 2003;145(4):323-6; discussion 326. DOI: 10.1007/s00701-003-0005-6.
- Çaylaklı F, Cagici AC, Hürcan C, Bal N, Kizilkiliç O, Kiroglu F. Cavernous hemangioma of the middle turbinate: a case report. *Ear Nose Throat J*. 2008;87(7):391-3.
- Kilde JD, Rhee JS, Balla AA, Smith MM, Smith TL. Hemangioma of the sphenoid and ethmoid sinuses: two case reports. *Ear Nose Throat J*. 2003;82(3):217-21.
- Dhupar V, Yadav S, Dhupar A, Akkara F. Cavernous hemangioma—uncommon presentation in zygomatic bone. *J Craniofac Surg*. 2012;23(2):607-9. DOI: 10.1097/SCS.0b013e31824cd7c4.
- Koybasi S, Saydam L, Kutluay L. Intraosseous hemangioma of the zygoma. *Am J Otolaryngol*. 2003;24(3):194-7. DOI: 10.1016/S0196-0709(02)32429-3.

