

## LITERATURE REVIEW

# Septal perforations – state of the art

Daniel Lupoi<sup>1,2,3</sup> , Alex Iulian Milea<sup>1</sup> , Andreea Elena Bejenariu<sup>1,2</sup> 

<sup>1</sup>ENT&HNS Department, “Sfanta Maria” Hospital, Bucharest, Romania

<sup>2</sup>“Carol Davila” University of Medicine and Pharmacy, Bucharest, Romania

<sup>3</sup>CESITO Centre, “Sfanta Maria” Hospital, Bucharest, Romania

### ABSTRACT

Septal perforation is a nasal condition discovered incidentally during an ENT clinical examination. Sometimes, patients may experiment epistaxis, septal crusts at the edge of perforation, nasal obstruction, whistling, rhinorrhea or even pain.

Doctors should be familiarized with the etiology of septal perforations in order to apply the best treatment possible. This etiology includes some of the following: iatrogenic, self-injury, drugs, inflammatory diseases, etc. A very good anamnesis and clinical examination should be performed. Also, paraclinical investigations are required depending on the particular situation. Treatment should be individualized and may include conservational techniques or applying of grafts/flaps for closing the septal perforation.

In this article, some of the most frequent causes of septal perforation are reviewed, with some examples from our clinic and short reminder of steps to be taken in this case.

**KEYWORDS:** septal perforation, nasal crusts.

### INTRODUCTION

Nasal septal perforation is an anatomic defect through the nasal septum that separates the two nasal cavities. Usually, septal perforation is discovered incidentally during an ENT clinical examination. A perturbation of the airflow represents an important impairment of the patient's quality of life. The prevalence of a nasal septal perforation varies from 0.9% to 2.1% in the general population<sup>1</sup>. Regarding the location of the perforation, the anterior septal perforation is more frequent (about 90%) than the posterior and superior septal perforation (which are less than 10%)<sup>2</sup>.

Regarding nasal septal perforation pathogenesis, four stages have been reported: in the first stage, a local inflammatory response determines mucosal harm followed by swelling, erythema, crusts (Figure 1); in the second one, the inflammatory cells penetrate the submucosal layer and the vascularization of that region decreases, inducing cartilage ischemia and destroying the submucosal and mucosal layers; in the third stage, necrosis and cartilage ulceration secondary to abnormal recovery of the mucosal layer appear; in the last stage, an

atrophic epithelium covers the edges of the perforation which is more predisposed to bleeding or crusts. Inadequate nasal hygiene may lead to local infections and persistent perichondritis as well, which can enlarge the nasal septal perforation and worsen it<sup>3</sup>.

### ETIOLOGY OF NASAL SEPTAL PERFORATIONS

There are many causes of nasal septal perforation (Table 1). A detailed anamnesis should point out any nasal trauma or nasal surgery, any systemic disorder, self-injury, use of cocaine, overuse of nasal steroids or vasoconstrictor sprays, smoking or other aerosol irritants exposure. Etiology has an important role regarding the size, severity of manifestations and management of nasal septal perforations.

#### Nasal trauma

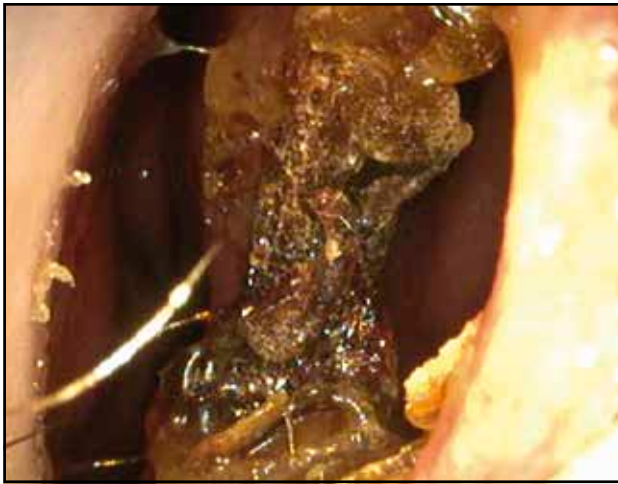Nasal trauma with fractures is usually secondary to fights, sports or accidents. The direction of the force to the nose leads to different forms of fractures. A force from the frontal

**Corresponding author:** Andreea Bejenariu, MD, ENT&HNS Department, “Sfanta Maria” Hospital, 37-39 Ion Mihalache Blvd., District 1, Bucharest, Romania

**ORCID:** <https://orcid.org/0000-0001-6134-9239>

**e-mail:** andreeaelena.bejenariu@yahoo.com

**Received for publication:** September 20, 2022 / **Accepted:** November 30, 2022

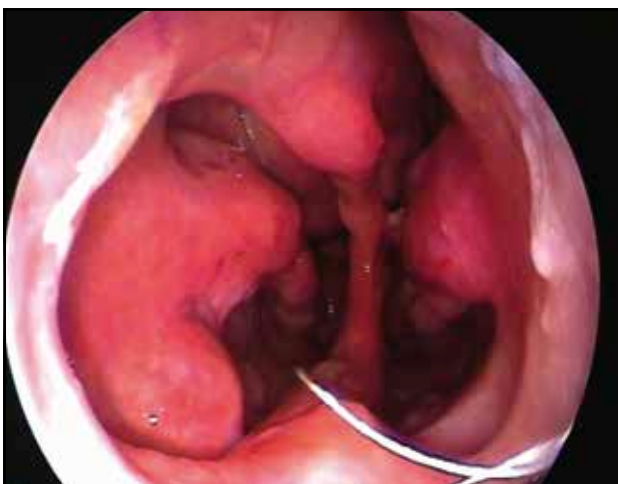


**Figure 1.** Crusts on the edge of the septal perforation.

direction may lead to a simple fracture of the nasal bones or the whole nose may be crushed, it depends on the strength of the blow. A lateral force may push down one of the nasal bone or both of them, depending on the strength of the blow. This force may provoke nasal septal displacement, or, in some cases, it may twist the nose. A superior force from below may determine dislocation of the quadrangular cartilage, septal fractures. If the nasal septal fractures are not treated, patients may develop infections followed by perforations. If a septal haematoma is not drained, it may be infected and an abscess may appear, followed by a nasal septal perforation<sup>1,4</sup>. Traumatic nasal septal perforation occurs in almost 39% of patients with nasal perforation<sup>4</sup>.

#### **Iatrogenic nasal septal perforations**

Iatrogenic nasal septal perforation appears most often after septoplasty (Figure 2), but this may be prevented with an appropriate subperichondrial layer dissection. Nasal septal perforation may occur in up to 8% of pa-



**Figure 2.** Iatrogenic septal perforation (margins without inflammatory signs).

**Table 1. Etiology of nasal septal perforations.**

<b>Trauma</b>	Nasal fractures, self-injury (nose picking, foreign bodies), septal piercing, septal haematoma
<b>Drugs</b>	- Steroid nasal spray - Vasoconstrictor nasal spray - Cocaine - Bevacizumab
<b>Chemical irritants</b>	- Chlorines and bromines - Sulfuric acid, chromic acid, hydrochloric acid - Chemical and industrial dust - Agricultural aerosolized dust - Glass - Cement - Dust - Salt - Cyanide - Arsenical - Heavy metal
<b>Iatrogenic</b>	- Nasal surgery - Septoplasty - Sinus surgery - Turbinate surgery - Rhinoplasty - Septal cauterization - Septal packing - Septal splinting - Cryosurgery - Trans-sphenoidal hypophysectomy - Postoperative suctioning - Nasotracheal intubation
<b>Inflammatory diseases</b>	- Vasculitis - Sarcoidosis - Collagen vascular disease - Wegener granulomatosis - Chron disease
<b>Neoplasia</b>	- Squamous cell carcinoma - Adenocarcinoma - Midline destructive granuloma - Metastatic carcinoma
<b>Infections</b>	- Syphilis - Rhinoscleroma - Tuberculosis - Lepromatous leprosy - Rhinosporidiosis - Multiple fungal species: Mucor mycosis; Histoplasma capsulatum

tients after septoplasty<sup>5</sup>.

Nasal septal perforation may also occur after septal cauterization, radiotherapy and after long term nasal packing<sup>5,6</sup>.

#### **Drugs-related septal perforations**

Nasal septal perforation may appear secondary to long-term local use of vasoconstrictors or also cocaine, which leads to osteocartilaginous necrosis through long-term deprivation of oxygen to the nasal septum<sup>7</sup>.

There were reported cases of septal nasal perforation secondary to intranasal drug abuse such as cocaine, stimulants, insufflation of heroin or benzodiazepines. Cocaine produces vasoconstriction and may cause necrosis in the nasal mucosae, cartilage and also damaging the osseous portion of the nasal septum. Impurities found in cocaine (mannitol, amphetamines, talcum powder) may cause an inflammatory local reaction which leads to granulation tissue, deterioration of the ciliary function and mucosal erosion, contributing to the perforation pathogenesis<sup>8,9</sup>.

Nowadays, there are a lot of people suffering from chronic rhinitis because of the increasing number of patients with allergies and more and more people use intranasal steroids. Intranasal steroids lead to nasal septal perforation less than intranasal vasoconstrictors. Although many authors describe the absence of atrophy of the nasal mucosa or damage in local vascularization after long-term use, a nasal septal perforation may occur<sup>10,11</sup>.

Desmopressin is an antidiuretic peptide hormone, a synthetic analogue of vasopressin which increases tissue plasminogen activator, factor VIII, and plasma von Willebrand factor. It is used for diseases associated with bleeding (von Willebrand disease or haemophilia A), uraemia, diabetes insipidus or nocturnal enuresis, and it may be administered orally, intravenously, sublingually or by intranasal spray. When intranasal desmopressin spray was used for less than 6 months, no septal mucosa damages were observed, but after long time administration, nasal septal perforation may occur; only one case was reported in the literature<sup>12</sup>.

There are reported some cases with nasal septal perforation after systemic bevacizumab treatment for ovarian cancer, breast (7% of cases)<sup>13</sup> and colorectal cancer (1% of cases)<sup>14</sup>, bevacizumab being a monoclonal antibody inhibitor of the vascular endothelial growth factor A. This medication is recommended in late-stage cancers and epistaxis which appears in patients with hereditary haemorrhagic telangiectasia<sup>15,16</sup>. The possible mechanism of bevacizumab consists in decreasing angiogenesis by inhibition of the vascular endothelial growth factor A. Factors that contribute to nasal septal perforation are mucositis, poor wound recovery, immunosuppression, risk of infection<sup>17</sup>.

#### **Nasal septal perforation secondary to nasal foreign body**

Nasal septal perforation secondary to nasal foreign body, such as jewellery magnets, may cause constriction of the blood supply in the septal mucosa associated with crusts, ulcerations, necrosis. Usually, these magnets are made with neodymium powder, boron and iron. A magnet with neodymium powder is stronger than one with iron only and produces more damage<sup>18</sup>.

#### **Chemical occupational exposure**

Chemical occupational exposure represents a frequent cause of nasal septal perforation. For example, approximately 20-30% of patients exposed to chromic acid present nasal septal perforation, with an exposure time before presentation between 6 to 12 months, depending on the intensity of exposure<sup>19,20</sup>.

Nasal septal perforation can appear secondary to Nickel exposure. It was observed that Nickel plating and refinery workers have a higher risk of sinusitis, rhinitis, nasal septal perforation, fibrosis, asthma and emphysema secondary to long term exposure to contaminated air<sup>21</sup>.

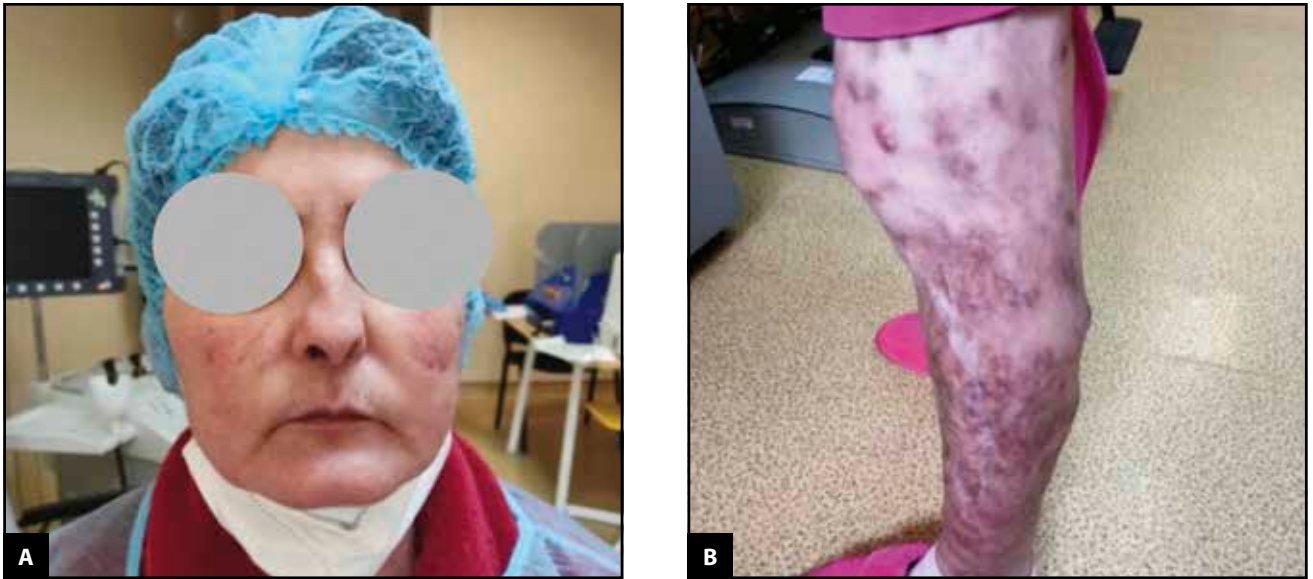#### **Inflammatory diseases**

Inflammatory diseases, such as systemic lupus erythematosus, sarcoidosis, Crohn's disease, Wegener granulomatosis, are an important cause of nasal septal perforation.

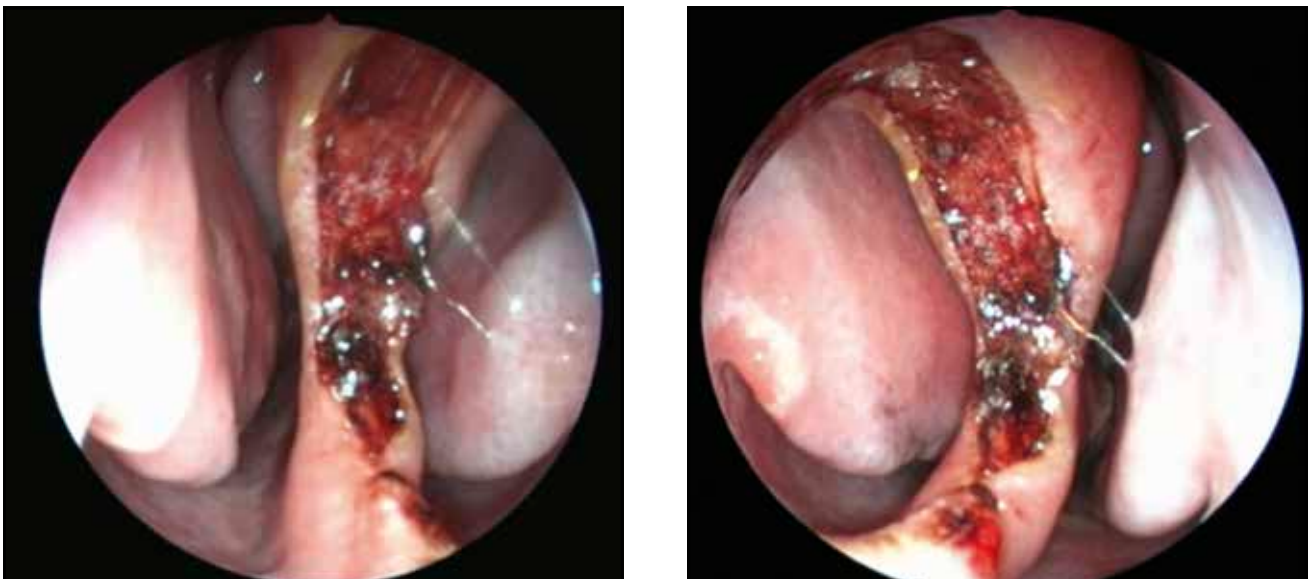
Sarcoidosis is a chronic granulomatous multisystemic disorder, which affects young and middle-aged adults. Usually, patients present with pulmonary infiltration or fibrosis, bilateral hilar adenopathy, inflammatory eye disease (uveitis) and skin lesions (erythema nodosum). In regard to pathogenesis, sarcoidosis having an unknown etiology is supposed to be a result of an exaggerated granulomatous reaction after exposure to environmental agents in genetically susceptible individuals<sup>22</sup>. Sinonasal involvement may occur as an isolated disease to the nose and sinuses or may be as part of a systemic disease (in up to 1% of patients)<sup>23</sup>. The most frequent symptoms are rhinorrhea, nasal obstruction, epistaxis, anosmia, crusts and on clinical examination one may identify edematous, erythematous, hypertrophied, friable nasal mucosa; also, crusts with small erythematous or pale nodules, nasal septal perforation and saddle nose deformity may be observed in severe cases. The diagnosis is based on clinical findings and noncaseating granulomatous inflammation obtained by biopsy especially from lung or other organs involved<sup>22-24</sup>.

Systemic lupus erythematosus is an autoimmune disease defined by the production of many autoantibodies and a diversity of clinical manifestations. This disease mainly affects young women. There are described some pathogenic mechanisms such as: inflammatory, vasculitic or autoimmune mechanisms. Patients may present with head and neck characteristics such as the malar rash localised on the face with a "butterfly shape", shallow ulcerations, commonly on the hard palate, hyperkeratotic, lichen planus-like plaques on the palate and buccal mucosa, tinnitus with or without hearing loss. They may complain about sinonasal symptoms including nasal itchiness, nasal congestion, nasal dryness or rhinorrhea. Clinical examination may identify the involvement of the skin from the nose and vestibule; the nasal mucosa may be affected, patients presenting ulcerations, and rarely with nasal septal perforation and crusts at the edges of the perforation. In systemic lupus erythematosus, nasal septal perforation may be as a consequence of vasculitis or ischemia with chondrolysis<sup>24-26</sup>.

There are some cases reported with pyoderma gangrenosum associated with ENT manifestations, such as: nasal septal perforation and oropharyngeal ulcers. In the histopathological samples from nasal mucosa, an infiltrate with neutrophils was observed – an ordinary characteristic of pyoderma gangrenosum. Pyoderma gangrenosum should be differentiated from other neutrophilic diseases: Behcet's disease, Chron's disease<sup>27</sup>.



**Figure 3.** A. Nasal dysmorphism; B. Calves with subcutaneous haematomas.



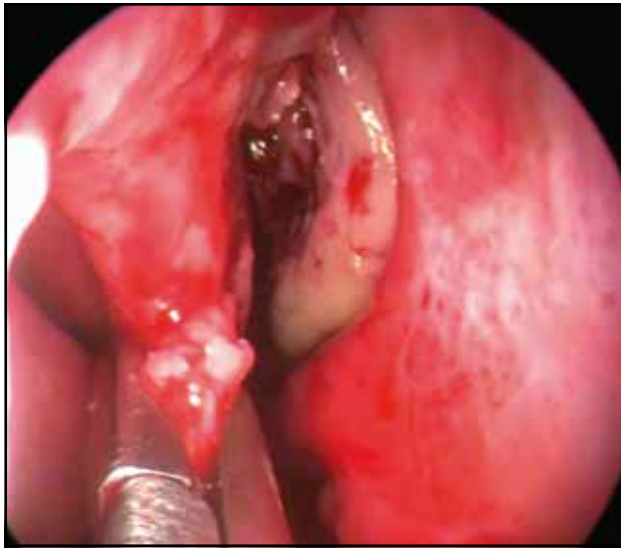
**Figure 4.** Nasal septal perforation (nasal endoscopic view).

Regarding disorders with neutrophilic infiltrate, we report a case of progressive neutrophilic granulomatous dermatitis and sero-negative rheumatoid arthritis with extraarticular manifestations, who presented to our clinic for nasal manifestations. The patient complained about persistent rhinorrhea. The clinical examination revealed nasal dysmorphism (Figure 3A), due to the systemic neutrophilic granulomatous dermatitis, and anterior nasal septal perforation, with 2-3 cm diameter, covered by hematic crusts and mucous secretions (Figure 4). The general clinical examination pointed out multiple subcutaneous haematomas in the calves (Figure 3B). Laboratory tests revealed normocytic

hypochromic anemia, increased level of erythrocyte sedimentation rate (18.8%; N:10-16.5%), mild leukocytosis, increased levels of C reactive protein (354.95mg/dL; N: 0-5mg/dL), decreased level of IgG (469.36mg/dL; N:700-1600mg/dL), antinuclear antibodies (Elisa) within normal range (0.2 Index; N: Index<1.0).

The patient was under immunosuppressive treatment for the underlying disease with azathioprine and corticosteroids. For the nasal manifestations, the recommendations included topical emollients.

Crohn's disease is a chronic inflammatory bowel disorder, which may affect any part of the gastrointestinal tract, but also



**Figure 5.** Nasal biopsy from the edges of perforation performed under nasal endoscopy.

extraintestinal organs can be affected (most frequently skin, joints, eye, liver, anus are targeted). Involvement of the upper aerodigestive tract is very uncommon. There are only some cases described in the literature with head and neck manifestation<sup>28</sup>. Among these, there were reported up to 6 cases of Chron's disease with nasal manifestations such as nasal congestion, nasal obstruction, crusting or nasal perforation (2 cases with nasal septal perforation). The histopathological sample from the nasal mucosa surrounding the perforation identified inflammatory granulomatous tissue and nonspecific mixed inflammation<sup>28-32</sup>. It was observed that patients with Chron's disease and nasal septal perforation had severe or uncontrolled disease<sup>33</sup>.

In Wegener granulomatosis, pharyngeal ulcers and nasal septal perforation may also occur, but in this disorder, the histological characteristics are granulomas and necrotizing vasculitis and also c-ANCA antibodies are present in serological examination. Sinonasal manifestations are frequent in Wegener granulomatosis. Usually, patients complain about nasal obstruction, smell dysfunction, purulent rhinorrhea, epistaxis, nasal dryness and pain. On the physical examination, nasal crusts are usually observed and, occasionally, anterior nasal septal perforation, which are secondary to vasculitis of the Kiesselbach's area. Nasal septal perforation may occur in about 4% of patients with granulomatosis with polyangiitis<sup>34</sup>. In advanced stages of the disease, as a consequence of extensive necrosis of the septal cartilage, a deformation of the nose may occur such as "saddle nose"<sup>27,34</sup>.

#### **Nasal septal perforation in infectious diseases**

Tuberculosis is a disease caused by *Mycobacterium tuberculosis* and commonly affects lungs, but other organs may be affected in up to one third of patients<sup>35</sup>. Primary nasal tuberculosis is a rare manifestation. Only one case was manifested with nasal septal perforation from 29 cases reported by Khan et al. in 2017 with primary nasal tuberculosis<sup>36</sup>. It is uncom-

mon for the nasal mucosa to be infected by *mycobacterium tuberculosis* because of its protective properties (filtering produced by nasal vibrissae and bactericidal effect of nasal secretions); this is why it is believed that primary nasal tuberculosis occurs on a damaged mucosa or atrophic mucosa by inhalation of infected particles or by self-traumatic inoculation. Usually, in nasal tuberculosis, the cartilaginous portion of the nasal septum and the inferior turbinates are involved, the symptoms presented by the patients being represented by nasal obstruction, crusts, rhinorrhea, epistaxis, ulcerous lesions and nasal septal perforation<sup>35,36</sup>.

The diagnosis of primary nasal tuberculosis can be difficult because the clinical manifestations are frequently nonspecific. Culture isolation from nasal secretions or damaged tissue gives the positive diagnosis, but, for a precise diagnosis, a biopsy from the affected tissue is also recommended. A nasal biopsy (Figure 5) from the edges of the perforation is important for the diagnosis revealing chronic inflammation with necrosis, caseating granulomas, Langhans-type giant cells and with Ziehl-Neelsen staining, acid-fast staining bacilli may be identified<sup>37,38</sup>.

Patients with human immunodeficiency infection may present with different head and neck manifestations. In the sinonasal area, they may present with acute or chronic rhinosinusitis, nasal polyps or nasal tumors (Kaposi's sarcomas, nasal lymphomas). Nasal septal perforation in patients with human immunodeficiency infection was assigned to non-Hodgkin's lymphoma, varicella zoster infection or due to *Histoplasma capsulatum* infection. From 10 patients with *histoplasma capsulatum* and nasal manifestations, only 2 cases had septal perforation without other organ involvement and 4 cases had septal perforation pulmonary symptoms<sup>39</sup>. Patients may complain about nasal obstruction, purulent rhinorrhea. The diagnosis of human immunodeficiency infection is based on clinical features and identification of HIV antibodies by immunological assay ELISA (enzyme-linked immunosorbent assay) and it is confirmed by Western blot tests which detect the specific viral proteins<sup>23,39,40</sup>.

Syphilis is an infection caused by the gram-negative spirochete *Treponema pallidum*. The primary way of acquisition is direct sexual contact, but it can be transmitted congenitally or by close contact with an active lesion through small fissures in the epithelial surface. The manifestations depend on the stages of the disease. Regarding nasal manifestations, during the three stages of the disease may appear: in primary stage, the manifestations are not very evident, but in some patients were described nasal vestibule chancres; in the secondary stage, nasal involvement may manifest as acute rhinitis, patients presenting with thick rhinorrhea and inflammation of the nasal mucosa<sup>41</sup>; the tertiary stage may manifest with nasal septal perforation, saddle nose deformity due to destruction of the nasal cartilage, gumma of the nose (which is a granulomatous lesion that commonly affects the mucocutaneous layer and skeletal system). The diagnosis of syphilis is based on clinical findings, darkfield microscopy (which is the gold standard technique

of diagnosis in primary, secondary and early congenital syphilis), serologic tests (nontreponemal rapid plasma reagin and specific treponemal antibody tests)<sup>41,42</sup>.

### Neoplasms

Nasal natural killer/T-cell lymphoma, a rare entity, known as lethal midline granuloma, is an extranodal tumor with origin in the natural killer cells. Pathologically, this tumor is characterized by a diffuse infiltrate of lymphoma cells with different size, pleomorphic small or large cells with mitosis and different inflammatory cells. This tumor is characterized by progressive destructive lesions with extensive necrosis, localized in the nasal cavity and paranasal sinuses. Usually, patients present with nasal obstruction, rhinorrhea, epistaxis, nasal crusts and particular B symptoms such as weight loss, fever, night sweats. In evolution, they present an ulcerative and destructive process of the nasal cartilages and bones, with friable mucosa, crusts, cartilage loss and infiltration of the adjacent area with facial extension may happen. Nasal natural killer cell lymphoma has a poor prognosis because of its rapid local progression and the presence of distant metastases. Diagnosis of natural killer/t-cell lymphoma is based on clinical characteristics, histological features, immunophenotypic and genotypic characteristics. It is important to be differentiated from other nasal malignancies<sup>43</sup> (Figure 6).

## DIAGNOSIS CRITERIA OF NASAL SEPTAL PERFORATIONS

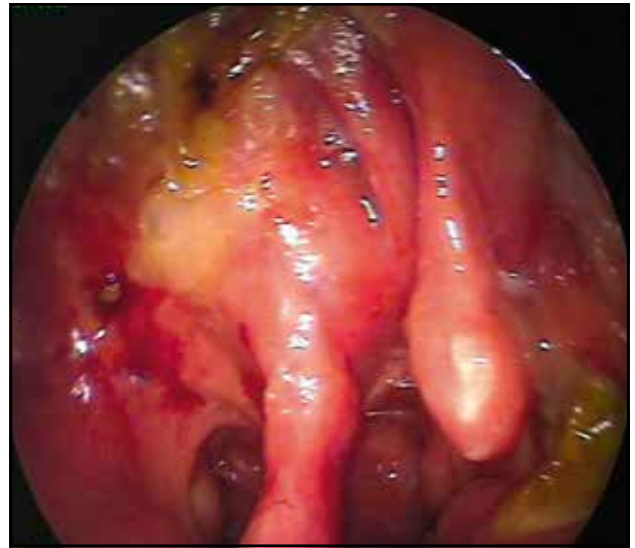
### Clinical diagnosis

Clinical diagnosis is based on a detailed anamnesis which may reveal information about symptoms and possible causes of perforations and an objective examination. Patients with anterior perforations present bleeding, septal crusts at the edge of perforation, nasal obstruction, whistling, rhinorrhea or even pain<sup>44</sup>. Posterior septal perforations are often free of symptoms because of a better humidification. Nasal obstruction may appear because of dried crusts or turbulent airflow, when the lamellar airflow is disturbed. Patients present rhinorrhea when the nose is dry and increase secretions, trying to irrigate itself. In small perforations, whistling may appear because of the noise produced by airflow through a small window<sup>45</sup>.

Anterior rhinoscopy and nasal endoscopy may point out crusts and enlarged turbinates. The crusts should be removed, and the turbinates should be decongested to have a good view of the entire nasal septum and to identify the position of the septal perforation and its circumferential size. Crusts observed not only beside the edge of the perforation, but also on the turbinates and over the entire septum, occur often in patients with granulomatosis, vasculitis or cocaine use. It is important to palpate the septum with an applicator to check the presence of the cartilage and its extension<sup>44,45</sup>.

### Laboratory tests

There are a series of laboratory tests that should be considered in patients with nasal septal perforation. The complete



**Figure 6.** Endoscopic examination of nasal fibrosarcoma multimodally treated – surgical resection (including most part of the nasal septum), followed by chemoradiotherapy – in a 29-year-old patient with history of several rhinosinusal interventions (septoplasty and nasal polypectomy in 2004; silicone septal button placement and ablation of endonasal fibromatous mesenchymal tumor in 2008).

cell blood count may reveal anemia, leukocytosis, thrombocytosis, eosinophilia (which is increased in eosinophilic granulomatosis with polyangiitis), an elevated erythrocyte sedimentation rate. Increased levels of C reactive protein may indicate an inflammation. Hypercalcemia and/or hypercalciuria and elevated levels of angiotensin-converting enzyme (ACE) can indicate the presence of sarcoidosis. The rheumatoid factor elevated level may help diagnose mixed connective tissue diseases, scleroderma, lupus, rheumatoid arthritis. Specific antibodies (antinuclear antibodies, anti ADN, anti-Ro) are found in systemic lupus erythematosus, while anti-neutrophil cytoplasmic autoantibodies (C-ANCA) suggest the presence of Wegener granulomatosis<sup>32,34</sup>.

When a specific infection is suspected, a purified protein derivative (PPD) test, the Mantoux tuberculin skin test and sputum cultures can be performed to identify tuberculosis. Serology tests such as rapid plasma reagin, venereal disease research laboratory test (VDRL), unheated serum reagent test (USR), which are nontreponemal tests, associated with the treponemal tests (fluorescent treponemal antibody absorption (FTA-ABS), Microhemagglutination Assay for *Treponema pallidum* Antibodies (MHA-TP)) and darkfield microscopy should be performed to detect syphilis<sup>37,41</sup>. An infection with the human immunodeficiency virus can be identified detecting retroviral antibodies by the enzyme-linked immunosorbent assay (ELISA) test and then, to confirm the presence of retroviral proteins, Western blot analysis should be performed<sup>23,39</sup>.

### Imaging

Chest radiography may show lung parenchymal abnormalities including nodule(s), consolidation, and cavities

which indicate tuberculosis. Bilateral hilar adenopathy is the most particular radiological finding in sarcoidosis.

Sinus computer tomography is useful to find out the location of the nasal septal perforation and its relationship with vascular structures for potential pedicles for the reconstruction, to analyse the osteocartilaginous portion in the remaining septum and to measure the perforation size.

#### Histopathological diagnosis

Nasal biopsy is recommended in those patients with nasal septal perforations, without a clear etiology, to identify a systemic granulomatous disease or vasculitis or a carcinoma. Chronic inflammation with necrosis, caseating granulomas, Langhans-type giant cells and with Ziehl-Neelsen staining, acid-fast staining bacilli may be identified, and it suggest tuberculosis<sup>37,38</sup>. A histology sample that reveals noncaseating granulomatous inflammation is characteristic for sarcoidosis<sup>22,23</sup>.

A nasal septal biopsy may reveal a necrotising granulomatous inflammation containing giant multinucleated cells and small vessel vasculitis, which is characteristic for Wegener granulomatosis<sup>34</sup>. This aspect should be differentiated from other granulomatous disorders, such as pyoderma gangrenosum (noted by an infiltrate with neutrophils)<sup>27</sup> and Chron's disease (characterized by inflammatory granulomatous tissue and nonspecific mixed inflammation)<sup>28,29</sup>. In T-cell lymphoma, histology examination may show necrosis with or without angiocentric infiltrates, but, to complete the diagnosis, immunophenotyping is required. This should include cytotoxic T-cell-associated antigens and/or natural killers' cells. The most frequent cell phenotype is CD2+, surface CD3-, and CD56+ and cytoplasmic CD3+<sup>46</sup>.

## TREATMENT OF NASAL SEPTAL PERFORATIONS

The treatment of nasal septal perforation should be taken into consideration in all cases, but particularly in patients with quality of life impairment. In the beginning, when the patients have symptoms, the treatment is conservative. Before starting the treatment, the cause of the perforation should be investigated. Initially, the disease that led to the nasal septal perforation should be treated. In patients with exposure to drugs or occupational irritants, the prevention is important. Asymptomatic perforations, usually those from the posterior part of the nasal septum with well-healed edges, rarely need treatment<sup>1,47-50</sup>.

Medical treatment is helpful in relieving symptoms. For patients with crusts, it is important to avoid self-nose picking and to increase the nasal hygiene by irrigation with saline solutions, local application of topical emollients and antibiotic ointments.

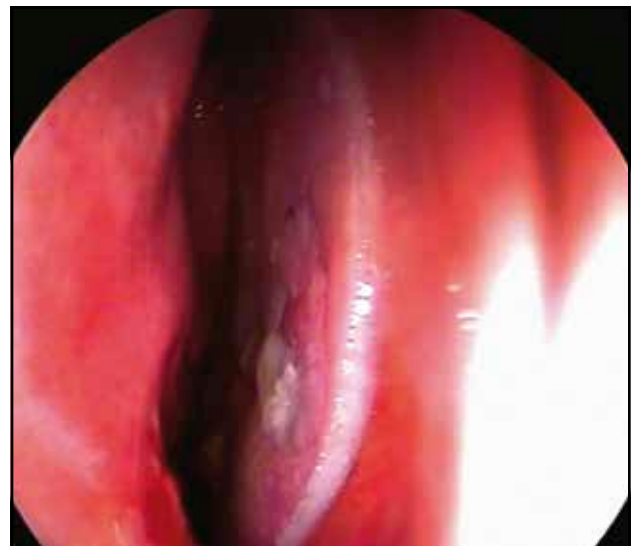Evaluation of the nasal septal perforation consists in location, size, edges of the perforation and colouring (pale colour of the mucosa indicates poor vascularization). It is important to identify if there is septal cartilage between mu-

coperichondrial flaps or not, in order to establish the need for cartilage graft.

An alternative technique to surgical closure of the nasal septal perforation is the insertion of a nasal septal prosthesis (button) made from silicone, acrylic or plastic (Figure 7). The nasal septal button can be placed under local anaesthesia. Some contraindications of this procedure are described: presence of acute infection with osteitis, very large perforations, carcinoma, chronic disease such as Wegener granulomatosis. Possible complications have been related to nasal septal buttons: epistaxis, pain, crusts, enlargement of the perforation<sup>47,48</sup>. Dose et al. reported that in 67% of patients the septal button was removed four years after placement because of dislodging, stenosis, crusting, pain, infection or secretion<sup>48</sup>.

The surgical treatment is indicated in patients with refractory symptoms despite a proper conservative treatment. There are described several techniques to repair the nasal septal perforation with free grafts and rotation flaps, grafts from temporal fascia, inferior turbinate flaps, advancement and suture of the perforation's edges; conchal cartilage and perichondrium, mastoid periosteum; tragal cartilage, perichondrium and temporal fascia<sup>51</sup>. There are some surgical approaches that may be used, including the endonasal technique, which may be assisted by endoscope, sublabial or facial degloving and open rhinoplasty<sup>49</sup>.

It was reported that the endoscopic endonasal approach is performed more often in small perforations, allowing a good access to the posterior part of the nasal septum and avoiding the requirement for an external incision. In symptomatic patients, a perforation smaller than 1.5cm in diameter may be closed through endonasal approach with bilateral mucosal flap advancement and mastoid graft with periosteum<sup>50</sup>. The external rhinoplasty approach allows a good visualization of the septal perforation, but may be problematic



**Figure 7.** Septal button.

because of the transcolumellar incision needed in this technique. Sublabial and midfacial degloving procedures are efficient but more ample techniques and are reserved for perforations wider than 2 cm in diameter<sup>52,53</sup>.

## CONCLUSIONS

In conclusion, it is important to identify and to control the etiology of the nasal septal perforation before considering the nasal septal perforation repair technique. A risk factor in healing failure may be the etiology of nasal septal perforation and the risk is higher in patients without a known cause.

**Conflict of interest:** The authors have no conflict of interest.

**Contribution of authors:** All the authors have equally contributed to this work.

## REFERENCES

- Gold M, Boyack I, Caputo N, Pearlman A. Imaging prevalence of nasal septal perforation in an urban population. *Clin Imaging*. 2017;43:80-2. DOI: 10.1016/j.clinimcag.2017.02.002.
- Sardana K, Goel K. Nasal septal ulceration. *Clin Dermatol*. 2014;32(6):817-26. DOI: 10.1016/j.clindermatol.2014.02.022.
- Belmont JR. An approach to large nasoseptal perforations and attendant deformity. *Arch Otolaryngol*. 1985;111(7):450-5. DOI: 10.1001/archotol.1985.00800090064010.
- Becker DG. Nasal and septal fractures. [Internet]. Medscape. [update Aug 01, 2022]. Available from: <https://emedicine.medscape.com/article/878595-overview#a7>.
- Kim DW, Egan KK, O'Grady K, Toriumi DM. Biomechanical strength of human nasal septal lining: comparison of the constituent layers. *Laryngoscope*. 2005;115(8):1451-3. DOI: 10.1097/01.mlg.0000168579.94187.f6.
- Yildiz E, Ulu S, Kahveci OK. What are the factors leading to nasal septal perforations after septoplasty? *J Otolaryngol Rhinol*. 2019;5(3):065. DOI: 10.23937/2572-4193.1510065.
- Keyserling HF, Grimme JD, Camacho DLA, Castillo M. Nasal septal perforation secondary to rhinitis medicamentosa. *Ear Nose Throat J*. 2006;85(6):376-9.
- Ballage A, El Harti M, Naceur S, Rouadi S, Abada RL, Roubal M, et al. Nasal septum perforation due to cocaine abuse. *SAJ Case Rep*. 2017;4(3):302.
- Zhang D, Patel KB, Cass LM, Foster AE, Guntupalli L, Brunworth JD. Heroin-induced nasal necrosis and septal perforation. *Acta Oto-Laryngologica Case Reports*. 2017;2(1):145-9. DOI: 10.1080/23772484.2017.1379354.
- Cervin A, Akerlund A, Greiff L, Andersson M. The effect of intranasal budesonide spray on mucosal blood flow measured with laser Doppler flowmetry. *Rhinology*. 2001;39(1):13-6.
- Brown HM, Storey G, Jackson FA. Beclomethasone dipropionate aerosol in treatment of perennial and seasonal rhinitis: A review of five years' experience. *Br J Clin Pharmacol*. 1977;4(Suppl 3):283S-6S. DOI: 10.1111/j.1365-2125.1977.tb04522.x.
- Brake DA, Hamilton GS 3rd, Bansberg SF. Nasal septal perforation due to desmopressin nasal spray use. *Ear Nose Throat J*. 2021;1455613211026425. DOI: 10.1177/01455613211026425.
- Maillez A, Baldini C, Van JT, Servent V, Mallet Y, Bonnetterre J. Nasal septum perforation: a side effect of bevacizumab chemotherapy in breast cancer patients. *Br J Cancer*. 2010;103(6):772-5. DOI: 10.1038/sj.bjc.6605828.
- Ramiscal JAB, Jatoi A. Bevacizumab-induced nasal septal perforation: incidence of symptomatic, confirmed event(s) in colorectal cancer patients. *Acta Oncol*. 2011;50(4):578-81. DOI: 10.3109/0284186X.2010.537692.
- Shih T, Lindley C. Bevacizumab: an angiogenesis inhibitor for the treatment of solid malignancies. *Clin Ther*. 2006;28(11):1779-802. DOI: 10.1016/j.clinthera.2006.11.015.
- Chen S 4th, Karnezis T, Davidson TM. Safety of intranasal Bevacizumab (Avastin) treatment in patients with hereditary hemorrhagic telangiectasia-associated epistaxis. *Laryngoscope*. 2011;121(3):644-6. DOI: 10.1002/lary.21345.
- Geltzeiler M, Steele TO. Nasal septal perforation secondary to systemic bevacizumab. *Am J Otolaryngol*. 2017;38(3):354-5. DOI: 10.1016/j.amjoto.2017.01.018.
- Shermetaro C, Charnesky M. Pediatric nasal septal perforation secondary to magnet misuse: a case report. *Ear Nose Throat J*. 2007;86(11):675-6.
- Castano R, Theriault G, Gaurin D. Categorizing nasal septal perforations of occupational origin as cases of corrosive rhinitis. *Am J Ind Med*. 2007;50(2):150-3. DOI: 10.1002/ajim.20419.
- Kuo HW, Lai JS, Lin TI. Nasal septum lesions and lung function in workers exposed to chromic acid in electroplating factories. *Int Arch Occup Environ Health*. 1997;70(4):272-6. DOI: 10.1007/s004200050218.
- Bolek EC, Erden A, Kulekci C, Kalyoncu U, Karadag O. Rare occupational cause of nasal septum perforation: Nickel exposure. *Int J Occup Med Environ Health*. 2017;30(6):963-7. DOI: 10.13075/ijomh.1896.01019.
- Kunadu A, Kataria YP. Nasal perforation: a rare complication of sarcoidosis. *Am J Respir Crit Care Med*. 2020;201:A5007. DOI: 10.1164/ajrccm-conference.2020.201.1\_MeetingAbstracts.A5007.
- Alobid I, Guilemany JM, Mullol J. Nasal manifestations of systemic illnesses. *Curr Allergy Asthma Rep*. 2004;4(3):208-16. DOI: 10.1007/s11882-004-0028-y.
- Harris JP, Weisman MH. Head and neck manifestations of systemic disease. 1st Edition. CRC Press; 2007.
- Thomas J, Gopinath P. Nasal septal perforation in systemic lupus erythematosus. *Eur J Rheumatol*. 2019;6(3):161-2. DOI: 10.5152/eurjrheum.2018.18111.
- Kusyairi KA, Gendeh BS, Sakthiswary R, Shaharir SS, Haizlene AH, Yusof KH. The spectrum of nasal involvement in systemic lupus erythematosus and its association with the disease activity. *Lupus*. 2016;25(5):520-4. DOI: 10.1177/0961203315622279.
- Isomura I, Miyawaki S, Morita A. Pyoderma gangrenosum associated with nasal septal perforation, oropharyngeal ulcers and IgA paraproteinemia. *J Dermatol*. 2005;32(3):193-8. DOI: 10.1111/j.1346-8138.2005.tb00744.x.
- Krskovich MD, Kelly SM, Jackson WD. Nasal septal perforation: a rare extraintestinal manifestation of Crohn's disease. *Ear Nose Throat J*. 2000;79(7):520-3.
- Kinnear WJ. Crohn's disease affecting the nasal mucosa. *J Otolaryngol*. 1985;14(6):399-400.
- Ernst A, Preyer S, Plauth M, Jenss H. Polypoid pansinusitis in an unusual, extraintestinal manifestation of Crohn's disease. *HNO*. 1993;41(3):33-6.
- Pochon N, Dulguerov P, Widgren S. Nasal manifestations of Crohn's disease. *Otolaryngol Head Neck Surg*. 1995;113(6):813-5.
- Burbige EJ, Huang SH, Bayless TM. Clinical manifestations of Crohn's disease in children and adolescents. *Pediatrics*. 1975;55(6):866-71.
- Sari S, Dalgic B, Yilmaz M, Poyraz A. Nasal septal perforation in an adolescent girl with Crohn's disease: a rare extraintestinal manifestation. *Dig Dis Sci*. 2007;52(5):1285-7. DOI: 10.1007/s10620-006-9584-4.

34. Morales-Angulo C, García-Zornoza R, Obeso-Agüera S, Calvo-Alén J, González-Gay MA. Manifestaciones otorrinolaringológicas en pacientes con granulomatosis de Wegener (granulomatosis con poliangiitis) [Ear, nose and throat manifestations of Wegener's granulomatosis (granulomatosis with polyangiitis)]. *Acta Otorrinolaringol Esp*. 2012;63(3):206-11. DOI: 10.1016/j.otorri.2011.12.002.
35. Lai TY, Liu PJ, Chan LP. Primary nasal tuberculosis presenting with septal perforation. *J Formos Med Assoc*. 2007;106(11):953-5. DOI: 10.1016/S0929-6646(08)60066-2.
36. Khan S, Pujani M, Jetley S. Primary nasal tuberculosis: resurgence or coincidence—a report of four cases with review of literature. *J Lab Physicians*. 2017;9(1):26-30. DOI: 10.4103/0974-2727.187921.
37. Choi YC, Park YS, Jeon EJ, Song SH. The disappeared disease: tuberculosis of the nasal septum. *Rhinology*. 2000;38(2):90-2.
38. Hup AK, Haitjema T, de Kuijper G. Primary nasal tuberculosis. *Rhinology*. 2001;39(1):47-8.
39. Jaimes A, Muvdi S, Alvarado Z, Rodríguez G. Perforation of the nasal septum as the first sign of histoplasmosis associated with AIDS and review of published literature. *Mycopathologia*. 2013;176(1-2):145-50. DOI: 10.1007/s11046-013-9662-z.
40. Rejali SD, Simo R, Saeed AM, de Carpentier J. Acquired immune deficiency syndrome (AIDS) presenting as a nasal septal perforation. *Rhinology*. 1999;37(2):93-5.
41. Centers for Disease Control and Prevention (CDC). Primary and secondary syphilis—United States, 2000-2001. *MMWR Morb Mortal Wkly Rep*. 2002;51(43):971-3. Available from: <https://www.cdc.gov/mmwr/preview/mmwrhtml/mm5143a4.htm>.
42. Pletcher SD, Cheung SW. Syphilis and otolaryngology. *Otolaryngol Clin N Am*. 2003;36(4):595-605, vi. DOI: 10.1016/s0030-6665(03)00025-2.
43. Harabuchi Y, Takahara M, Kishibe K, Nagato T, Kumai T. Extranodal natural killer/T-cell lymphoma, nasal type: basic science and clinical progress. *Front Pediatr*. 2019;7:141. DOI: 10.3389/fped.2019.00141.
44. Lanier B, Kai G, Marple B, Wall GM. Pathophysiology and progression of nasal septal perforation. *Ann Allergy Asthma Immunol*. 2007;99(6):473-9; quiz 480-1, 521. DOI: 10.1016/S1081-1206(10)60373-0.
45. Kridel RWH. Considerations in the etiology, treatment, and repair of septal perforations. *Facial Plast Surg Clin North Am*. 2004;12(4):435-50, vi. DOI: 10.1016/j.fsc.2004.04.014.
46. Jaffe ES, Chan JK, Su IJ, Frizzera G, Mori S, Feller AC, et al. Report of the workshop on nasal and related extranodal angiocentric T/natural killer cell lymphomas. Definitions, differential diagnosis, and epidemiology. *Am J Surg Pathol*. 1996;20(1):103-11. DOI: 10.1097/00000478-199601000-00012.
47. Mullace M, Gorini E, Sbrocca M, Artesi L, Mevio N. Management of nasal septal perforation using silicone nasal septal button. *Acta Otorhinolaryngol Ital*. 2006;26(4):216-8.
48. Dosen LK, Haye R. Silicone button in nasal septal perforation. Long term observations. *Rhinology*. 2008;46(4):324-7.
49. Ribeiro JS, da Silva GS. Technical advances in the correction of septal perforation associated with closed rhinoplasty. *Arch Facial Plast Surg*. 2007;9(5):321-7. DOI: 10.1001/archfaci.9.5.321.
50. Wang W, Vincent A, Shokri T, Hilger P, Ducic Y. Septal perforation repair using bilateral rotational flaps with interposed mastoid periosteal graft. *Laryngoscope*. 2021;131(7):1497-1500. DOI:10.1002/lary.29347.
51. Santamaría-Gadea A, Mariño-Sánchez F, Arana-Fernández B, Mullol J, Alobid I. Innovative surgical techniques for nasal septal perforations: management and treatment. *Curr Allergy Asthma Rep*. 2021;21(3):17. DOI: 10.1007/s11882-021-00992-2.
52. Goh AY, Hussain SSM. Different surgical treatments for nasal septal perforation and their outcomes. *J Laryngol Otol*. 2007;121(5):419-26. DOI: 10.1017/S002221510700566X.
53. Ayshford CA, Shykhon M, Uppal HS, Wake M. Endoscopic repair of nasal septal perforation with acellular human dermal allograft and an inferior turbinate flap. *Clin Otolaryngol Allied Sci*. 2003;28(1):29-33. DOI: 10.1046/j.1365-2273.2003.00654.x.

