


## ORIGINAL STUDY

# Stapes surgery for otosclerosis: Comparison of two techniques

Regina Jacobo-Pinelli<sup>1</sup> , José Alberto Guerrero-Paz<sup>1</sup> , Juan Antonio Lugo-Machado<sup>1</sup> , Martha Lucía Gutiérrez Pérez<sup>2</sup> , Noemí Sainz-Fuentes<sup>1</sup> , Irene del Carmen Arellano-Rodríguez<sup>1</sup> , Edwin Miguel Canche-Martín<sup>1</sup> , Jose Roberto Reina-Loaiza<sup>1</sup> , Oscar Said Rodríguez-Quintana<sup>1</sup> , Pedro Alberto Rodríguez-Romero<sup>1</sup> 

<sup>1</sup>Otorhinolaryngology Service of the UMAE, “Lic. Luis Donaldo Colosio Murrieta” Specialties Hospital no. 2, Mexican Institute of Social Security, Ciudad Obregón, Sonora, Mexico

<sup>2</sup>El Bosque University, Colombian School of Medicine, Otorhinolaryngology Interest Group UEB (ORLIG-UEB), Bogotá, Colombia

## ABSTRACT

**BACKGROUND.** Otosclerosis is a primary disease of the human otic capsule and stapes stage, being a frequent cause of conductive hearing loss in our country. The surgical treatment of choice is stapes surgery and prosthesis placement, performed in a conventional way, with a surgical microscope, for 30 years in our hospital. Recently, the option of performing stapes surgery endoscopically was introduced in our centre.

**OBJECTIVE.** To evaluate the results in stapes surgery for otosclerosis between the conventional microscopic versus endoscopic procedure.

**MATERIAL AND METHODS.** An observational, analytical and retrospective study on patients undergoing stapes surgery with microscopic and endoscopic technique was conducted. Data such as age, sex, state of origin, affected ear, as well as the technique used, duration of surgical intervention, hearing gain and postsurgical complications were taken. Data were taken from the records of patients admitted to the hospital. Descriptive statistics, Mann-Whitney U and Pearson’s  $\chi^2$ , were used, considering a value of  $p \leq 0.05$  as significant.

**RESULTS.** No significant differences were found in surgical time or postoperative hearing between the two surgical techniques. The female sex was the most intervened. There was no significant difference between the post-surgical complications of both groups.

**CONCLUSION.** Both procedures appear to be effective, with similar risks and postoperative results for the surgical treatment of otosclerosis.

**KEYWORDS:** otosclerosis, stapes surgery, stapectomy, endoscopy, microscopy, treatment outcome.

## INTRODUCTION

Otosclerosis (localized bone dysplasia) is a primary disease of the ear capsule and stapes stage. This impacts hearing and balance depending on the site affected, size and histological characteristics of the areas involved. The clinical and radiological form of the disease is expressed in the presence of otosclerotic foci that cause conductive hearing loss by interfering with the movement of the stapes or round window membrane. The otosclerotic plates are located mainly anterior to the oval window (fissula ante fenestram) and in the stage of the stapes<sup>1</sup>.

Histological otosclerosis refers to a pathological process without clinical implications, discovered only in routine sec-

tion of the temporal bone. There are three forms: otospongiosis (early phase), a transitional phase and otosclerosis (final phase)<sup>2</sup>.

This disease is more common in the Caucasian population, affecting approximately 1% of the population<sup>1,2</sup>. In up to 50-60% of cases there is a pattern of family inheritance<sup>3</sup>.

The clinical presentation is directly associated with the location and extent of the sclera lesion. An injury originating in the fissula ante fenestram and advancing through the annular ligament of the stapes stage will result in platen fixation and consequently conductive hearing loss. Less commonly, the lesion progresses medially to the endosteum of the cochlea and results in sensorineural hearing loss. The classic

**Corresponding author:** Dr. Juan Antonio Lugo-Machado, Otorhinolaryngology Service of the UMAE, “Lic. Luis Donaldo Colosio Murrieta” Specialties Hospital no. 2, Mexican Institute of Social Security, Prolongación Hidalgo Bellavista, Cajeme 85130, Ciudad Obregón, Sonora, Mexico

**ORCID:** <https://orcid.org/0000-0003-4864-8546>

**e-mail:** otorrinox@gmail.com

**Received for publication:** January 8, 2023 / **Accepted:** February 13, 2023

presentation is the onset in adulthood, as progressive conductive hearing loss<sup>4</sup>.

Traditionally, the diagnosis of otosclerosis is clinically suspected and supported by audiological findings. The diagnostic value of routine imaging studies is usually a matter of debate. However, imaging is very well established for some patients with suspected otosclerosis, to exclude other causes of conductive hearing loss.

The therapeutic approach of patients with otosclerosis is aimed at limiting the clinical-symptomatic progression of the disease<sup>5</sup>. There is no curative medical therapy<sup>6</sup>. The literature suggests that sodium fluoride, possibly in combination with calcium carbonate, may reduce the rate of conductive and sensorineural hearing impairment in patients with otosclerosis<sup>7</sup>. The discovery that bisphosphonates could inhibit bone resorption was made in 1960. To date, several promising studies have been published for the use of bisphosphonates in the context of otosclerosis. However, there is insufficient evidence to evaluate their preventive use<sup>8</sup>.

Since the introduction of the classical microscopic technique, described by John Shea in 1956 by removing the stapes and using a Teflon prosthesis instead, multiple techniques have been described in the literature from the microscopic point of view. Currently, microscopic ear surgery has satisfactory results. However, there are some limitations, such as visualization of the tympanic membrane and some structures of the middle ear, especially for patients who have narrowing in the external ear canal<sup>9</sup>.

In 1967, Mer et al. first described the use of the endoscope to visualize structures of the middle ear<sup>10</sup>. The past two decades have seen a substantial increase in the use of endoscopic transcanal ear surgery. It is currently used to perform stapedectomies, as well as other otologic procedures such as tympanoplasty, cholesteatoma surgery, ossiculoplasty and the removal of the middle ear and intracanalicular pathology<sup>10</sup>.

One of the greatest advantages of using the endoscope is that it allows optimized visibility of the middle ear structures compared to those of the microscope. Specifically, in stapes surgery, the wide-angle view allows for better visibility of the stapes, plate, as well as anatomical identification and pathological variants, plus a closer view and confirmation of the prosthesis coupling<sup>11</sup>.

## MATERIAL AND METHODS

An observational, analytical, cross-sectional, retrospective, non-probabilistic selection study was carried out on consecutive series of cases from March 2020 to July 2022. The study included patients undergoing stapes surgery for otosclerosis with the two types of microscopic and endoscopic surgical approach and with two techniques of release of the stage of the stapedectomy stapes and stapedotomy. There was no distinction between the endoscopic or microscopic approach. In all patients, the same Schuknecht wire and Teflon prosthesis was placed. The procedures were performed by 3 or more

experienced ENT surgeons, under general anaesthesia and orotracheal intubation.

The clinical records of the patients included in the study were reviewed, noting demographic variables, as well as the data obtained from the surgical sheets to be compared (duration, type of technique used), in addition to investigating data on the postoperative evolution in the short and medium term to obtain data such as postsurgical complications (nausea, vomiting, facial paralysis) and hearing gain. A 3-month follow-up audiological study was performed in all cases.

### Data analysis

Once the variables were captured through an Excel spreadsheet of Microsoft Office 2019 for Windows, descriptive statistics were used with measures of central trends and dispersion. For inferential analysis the Mann-Whitney U will be used for numerical variables and Pearson's J<sub>2</sub> or Fisher's exact test for categorical variables, considering a value of  $p \leq 0.05$  as significant. The statistical analysis was performed using the IBM SPSS version 26 package for Windows.

## RESULTS

In the period between March 2020 to July 2022, 38 procedures were performed, 8 were eliminated due to loss to follow-up, leaving 30 stapes surgeries for otosclerosis for analysis, with the two different approaches: conventional, with a surgical microscope, and endoscopic. These patients were divided into 2 groups: 15 patients were operated on microscopically and 15 patients endoscopically. In our study, the majority of operated patients were female (76.7%) over male (23.3%), a fact that correlates with most national and international research studies<sup>1,2,4,12</sup> (see Table 1). The mean age of the participants was 43.10, SD  $\pm$  11.4 years, with a maximum age of 65 and a minimum of 16.

The ear operated on most frequently in our study was the right ear (56%) (Table 1). The most used technique for prosthetic placement was stapedotomy (63.3%) over classic stapedectomy (36.7%), depending on the technique preferred by each surgeon and the case of each patient (see Table 1).

The vast majority of patients (86%) reported hearing gain subjectively to direct questioning during their immediate postoperative period.

The PTA (Pure Tone Audiogram Average) on pure-tone audiometry, presurgical, of both groups was 58.7, translating this to moderate hearing loss. In our study, it was observed that the postoperative PTA decreased on average to 46.0, obtaining a favourable result on average for the auditory thresholds in the operated patients. We found no significant differences between both groups in terms of the reduction of bone gap-air with respect to the type of surgery (endoscopic vs. microscopic) with a value of  $p = 0.486$  ( $p \leq 0.05$ ) (Table 1).

The surgical time was shorter in microscopic surgery, lasting an average of 101 minutes, compared to 129 minutes during the endoscopic intervention. However, no significant differences were found ( $p = 0.106$ ) (Table 2). Half of the pa-

**Table 1. Descriptive variables considered in patients undergoing stapes surgery.**

Variables		n	%
Gender	Female	23	76.7
	Male	7	23.3
Age	Average	43.1	
	Rank	16-65	
Operated ear	Right	17	56.6
	Left	13	43.4
Technique	Stapedectomy	11	36.7
	Stapedotomy	19	63.3

Source: Otorhinolaryngology Service of the Luis Donaldo Colosio Murrieta Specialty Hospital No. 2 from March 2020 to July 2022.

tients in both groups did not present complications (50%), being slightly more frequent in the microscopic group (60%). However, no significant differences were found with a value of  $p = 0.608$  ( $p \leq 0.05$ ). Several complications were identified such as vertigo (8 cases, in 26%) being the most frequent, as well as tinnitus (2 patients, 6.7%), dysgeusia, perforation of the tympanic membrane, in one patient there was disruption of the ossicular chain and in one case, in turn, anacusis. A patient in the microscopic group presented facial paralysis (House Brackmann II) 10 days after his intervention, remitting completely within a month (Figure 1) and (Table 3).

## DISCUSSIONS

In relation to sex, it was found a predominance of females, similar to what is widely described in the international literature<sup>12</sup>. In several studies consulted in our literature review, a decrease in ABG (GAP or air-bone space) to less than 10dB (decibels) is considered successful in stapes surgery<sup>12-14</sup>. In our evaluation, we observed that of the patients who did con-

tinue with their postoperative follow-up with the Audiology service, approximately half of each group achieved this goal by having as a postoperative result an ABG less than 10dB. In the endoscopic surgery group, there were also cases in whom there was a result of an ABG between 10 and 20dB, this being considered a favourable result. However, in the same group, there were two patients with decreased hearing threshold – one of them presented a disruption of the ossicular chain after surgery, with a postsurgical tonal audiometry with anacusis; the other reported immediate gain, but at 4 weeks after the surgery presented a sudden decrease in the hearing threshold accompanied by tinnitus. When performing tonal audiometry, a severe sensorineural hearing loss was found.

In the group of stapes surgeries performed under a microscope, half of the patients who did continue with their postoperative audiological control adequately did not present hearing gain and/or decrease in ABG.

In a study similar to ours, conducted by Kojima in Japan, with a similar number of participants, in order to investigate whether endoscopic stapes surgery was safer and less invasive than the conventional technique, similar results were obtained, finding no significant differences in surgical time,

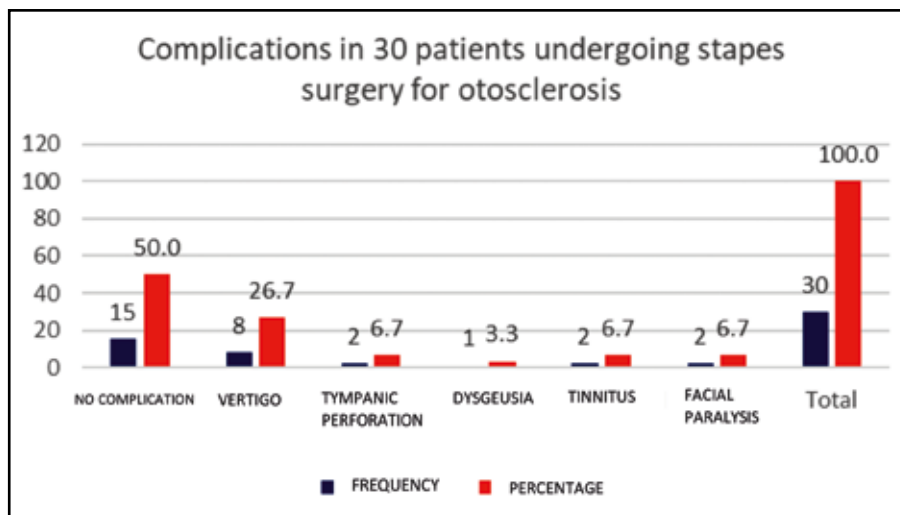
**Table 2. Comparison of post-surgical hearing gain and duration of endoscopic vs microscopic stapes surgery.**

	Endoscopic	Microscopic	(p)
Pre-surgical PTA	53.4	64.25	0.202
Post-surgical PTA	44.4	47.7	0.486
Duration (min)	129	101	0.106

PTA: Pure Tone Audiogram Average

(p) = p-value calculated with Mann-Whitney U test.

Source: Otorhinolaryngology Service of the Specialty Hospital No. 2 Luis Donaldo Colosio Murrieta from March 2020 to June 2022



**Figure 1.** Complications in patients undergoing stapes surgery (Source: Otorhinolaryngology Service of the Luis Donaldo Colosio Murrieta Specialty Hospital No. 2 from March 2020 to July 2022).

hearing gain or complications in both groups<sup>14</sup>. However, a systematic review and meta-analysis (Fang) conducted in 2020, including twelve studies and a total of 620 patients, demonstrated a consistently superior effect in the stapes endoscopic surgery group in total terms of effectiveness when compared to the microscopic surgery group<sup>15</sup>.

We observed that the duration of surgery is shorter in microscopic surgery. However, this is also related to the time used to clean the lens or haemostasis in surgery that is performed with one hand, as is the case of endoscopic surgeries<sup>15</sup>. It is clear that exposure and visibility are superior with the use of the endoscope since the lenses pass through the narrowest portion of the ear canal and provide a wide view that allows the surgeon to look “around the corners” either with angled endoscopes or even with those of 0°. In contrast, the microscope through the ear canal provides a limited surgical field, defined by the narrowest segment of the duct. By using the endoscope for stapes surgery for otosclerosis, greater precision is obtained when placing the prosthesis, less need to resect bone from the posterior wall of the duct, less manipulation of the eardrum cord, possibly trans-

lating to a lower rate of complications and need for revision surgery after surgery<sup>16</sup>.

Numerous studies have been conducted to evaluate the results of these procedures. Overall, patients undergoing stapedotomy had slightly, but significantly better results compared to patients who underwent stapedectomy, taking as a successful case an ABG less than 10dB<sup>17</sup>. The rate of complications presented was lower in stapedotomies than in stapedectomies in studies such as Cheng’s<sup>17</sup>. However, in our study, there was no correlation in hearing gain or complications presented after performing either technique.

Among the limitations would be: the retrospective type of the study, the sample size which could in the future be performed with more patients to achieve a greater recruitment of cases between the surgical techniques performed (stapedotomy vs. stapedectomy), the type of approach (microscopic vs. endoscopic) and duration, hearing gain and postsurgical complications. We propose to continue with the recruitment of a greater number of patients in order to increase the samples and our results could be more reliable for their generalization.

**Table 3. Complications by surgical approach in stapes surgery.**

Surgical approach	Without complications	Vertigo	Facial paralysis	Tympanic membrane perforation	Tinnitus	Dysgeusia
Microscopic	9	2	1	1	1	1
Endoscopic	6	6	1	1	1	0

Source: Otolaryngology Service of the Specialty Hospital No. 2 Luis Donaldo Colosio Murrieta from March 2020 to July 2022

## CONCLUSIONS

Stapes surgery for otosclerosis can be performed endoscopically or microscopically in a safe way, since with the use of either of the two approaches similar results will be obtained, mostly favourable for hearing, both being carried out in an average of similar surgical time, with a complication rate at the same time.

In our hospital, endoscopic ear surgery has recently begun to be performed, so it is suggested to carry out studies in the coming years to evaluate these variables with a better learning curve and greater experience of both assigned doctors and residents in training with the use of these equipment, in addition to having a larger sample with better audiological postsurgical follow-up.

**Study limitations:** It is a retrospective study that may present biases of the registration of data in the files, very small groups, without probabilistic methods, which avoid the generalization of our results.

**Funding sources:** This article has been funded by the authors.

**Conflicts of interest:** The authors declare that they have no conflict of interest.

**Contribution of authors:** All authors equally contributed to this work.

**Ethical aspects:** This research work presented a protocol that was evaluated and authorized by the research ethics committee (CLEIS) and health research committee (CLIS) of our hospital, registration number: 2022-2602-075.

**Acknowledgements:** We thank the Mexican Institute of Social Security, as the contributing institution of the cases, as well as thank our authorities of this hospital for the facilities to carry out this investigation.

### Authors' information:

Regina Jacobo-Pinelli, Resident Doctor, Otorhinolaryngology Service of the UMAE, "Lic. Luis Donaldo Colosio Murrieta" Specialties Hospital no. 2, Mexican Institute of Social Security, Ciudad Obregón, Sonora, Mexico. E-mail: reginapinelli.otorrino@gmail.com. ORCID: <https://orcid.org/0000-0002-2116-8043>.

José Alberto Guerrero-Paz, MD, Otorhinolaryngology Service of the UMAE, "Lic. Luis Donaldo Colosio Murrieta" Specialties Hospital no. 2, Mexican Institute of Social Security, Ciudad Obregón, Sonora, Mexico. E-mail: albertsevenfold@gmail.com. ORCID: <https://orcid.org/0000-0002-9755-0951>.

Juan Antonio Lugo-Machado, MD, Otorhinolaryngology Service of the UMAE, "Lic. Luis Donaldo Colosio Murrieta" Specialties Hospital no. 2, Mexican Institute of Social Security, Ciudad Obregón, Sonora, Mexico. E-mail: otorrinox@gmail.com. ORCID: <https://orcid.org/0000-0003-4864-8546>.

Martha Lucía Gutiérrez Pérez, Medical Doctor, El Bosque University, Colombian School of Medicine, Otorhinolaryngology

Interest Group UEB (ORLIG-UEB), Bogotá, Colombia. E-mail: martha.gutierrez24@hotmail.com. ORCID: <https://orcid.org/0000-0002-5577-7082>.

Noemi Sainz-Fuentes, MD, Otorhinolaryngology Service of the UMAE, "Lic. Luis Donaldo Colosio Murrieta" Specialties Hospital no. 2, Mexican Institute of Social Security, Ciudad Obregón, Sonora, Mexico. E-mail: mimisf@hotmail.com. ORCID: <https://orcid.org/0000-0001-9672-8896>.

Irene del Carmen Arellano-Rodríguez, MD, Otorhinolaryngology Service of the UMAE, "Lic. Luis Donaldo Colosio Murrieta" Specialties Hospital no. 2, Mexican Institute of Social Security, Ciudad Obregón, Sonora, Mexico. E-mail: irene\_kawai@hotmail.com. ORCID: <https://orcid.org/0000-0001-9610-3810>.

Edwin Miguel Canche-Martín, MD, Otorhinolaryngology Service of the UMAE, "Lic. Luis Donaldo Colosio Murrieta" Specialties Hospital no. 2, Mexican Institute of Social Security, Ciudad Obregón, Sonora, Mexico. E-mail: edwincanche@hotmail.com. ORCID: <https://orcid.org/0000-0001-8718-7653>.

José Roberto Reina-Loaiza, MD, Otorhinolaryngology Service of the UMAE, "Lic. Luis Donaldo Colosio Murrieta" Specialties Hospital no. 2, Mexican Institute of Social Security, Ciudad Obregón, Sonora, Mexico. E-mail: jrobertorl@hotmail.com. ORCID: <https://orcid.org/0000-0002-8615-4072>.

Oscar Said Rodriguez-Quintana, MD, Otorhinolaryngology Service of the UMAE, "Lic. Luis Donaldo Colosio Murrieta" Specialties Hospital no. 2, Mexican Institute of Social Security, Ciudad Obregón, Sonora, Mexico. E-mail: saidorus@gmail.com. ORCID: <https://orcid.org/0000-0003-3618-9127>.

Pedro Alberto Rodríguez-Romero, MD, Otorhinolaryngology Service of the UMAE, "Lic. Luis Donaldo Colosio Murrieta" Specialties Hospital no. 2, Mexican Institute of Social Security, Ciudad Obregón, Sonora, Mexico. E-mail: pedrorodriguezromero@gmail.com. ORCID: <https://orcid.org/0000-0002-9153-7123>.

## REFERENCES

- Rudic M, Keogh I, Wagner R, Wilkinson E, Kiros N, Ferrary E, et al. The pathophysiology of otosclerosis: Review of current research. *Hear Res.* 2015;330(Pt A):51-6. DOI: [10.1016/j.heares.2015.07.014](https://doi.org/10.1016/j.heares.2015.07.014).
- Foster MF, Backous DD. Clinical evaluation of the patient with otosclerosis. *Otolaryngol Clin North Am.* 2018;51(2):319-26. DOI: [10.1016/j.otc.2017.11.004](https://doi.org/10.1016/j.otc.2017.11.004).
- Ziff JL, Crompton M, Powell HRF, Lavy JA, Aldren CP, Steel KP, et al. Mutations and altered expression of SERPINF1 in patients with familial otosclerosis. *Hum Mol Genet.* 2016;25(12):2393-403. DOI: [10.1093/hmg/ddw106](https://doi.org/10.1093/hmg/ddw106).
- Danesh AA, Shahnaz N, Hall JW. The audiology of otosclerosis. *Otolaryngol Clin North Am.* 2018;51(2):327-42. DOI: [10.1016/j.otc.2017.11.007](https://doi.org/10.1016/j.otc.2017.11.007).
- Mangia LRL, de Mattos Coelho LO, Carvalho B, de Oliveira AKP, Hamerschmidt R. Imaging studies in otosclerosis: An up-to-date comprehensive review. *Int Arch Otorhinolaryngol.* 2021;25(2):e318-27. DOI: [10.1016/j.iaot.2021.03.001](https://doi.org/10.1016/j.iaot.2021.03.001).

- 10.1055/s-0040-1715149.
6. de Oliveira Penido N, de Oliveira Vicente A. Medical management of otosclerosis. *Otolaryngol Clin North Am.* 2018;51(2):441-52. DOI: 10.1016/j.otc.2017.11.006.
  7. Cruise AS, Singh A, Quiney RE. Sodium fluoride in otosclerosis treatment: review. *J Laryngol Otol.* 2010;124(6):583-6. DOI: 10.1017/S0022215110000241.
  8. Zimmerer RE, Africa RE, Westenhaver ZK, McKinnon BJ. Bisphosphonate therapy in otosclerosis: A scoping review. *Laryngoscope Investig Otolaryngol.* 2022;7(1):242-9. DOI: 10.1002/lio2.729.
  9. Nazarian R, McElveen JT, Eshraghi AA. History of otosclerosis and stapes surgery. *Otolaryngol Clin North Am.* 2018;51(2):275-90. DOI: 10.1016/j.otc.2017.11.003.
  10. Isaacson B, Hunter JB, Rivas A. Endoscopic stapes surgery. *Otolaryngol Clin North Am.* 2018;51(2):415-28. DOI: 10.1016/j.otc.2017.11.011.
  11. Bennett ML, Zhang D, Labadie RF, Noble JH. Comparison of middle ear visualization with endoscopy and microscopy. *Otol Neurotol.* 2016;37(4):362-6. DOI: 10.1097/MAO.0000000000000988.
  12. Crompton M, Cadge BA, Ziff JL, Mowat AJ, Nash R, Lavy JA, et al. The epidemiology of otosclerosis in a British cohort. *Otol Neurotol.* 2019;40(1):22-30. DOI: 10.1097/MAO.0000000000002047.
  13. Rajput MSA, Arain AA, Rajput A, Adeel M, Suahil A, Awan MS. Otosclerosis: experience with stapes surgery. *Cureus.* 2020;12(5):e7927. DOI: 10.7759/cureus.7927.
  14. Kojima H, Komori M, Chikazawa S, Yaguchi Y, Yamamoto K, Chujo K, et al. Comparison between endoscopic and microscopic stapes surgery. *Laryngoscope.* 2014;124(1):266-71. DOI: 10.1002/lary.24144.
  15. Fang L, Xu J, Wang W, Huang Y. Would endoscopic surgery be the gold standard for stapes surgery in the future? A systematic review and meta-analysis. *Eur Arch Otorhinolaryngol.* 2021;278(4):925-32. DOI: 10.1007/s00405-020-06132-3.
  16. Kapadiya M, Tarabichi M. An overview of endoscopic ear surgery in 2018. *Laryngoscope Investig Otolaryngol.* 2019;4(3):365-73. DOI: 10.1002/lio2.276.
  17. Cheng HCS, Agrawal SK, Parnes LS. Stapedectomy versus stapedotomy. *Otolaryngol Clin North Am.* 2017;51(2):375-92. DOI: 10.1016/j.otc.2017.11.008.

© 2023 Regina Jacobo-Pinelli, José Alberto Guerrero-Paz, Juan Antonio Lugo-Machado, Martha Lucía Gutiérrez Pérez, Noemí Sainz-Fuentes, Irene del Carmen Arellano-Rodríguez, Edwin Miguel Canche-Martín, Jose Roberto Reina-Loaiza, Oscar Said Rodríguez-Quintana, Pedro Alberto Rodríguez-Romero, published by Romanian Rhinologic Society



This is an open access article published under the terms and conditions of the Creative Commons Attribution-NonCommercial-NoDerivatives 4.0 International (CC BY-NC-ND 4.0) License (<https://creativecommons.org/licenses/by-nc-nd/4.0/>). CC BY-NC-ND 4.0 license requires that reusers give credit to the creator by citing or quoting the original work. It allows reusers to copy, share, read, download, print, redistribute the material in any medium or format, or to link to the full texts of the articles, for non-commercial purposes only. If others remix, adapt, or build upon the material, they may not distribute the modified material.