

LITERATURE REVIEW

Olfactory neuroblastoma: Up-to-date review and our experience

Bianca Rusu¹, Daniel Lupoi^{1,2} , Mihai Dragomir¹, Carmen Badea^{1,2} 

¹ENT&HNS Department, “Sfanta Maria” Hospital, Bucharest, Romania

²“Carol Davila” University of Medicine and Pharmacy, Bucharest, Romania

ABSTRACT

Olfactory neuroblastoma (ONB), also known as esthesioneuroblastoma, is a rare malignant neuroectodermal tumor originating primarily from the basal layer of the olfactory epithelium in the roof of the nasal cavity. The most common symptoms are nasal obstruction, anosmia, recurrent epistaxis, rhinorrhea and excessive lacrimation. Imaging studies are helpful for assessing the extent of olfactory neuroblastoma, as well as grading the tumor. The definitive diagnosis is based on histopathological exam and immunohistochemistry profile and it might be quite challenging because the tumor can mimic other sinonasal malignancies. Because of the small number of reported cases and the lack of prospective research, the optimal treatment for olfactory neuroblastoma is still controversial. However, it is generally believed that surgical resection followed by radiotherapy gives the best outcome in terms of recurrence and survival rates. Keeping in mind the rarity of olfactory neuroblastoma and the diagnostic difficulty, the aim of this study is to improve the understanding of the clinical features by reviewing the literature focusing on the recent advances in the diagnosis and treatment of ONB. Moreover, we are reporting an atypical case of an aggressive type of olfactory neuroblastoma treated through a multimodal approach, with no signs of tumor recurrence after a 3-month follow-up.

KEYWORDS: olfactory neuroblastoma, esthesioneuroblastoma, surgery, radiotherapy, chemotherapy.

INTRODUCTION

Olfactory neuroblastoma (ONB), also referred to as esthesioneuroblastoma, is a rare malignant tumor of the nasal cavity, representing about 6.3% of all malignancies of the sinonasal tract, with a prevalence of 0.4 cases per million population¹. It is considered a neuroectodermal tumor originating from the basal stem cells of the olfactory neuroepithelium located on superior nasal structures, cribriform plate and anterior skull base. It has a bimodal distribution and generally tends to occur in the second and sixth decade of life, with no gender or race predilection². The etiology is not clearly defined, but there are several risk factors associated, such as smoking, exposure to hazardous chemicals and particles, wood dust, wheat, nickel, cadmium dust, glues, formaldehyde and other solvating agents. The most common symptoms

are nasal obstruction, anosmia, recurrent epistaxis, rhinorrhea and excessive lacrimation. Because of the non-specific presentation, most patients present with locally advanced tumors.

Due to the small number of reported cases, no consensus has been reached regarding the optimal treatment of olfactory neuroblastoma, although diagnostic and treatment modalities have improved over the past two decades. However, most authors consider that surgical excision via craniofacial approach (CFA) combined with postoperative radiotherapy is the standard of care and provides the best outcome in terms of survival and recurrence³.

A thorough search of the relevant literature reveals that many features of this entity are still unclear because of the low incidence, underlying the necessity for well-designed diagnostic and treatment algorithms.

Corresponding author: Daniel Lupoi, MD, Lecturer, ENT&HNS Department, “Sfanta Maria” Clinical Hospital, 37-39 Ion Mihalache Blvd., District 1, Bucharest, Romania

ORCID: <https://orcid.org/0000-0003-2248-6702>

e-mail: daniel.lupoi@umfcd.ro

Received for publication: February 8, 2023 / **Accepted:** March 27, 2023

The diagnosis of olfactory neuroblastoma is extremely challenging and usually is made on the basis of information derived from the history, clinical examination, imaging studies and confirmed by histopathological exam and immunohistochemistry profile.

CLINICAL AND PARACLINICAL FEATURES

Among the presenting symptoms, unilateral nasal obstruction and recurrent epistaxis are the most frequent. Other symptoms may include rhinorrhea, hyposmia/anosmia, headache, excessive lacrimation, facial pain, or numbness. In cases with intraorbital extension, the patients may present with decreased visual acuity, proptosis, periorbital edema, or diplopia⁴. Because most clinical manifestations are nonspecific, olfactory neuroblastoma is often missed during its early stages and not diagnosed until it has reached an advanced stage.

Clinical examination and nasal endoscopy reveal a soft tissue mass in the superior olfactory recess. The tumor may not have a specific appearance but, usually, presents as a unilateral soft reddish gray polypoid mass, with an intact mucosa medial to the middle turbinate. Considering the pathway of the olfactory nerve, esthesioneuroblastoma can remain localized in the nasal cavity for a long time or can spread to adjacent structures such as the sinuses, the cribriform plate, the anterior skull base, the orbit or it can extend to the contralateral nasal cavity. The most frequent place for metastases is the cervical lymph nodes (10–33% of patients), while other more uncommon sites for the extension of the malignancy are the lungs, the brain and bones⁴.

Imaging studies are of the utmost importance in establishing tumor extension and surgical planning of olfactory neuroblastoma. CT and MRI scans represent the first choice in assessing ONB. The contrast-enhanced computer tomography (CECT) of the head and neck is the best investigation for evaluating the local extension of the tumoral mass⁵. One of the most typical findings is a “dumbbell-shaped” mass that crosses the cribriform plate. The observation depends on how big the tumor is and how long the symptoms have been present. With the “waist” at the cribriform plate, the upper section is a mass in the cerebral fossa, while the bottom portion is located in the nasal cavity. The lamina papyracea, the cribriform plate, and/or fovea ethmoidalis will all be seen on a CT scan as scattered calcifications and bone destruction. With a CECT scan, a homogeneously enhancing bulk will be visible, while non-enhancing patches will suggest necrotic areas⁶. MRI is the appropriate choice for evaluating intraorbital and intracranial extension⁵. T1-weighted pictures show a hypointense to intermediate signal intensity within the mass compared to the brain, while hyperintense areas that correspond to the cystic regions at the advancing edge may be visible on T2-

weighted imaging. After gadolinium, tumors frequently exhibit a noticeable enhancement⁶.

Histopathological exam and immunohistochemistry profile, however, lead to a definitive diagnosis. The typical histologic appearance includes a lobular architecture characterized by small, round blue cells with a high nuclear-to-cytoplasmic ratio separated into nests by fibrovascular septa. The tumor cells have small round nuclei, with a salt and paper nuclear chromatin distribution, mimicking other small, round cell tumors. Therefore, it is challenging to distinguish between the undifferentiated ONB and other small-cell sinonasal neoplasms such as small-cell carcinoma, lymphoma, rhabdomyosarcoma, undifferentiated carcinoma, sinonasal neuroendocrine carcinoma, Ewing's sarcoma. Immunohistochemistry shows intense positive staining for neuroendocrine markers, such as synaptophysin, neuron-specific enolase, chromogranin, CD57, CD56 and calretinin, in addition to a negative staining for p63, ruling out the majority of these differential diagnoses⁷.

STAGING SYSTEMS

Over time, many staging classifications were described, essential in selecting the most appropriate treatment and determining the prognosis. Kadish et al.⁸ proposed the first classification of olfactory neuroblastoma based on computer tomography and magnetic resonance imaging. This system divides tumors into three groups: group A – tumors are limited to the nasal cavity; group B – tumors involve the nasal cavity and paranasal sinuses; group C – tumors extend beyond the nasal cavity and paranasal sinuses.

Miorita et al.⁹ brought a modification to the system with the addition of a group D for patients with regional (neck lymph nodes) or distant metastases (Table 1). Later, Dulguerov et al.¹⁰ proposed a new classification closer to the TNM classification used to better assess regional and distant extension (Table 2). Dulguerov classification takes into consideration three factors: the

Table 1. Modified Kadish staging system for olfactory neuroblastoma⁹.

Stage	Tumor boundaries
A	Nasal cavity
B	Nasal cavity and one or more paranasal sinuses
C	Invasion of the cribriform plate, skull base, orbit and/or the intracranial cavity
D	Cervical or distant metastasis

Table 2. Staging system for olfactory neuroblastoma according to Dulguerov¹⁰.

Stage	Tumor boundaries		
T1	Tumor involving the nasal cavity and/or paranasal sinuses (apart from sphenoid), sparing the most superior ethmoidal cells		
T2	Tumor involving the nasal cavity and/or paranasal sinuses (including the sphenoid) with extension to or erosion of the cribriform plate		
T2	Tumor extending into the orbit or protruding into the anterior cranial fossa		
T4	Tumor involving the brain		
	Lymph nodes	Distant metastasis	
N0	No cervical lymph node metastasis	M0	No metastasis
N1	Any form of cervical lymph node metastasis	M1	Distant metastasis present

Table 3. Hyams histologic grading system for olfactory neuroblastoma⁶.

Grade	Cytoarchitecture	Mitotic rate	Nuclear pleomorphism	Rosettes	Necrosis
Grade I	Lobular	0	Absent	±	Absent
Grade II	Lobular	Low	Slight	±	Absent
Grade III	±	Moderate	Moderate	True rosettes	Mild
Grade IV	±	High	Marked	None	Extreme

± - may be present or absent

primary tumor, the lymph nodes and the presence of distant metastasis. An important aspect is that both the Kadish modified staging system and the Dulguerov staging system consider the implication of the regional neck lymph nodes and distant metastasis, as they are a significant prognostic factor associated with poorer outcomes¹¹.

In 1988, Hyams et al.⁶ proposed a histological grading system based on microscopic findings, which demonstrates a high correlation of survival with histological differentiation of the disease (Table 3). Apart from the staging systems, the grading system gives an important insight related to the prognosis. Based on the microscopic aspects of the cellular architecture, pleomorphism, mitotic activity and presence of necrosis, gland hyperplasia, calcification and neurofibrillary matrix or rosettes, Hyams classifies ONB into another four classes¹². It is a model that includes the full range of ONB maturation, from undifferentiated, indolent disease to differentiated, more aggressive form of the disease. According to Hyams's histologic grading system, there is a plain distinctive pattern between the well-differentiated ONB and undifferentiated ONB on traditional pathological sections. In the first case, there can be seen homogenous

small cells with round nuclei, with rosette or pseudorosette development and eosinophilic fibrillary intercellular background material, while in the second situation, the cells are small, anaplastic, hyperchromic, a high nucleus/cytoplasm ratio, a high mitotic rate, extensive necrosis and no rosettes¹³.

TREATMENT OUTCOME AND SURVIVAL

Because of the small number of reported cases and the lack of prospective research, the optimal treatment for olfactory neuroblastoma is still controversial. Olfactory neuroblastomas can be treated surgically, with radiation therapy, or with chemotherapy. Depending on the size of the tumor and the feasibility of surgical excision, these may be performed alone or in combination.

Currently, it is generally believed that the mainstay of treatment is surgical resection combined with postoperative radiotherapy. In patients with early-stage tumors limited to the sinonasal cavity (Kadish A stage), surgery alone via open or endoscopic approach with adequate negative margin appears to be sufficient, with a high de-

gree of oncological control. Routine neck dissection is not indicated in these cases due to the low incidence of neck node metastasis in the early stages. However, in patients with advanced-stage tumors, a multimodal strategy is preferred. The rate of neck metastases increases up to 44%, therefore, neck dissection or irradiation is recommended¹⁴.

Olfactory neuroblastoma has a high rate of regional recurrence, and it seems that the risk increases with longer follow-up time. According to Dulguerov's meta-analysis published in 2001, the rates of local, regional and distant metastases were 29%, 16%, and 17%, respectively¹⁵.

Traditionally, olfactory neuroblastoma is treated surgically with an anterior craniofacial resection that requires a bi-frontal craniotomy in combination with a transfacial approach (lateral rhinotomy or midfacial degloving). However, in the last 20 years, endoscopic resection has become the preferred approach for olfactory neuroblastoma. The endoscopic approach provides many advantages, including better cosmetic results and avoidance of maxillofacial bone dissection and translocation. The main limitations of endoscopic approaches include skin and subcutaneous tissue involvement, anterior table of the frontal sinus, deep orbital invasion, lateral supra-orbital extension, carotid artery and brain parenchymal invasion¹⁶. Gallia et al.¹⁷ reported 11 patients with olfactory neuroblastoma who underwent endoscopic resection, 63.7% being classified as Kadish C or D stage. In all cases, negative margins were achieved and all patients were disease-free at the time of report (median follow-up time of 28 months).

It has been demonstrated that a combination of surgery followed by postoperative radiotherapy (PORT) provides a better recurrence-free rate (60% - 100%) compared with surgery alone (14% - 56%)¹⁸. Radiotherapy can be used as adjuvant therapy following surgical resection, as a definitive treatment in inoperable lesions, or for palliation in metastatic disease. In a combined modality of treatment, the preoperative and postoperative doses are 45 Gy and 50-60 Gy, respectively, depending on the status of the surgical margins. In patients with inoperable tumors, 65-70 Gy doses are required. The usual fraction dose is 1.8 to 2.0 Gy. A high dose (more than 2 Gy) raises the risk of late sequelae, such as blindness and bone or brain necrosis¹⁹.

Intensity-modulated radiotherapy (IMRT) is an advanced alternative to conventional techniques that use computer-controlled linear accelerators to deliver precise radiation to the tumor, while minimizing the dose to surrounding normal tissues without compromising tumor control. Compared to traditional techniques, IMRT has less adverse reactions and better survival rates¹⁹. Because of the proximity with the optic nerves and the brainstem, insufficient dose delivery is the main reason for treatment failure.

Osteoradionecrosis is a rare but serious complication

of radiotherapy leading to destruction of vasculature, hypoxia and tissue necrosis. Possible risk factors include surgical trauma (either pre or post-radiation treatment), radiation dose and patient-related factors such as type II diabetes mellitus, smoking, hypertension, atherosclerotic disease or peripheral vascular disease. Usually, the physical exam reveals a non-healing wound with exposed bone and surrounding necrotic tissue or purulent debris. The bone and surrounding tissue can be tender, painful and edematous. Advanced osteoradionecrosis can cause further complications, such as pathologic fractures and discharging fistulas, leading to decreased levels of social and emotional functioning. Treatment options can vary depending on the severity and typically include pentoxifylline and vitamin E, surgical debridement and hyperbaric oxygen therapy²⁰.

SEER (Surveillance, Epidemiology and End Results) database from 2004 to 2016 on 513 patients, which evaluated the survival impact of postoperative radiotherapy, revealed that postoperative radiotherapy improves survival outcomes in patients with modified Kadish C and D but may not affect survival for stages A and B¹.

Nodal neck metastases can occur at a rate of up to 30%. Level II is the most commonly affected. The benefit of adding elective neck irradiation (ENI) for N0 neck patients is still unclear. Many authors suggest that elective neck irradiation might improve the outcome by reducing the regional recurrence rate²¹. Monroe et al.²² reported no regional recurrence in patients who received elective neck irradiation compared to those who did not (27%, $p=0.02$).

Because of the few available studies in the literature, the role of chemotherapy is not clearly defined. Su et al.²³ reported a 68% response rate to induction chemotherapy in 15 patients treated with neoadjuvant chemotherapy. Another large multi-institutional retrospective cohort from France reported a response rate to induction chemotherapy of 74% among 14 patients with locally advanced esthesioneuroblastoma⁵. Therefore, chemotherapy may be indicated in patients with advanced-stage disease, a high Hyams grade, extensive regional disease or distant disease metastases, positive margins, unresectable tumors, and recurrent tumors. Different chemotherapy drugs can be used in treating olfactory neuroblastoma, Cisplatin combined with Etoposide being the most popular regimen preferred by the majority of institutions²².

In a systematic review of the literature, De Bonnecaze et al.²⁴ observed that the combination of surgery and postoperative radiotherapy (PORT) had a better 5-year survival rate (72.9%) than surgery combined with chemoradiotherapy (CRT) (63.9%) and surgery alone (57.6%). Likewise, Dulguerov et al.¹⁵ (2001) reported that the combination of surgery and PORT had a better survival rate (65%) than surgery alone (48%) or chemoradiotherapy (51%). Ward et al.²⁵ confirmed

these data with a 15-year disease-free survival rate of 83% for patients treated with surgery and radiotherapy, compared to 23% at five years and 0% at 15 years for patients treated with surgery alone. Moreover, postoperative radiotherapy reduces the risk of distant lymph node metastases.

Overexpression of cell surface somatostatin receptors is a possible molecular target for olfactory neuroblastoma. Apparently, somatostatin analogs are a safe and effective treatment choice for patients with unresectable, locally advanced, or metastatic disease and might become a potential research direction for future studies¹⁹.

Esthesioneuroblastoma has a good rate of survival. The five-year overall survival rate ranges between 57% to 93%. Despite the high survival rates, recurrence is common and usually occurs late, highlighting the necessity of long-term monitoring²⁶.

PROGNOSTIC FACTORS FOR SURVIVAL

The prognosis of olfactory neuroblastoma depends on various factors, such as the clinical stage, the Kadish stage, orbital and/or intracranial extension, neck and distant metastases, positive margins in operative findings, preoperative radiation and chemotherapy, the age and overall health of the patient. Also, Hyams's histological grade is an essential factor in the prognosis, with an overall survival rate of 56% for low grades (I and II) and 25% for high grades (III and IV)¹⁹.

Due to the complex anatomy of the anterior skull base, assessment of the surgical margin in operative findings has a high sampling error. Complete tumor resection with an adequate safety margin in the adjacent tissue is essential. Considering that invasion of the dura is a significant factor of survival and because the

radiologic invasion is difficult to assess, radical excision of the tumor and the dura are necessary to minimize metastasis and recurrence²⁷.

OUR EXPERIENCE

A 34-year-old Caucasian man with no other known comorbidities presented to our ENT Department for a three-month history of progressive unilateral nasal obstruction, recurrent episodes of epistaxis and hyposmia. Before his admission to our clinic, he was diagnosed in another medical facility with olfactory neuroblastoma, according to the histopathological and immunohistochemical examinations. He came for further treatment with progressive growing of the tumor and worsening of symptoms over the last two weeks.

The clinical examination showed deformity of the left nasal wing, a lobulated, red-violet, easily bleeding tumor mass with a rubbery, non-friable texture and a high rate of growth (noticeable among previous consultations), which filled the left nasal fossa and the nasal vestibule, without allowing the examination of the other anatomical landmarks of the left nasal fossa. No lesions were identified in the right nasal cavity. The ophthalmological assessment revealed no visual impairment. His blood profile for haematology and biochemistry was within normal limits. No cervical lymph nodes were found.

Contrast-enhanced computed tomography scan (CECT) revealed a large, lobulated heterogeneous enhancing soft tissue density mass that filled the left nasal cavity, anterior left ethmoidal cells and the left frontal recess (Figure 1). The CT scan showed bone destruction of the left cribriform plate and crista galli, with the invasion of the left olfactory fossa and extra-axial intracranial extension apparently contained by the dura. Also, there

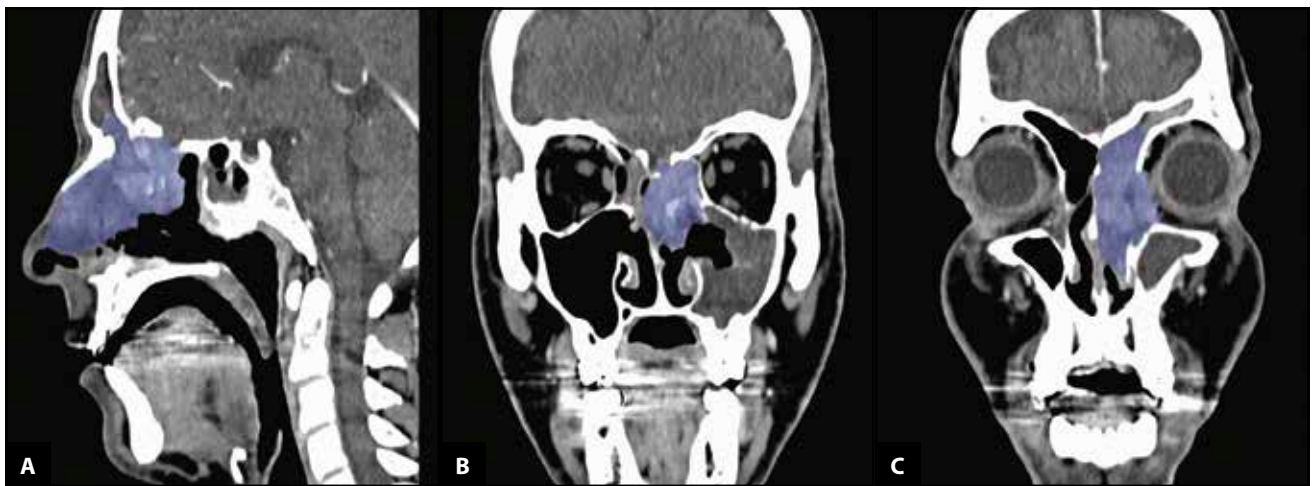


Figure 1. Contrast-enhanced computed tomography scan (CECT) sagittal (A) and coronal view (B, C) showing a heterogeneous moderate enhancement soft tissue mass occupying the left nasal fossa, with bone destruction of the left cribriform plate and intracranial extradural extension, destruction of the left medial wall of the maxillary sinus, lamina papyracea and extraconal intraorbital extension. Erosion of the posterosuperior part of the nasal septum.

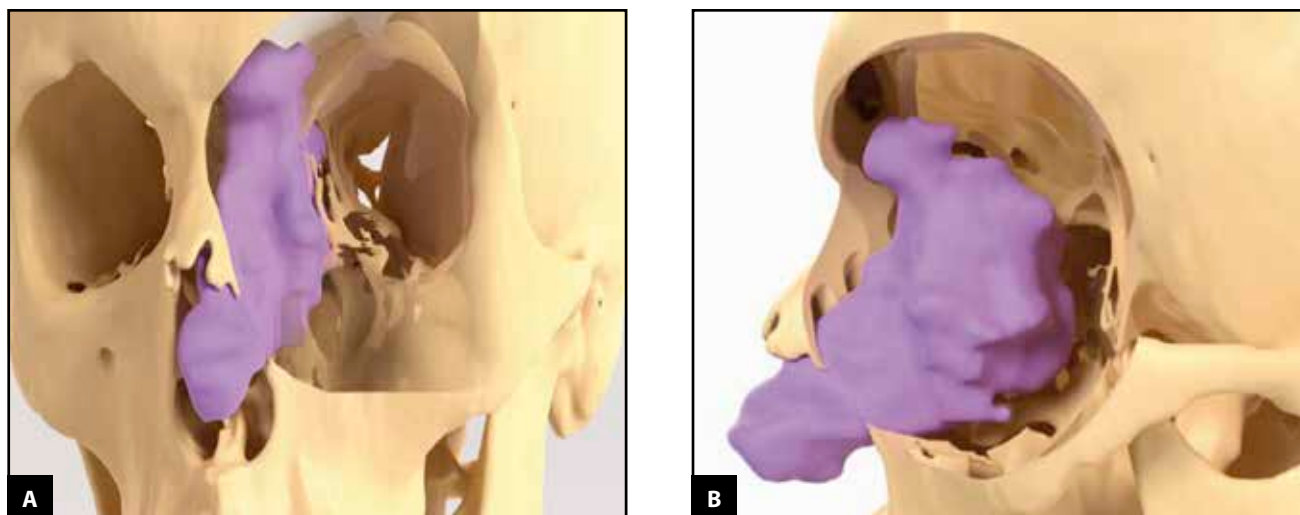


Figure 2. Screenshot of 3D slicer software showing the segmentation of the tumor on the CT scan images and the 3D reconstructed model generated from it – frontal (A) and sagittal view (B).

was bone destruction of the left medial wall of the maxillary sinus and left lamina papyracea with further infiltration of the nasolacrimal canal, the lacrimal sac and a minimal of the extraconal fat, without infiltration of the extrinsic muscles of the eyeball. Erosion of the postero-superior part of the nasal septum was noted as well (Figure 1, Figure 2).

The carotid angiography demonstrated a pathological blush of about 3-4 centimetres in diameter on the projection area of the left ethmoid sinus, with the majority supply from the left ophthalmic artery and a small part from the branches of the left maxillary artery (Figure 3).

Based on clinical and paraclinical investigations, a

multimodal approach was preferred. In order to minimize the risk of bleeding and to improve the visualization of the surgical field, distal embolization of the left maxillary artery with PVA foam particles (polyvinyl alcohol) was performed. Next, the mass was removed via lateral rhinotomy approach and the tumor was peeled away entirely from the cribriform plate with endoscopes. Safety margins were taken from the nasal septum level and the orbit's medial wall. The removed parts were sent separately for histopathological examination (Figure 4).

On histopathological examination, hematoxylin and eosin (HE) stained evaluation of the surgical specimen showed a malignant tumor proliferation with a biphasic

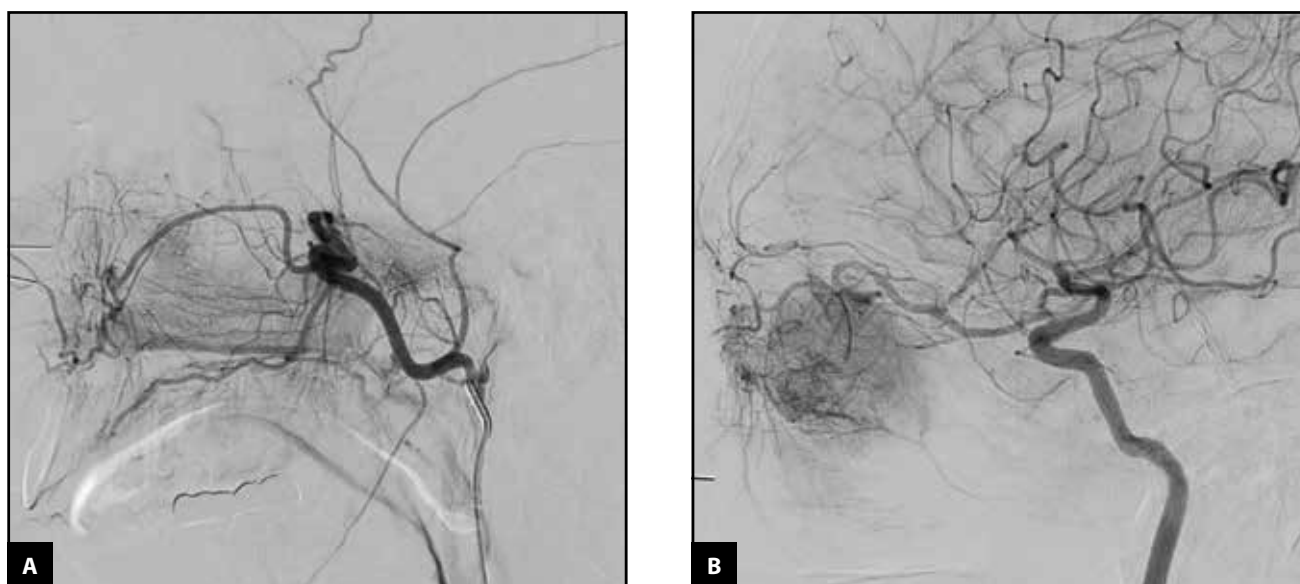

Figure 3. Bilateral carotid angiography – frontal (A) and sagittal view (B). Pathological blush of about 3-4 centimetres in diameter on the projection area of the left ethmoid sinus, with the majority supply from the left ophthalmic artery (B) and a small part from the branches of the maxillary left artery (A).

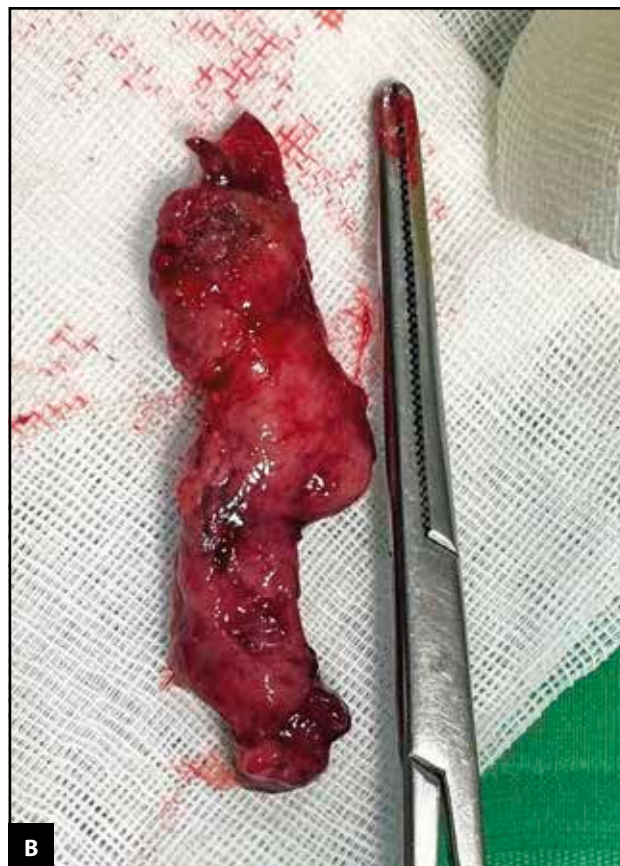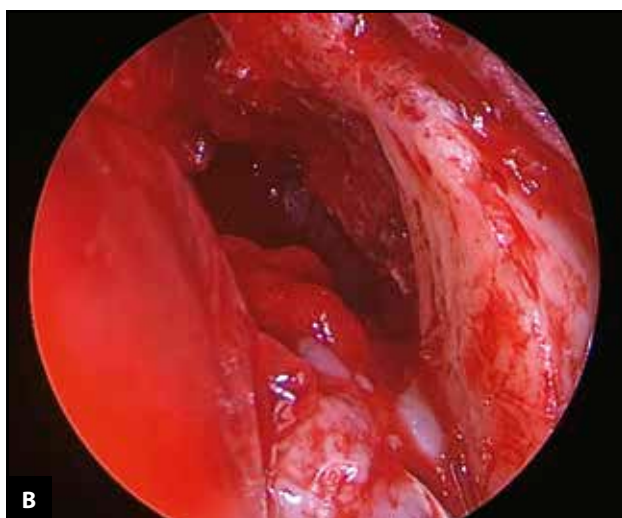

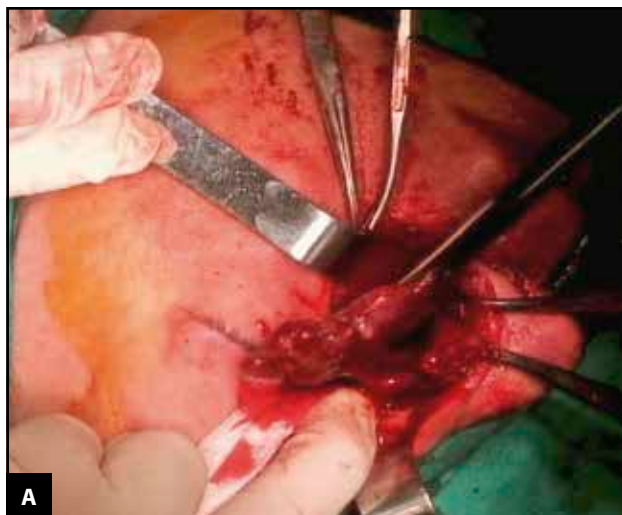
Figure 4. A. Intraoperative view – lateral rhinotomy approach; B. Endoscopic image of the tumor; C. Excised surgical specimen.

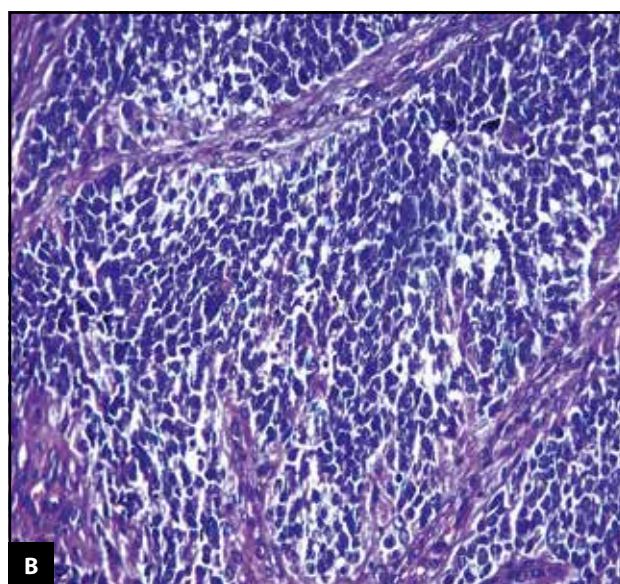
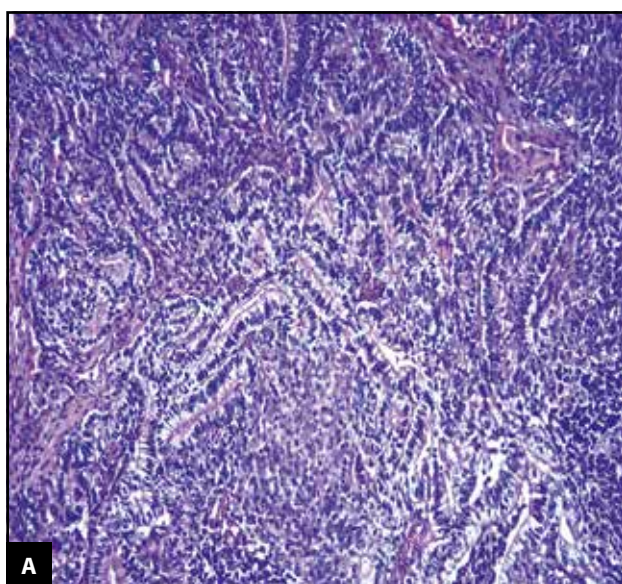


Figure 5. (A) Malignant tumor proliferation consisting of round and cylindrical malignant tumor cells arranged in an insular and pseudoglandular pattern, with the formation of rosette-type structures (HE 20X). (B) Malignant tumor proliferation with round cells with hyperchromatic nuclei arranged in an island pattern (HE 40X).

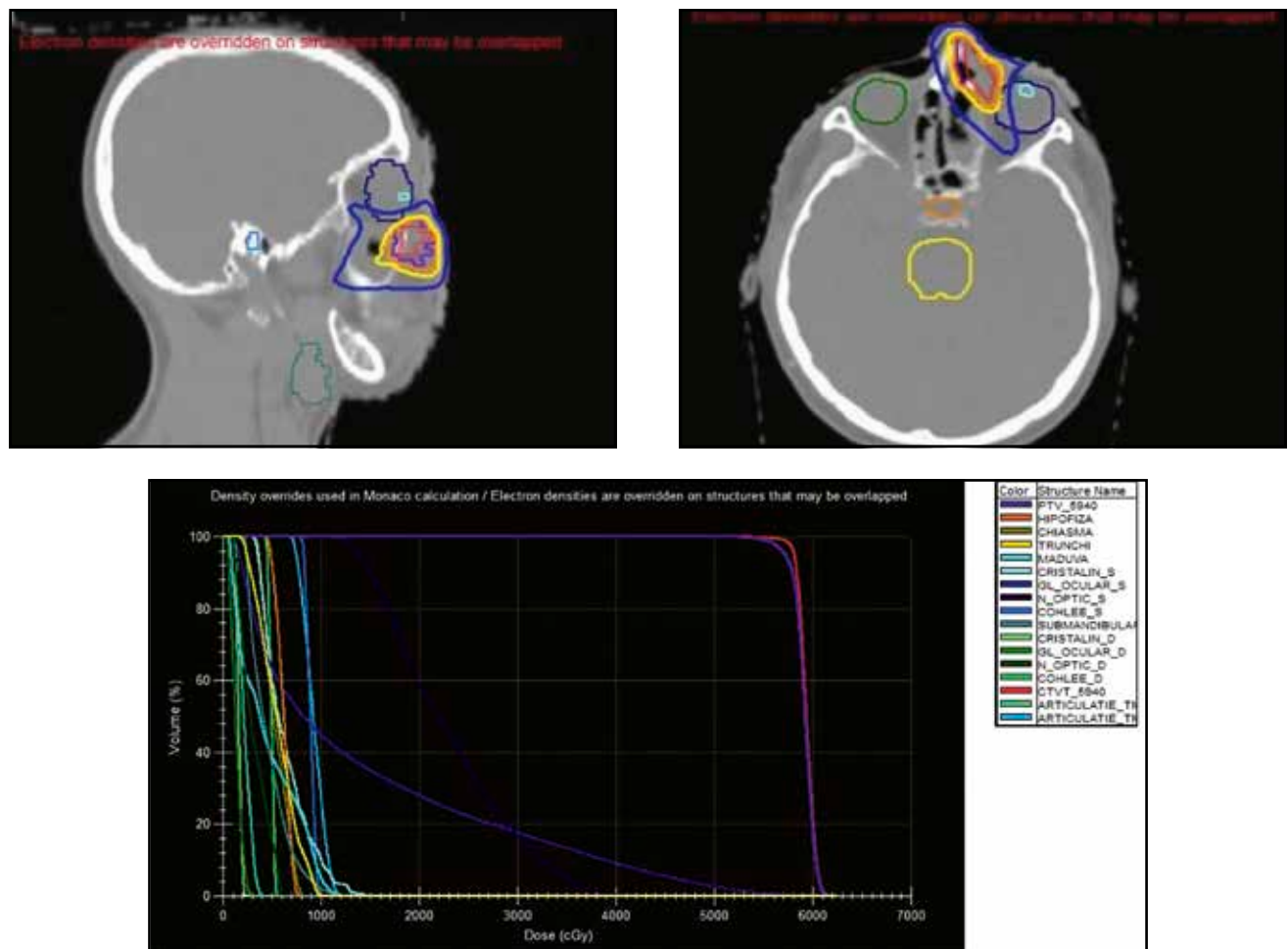


Figure 6. Intensity-modulated radiation therapy (IMRT) plans demonstrating representatives' dose for the primary site and adjacent critical normal tissue (e.g., brainstem and optic tissues).

character, with epithelial-type cells that palisaded the periphery of some islands and trabeculae with small round or ovoid/fusiform hyperchromic cells, with areas of central necrosis and haemorrhage. On immunohistochemistry, the neoplastic cell showed positivity for synaptophysin, S100, GFAP, p63, AE1/AE3/PCK26, CK7, p16. The histopathological appearance and immunohistochemical profile were characteristic of a WHO grade IV olfactory neuroblastoma (Figure 5). The surgical margins from the level of the nasal septum and the orbit's medial wall were also positive.

Given the advanced stage of the disease and positive margins, the patient was treated with postoperative intensity-modulated radiotherapy (IMRT) to the primary site and neck. The patient was scanned starting from the top of the head to the bifurcation of the trachea with a 3 mm slice thickness. The radiation was delivered five days per week, 60 Gy in 30 fractions over six weeks with a single dose of 2 Gy. The clinical target volume was defined as the gross tumor volume plus risk regions. A 5 mm margin was added to the clinical target volume (Figure 6). Concurrent chemotherapy with Cisplatin was delivered

to increase the sensitivity of tumors to radiation therapy and the patient's chances of survival. At follow-up, three months later, he was free of recurrence.

CONCLUSIONS

Olfactory neuroblastoma is a rare malignant tumor that arises from the olfactory epithelium in the upper nasal cavity. The etiology and pathogenesis are not fully understood. Because of its nonspecific symptoms and insidious evolution, most patients present with advanced-stage diseases. The optimal treatment depends on the cooperation between the ENT surgeon, neurosurgeon, radiologist, oncologist and pathologist. Indications for endoscopic surgery are progressively expanding. The optimal treatment is the combination of surgery followed by postoperative radiotherapy. Patients must be closely monitored, with the understanding that ONB has a high local recurrence rate and can occur years after therapy. The prognosis for long-term survival is poor.

Conflict of interest: The authors have no conflict of interest to declare.

Contribution of authors: All the authors have equally contributed to this work.

Financial disclosure: None.

Acknowledgments: None.

Authors' information:

Lupoi Daniel, MD, ENT Department, "Sfanta Maria" Clinical Hospital, Bucharest, Romania. E-mail: daniel.lupoi@umfcd.ro. ORCID: <https://orcid.org/0000-0003-2248-6702>.

Carmen Badea, MD, ENT Department, "Sfanta Maria" Clinical Hospital, Bucharest, Romania. E-mail: carmen.badea@drd.umfcd.ro. ORCID: <https://orcid.org/0000-0002-0296-8141>.

Bianca Rusu, Resident Doctor, ENT Department, "Sfanta Maria" Clinical Hospital, Bucharest, Romania. E-mail: bianca.rusu3663@gmail.com.

Mihai Dragomir, Resident Doctor, ENT Department, "Sfanta Maria" Clinical Hospital, Bucharest, Romania. E-mail: mihai.dragomir095@gmail.com.

REFERENCES

- Duo GS, Feng JL, Zhang ZY, Wang LJ. Survival impact of postoperative radiotherapy in patients with olfactory neuroblastoma: 513 cases from the SEER database. *Cancer Radiother.* 2022;26(5):663-9. DOI: 10.1016/j.canrad.2021.12.006.
- Kumar R. Esthesioneuroblastoma: Multimodal management and review of literature. *World J Clin Cases.* 2015;3(9):774-8. DOI: 10.12998/wjcc.v3.i9.774.
- Abdelmeguid AS. Olfactory neuroblastoma. *Curr Oncol Rep.* 2018;20(1):7. DOI: 10.1007/s11912-018-0661-6.
- Fiani B, Quadri SA, Cathel A, Farooqui M, Ramachandran A, Siddiqi I, et al. Esthesioneuroblastoma: A comprehensive review of diagnosis, management, and current treatment options. *World Neurosurg.* 2019;126:194-211. DOI: 10.1016/j.wneu.2019.03.014.
- Modesto A, Blanchard P, Tao YG, Rives M, Janot F, Serrano E, et al. Multimodal treatment and long-term outcome of patients with esthesioneuroblastoma. *Oral Oncol.* 2013;49(8):830-4. DOI: 10.1016/j.oraloncology.2013.04.013.
- Thompson LDR. Olfactory neuroblastoma. *Head Neck Pathol.* 2009;3(3):252-9. DOI: 10.1007/s12105-009-0125-2.
- Meyer C, Hamersley ERS, Manosalva RE, Torske K, McIntyre N, Mitchell A. Olfactory neuroblastoma with divergent differentiation: an unusual histologic finding in a rare tumor. *Head Neck Pathol.* 2017;11(4):531-6. DOI: 10.1007/s12105-017-0781-6.
- Kadish S, Goodman M, Wang CC. Olfactory neuroblastoma. A clinical analysis of 17 cases. *Cancer.* 1976;37(3):1571-6. DOI: 10.1002/1097-0142(197603)37:3<1571::aid-cnrcr2820370347>3.0.co;2-I.
- Morita A, Ebersold MJ, Olsen KD, Foote RL, Lewis JE, Quast LM. Esthesioneuroblastoma: prognosis and management. *Neurosurgery.* 1993;32(5):706-14; discussion 714-5. DOI: 10.1227/00006123-199305000-00002.
- Dulguerov P, Calcaterra T. Esthesioneuroblastoma: the UCLA experience 1970-1990. *Laryngoscope.* 1992;102(8):843-9. DOI: 10.1288/00005537-199208000-00001.
- Saade RE, Hanna EY, Bell D. Prognosis and biology in esthesioneuroblastoma: the emerging role of Hyams grading system. *Curr Oncol Rep.* 2015;17(1):423. DOI: 10.1007/s11912-014-0423-z.
- Goshtabi K, Abiri A, Abouzari M, Sahyouni R, Wang BY, Tajudeen BA, et al. Hyams grading as a predictor of metastasis and overall survival in esthesioneuroblastoma: a meta-analysis. *Int Forum Allergy Rhinol.* 2019;9(9):1054-62. DOI: 10.1002/alr.22373.
- Holmes M, Su SY, Bell D. Ectopic primary olfactory neuroblastoma of the maxillary sinus. *Ann Diagn Pathol.* 2016;22:45-48. DOI: 10.1016/j.anndiagnpath.2016.04.001.
- Paul D, Bhardwaj S, Yadav G, Kaushal V. Aggressiveness of esthesioneuroblastoma: a rare case report and review of literature. *Oncology in Clinical Practice.* 2022;18(6):410-4. DOI: 10.5603/OCP.2022.0041.
- Dulguerov P, Allal A, Calcaterra T. Esthesioneuroblastoma: a meta-analysis and review. *Lancet Oncol.* 2001;2(11):683-90. DOI: 10.1016/S1470-2045(01)00558-7.
- Abdelmeguid AS, Raza SM, Su SY, Kupferman M, Roberts D, DeMonte F, et al. Endoscopic resection of sinonasal malignancies. *Head Neck.* 2020;42(4):645-52. DOI: 10.1002/hed.26047.
- Gallia GL, Reh DD, Lane AP, Higgins TS, Koch W, Ishii M. Endoscopic resection of esthesioneuroblastoma. *J Clin Neurosci.* 2012;19(11):1478-82. DOI: 10.1016/j.jocn.2012.03.011.
- Eriksen JG, Bastholt L, Krogdahl AS, Hansen O, Joergensen KE. Esthesioneuroblastoma - what is the optimal treatment? *Acta Oncol.* 2000;39(2):231-5. DOI: 10.1080/028418600430833.
- Alami Z, Farhane FZ, Bouziane A, Mhirech S, Joutei SA, Hassani W, et al. Management of esthesioneuroblastoma: A retrospective study of 6 cases and literature review. *Case Rep Oncol.* 2022;15(1):176-86. DOI: 10.1159/000521736.
- Leonetti JP, Weishaar JR, Gannon D, Harmon GA, Block A, Anderson DE. Osteoradionecrosis of the skull base. *J Neurooncol.* 2020;150(3):477-82. DOI: 10.1007/s11060-020-03462-3.
- Jiang W, Mohamed ASR, Fuller CD, Kim BYS, Tang C, Gunn GB, et al. The role of elective nodal irradiation for esthesioneuroblastoma patients with clinically negative neck. *Pract Radiat Oncol.* 2016;6(4):241-7. DOI: 10.1016/j.pro.2015.10.023.
- Abdelmeguid AS, Bell D, Roberts D, Ferrarotto R, Phan J, Su SY, et al. Long-term outcomes of olfactory neuroblastoma: MD Anderson Cancer Center experience and review of the literature. *Laryngoscope.* 2022;132(2):290-7. DOI: 10.1002/lary.29732.
- Su SY, Bell D, Ferrarotto R, Phan J, Roberts D, Kupferman ME, et al. Outcomes for olfactory neuroblastoma treated with induction chemotherapy. *Head Neck.* 2017;39(8):1671-9. DOI: 10.1002/hed.24822.
- De Bonneze G, Lepage B, Rimmer J, Al Hawat A, Vairel B, Serrano E, et al. Long-term carcinologic results of advanced esthesioneuroblastoma: a systematic review. *Eur Arch Otorhinolaryngol.* 2016;273(1):21-6. DOI: 10.1007/s00405-014-3320-z.
- Ward PD, Heth JA, Thompson BG, Marentette LJ. Esthesioneuroblastoma: Results and outcomes of a single institution's experience. *Skull Base.* 2009;19(2):133-40. DOI: 10.1055/s-0028-1096195.
- Hollen TR, Morris CG, Kirwan JM, Amdur RJ, Werning JW, Vaysberg M, et al. Esthesioneuroblastoma of the nasal cavity. *Am J Clin Oncol.* 2015;38(3):311-4. DOI: 10.1097/COC.0b013e31829b5631.
- Hwang SK, Paek SH, Kim DG, Jeon YK, Chi JG, Jung HW. Olfactory neuroblastomas: survival rate and prognostic factor. *J Neurooncol.* 2002;59(3):217-26. DOI: 10.1023/a:1019937503469.

