

ORIGINAL STUDY

Maxillary sinus volume and adenoid tissue size in children: computed tomographic evaluation

Serkan Tursun¹, Nuray Bayar Muluk², Adnan Özdemir³, Gökçe Özel⁴, Ziya Şencan²

¹Pediatrics Department, Kırıkkale University, Faculty of Medicine, Kırıkkale, Turkey

²ENT Department, Kırıkkale University, Faculty of Medicine, Kırıkkale, Turkey

³Radiology Department, Kırıkkale University, Faculty of Medicine, Kırıkkale, Turkey

⁴ENT Clinics, Private Clinics, Ankara, Turkey

ABSTRACT

OBJECTIVES. Adenoid hypertrophy is related to obstructive sleep apnea syndrome (OSAS). In this study, we investigated the relationship between adenoid tissue size and maxillary sinus volumes by examining the paranasal sinus computed tomography (PNSCT) images.

MATERIAL AND METHODS. PNSCT images of 41 children were included in this study. According to the adenoid/nasopharynx (A/NP) ratio, two groups were identified. Group 1 (n=19, 9 males and 10 females): A/NP≤0.50 and Group 2 (n=22, 16 males and 6 females): A/NP>0.50. The following measurements were performed: adenoid width, NP width, A/NP ratio, air column, soft palate, maxillary sinus volume and mucosal thickening.

RESULTS. Adenoid width of group 2 (16.11±2.26 mm) was higher than that of group 1 (10.97±2.26 mm). In group 2, with an A/NP ratio of 0.61±0.07, the air column value (6.30±2.27 mm) was lower than that of group 1 with an A/NP ratio of 0.40±0.07 (air column value: 10.06±3.78 mm). NP width, soft palate and maxillary sinus volumes were not different between groups 1 and 2. As the adenoid width increased, the A/NP ratio increased, and the air column decreased.

CONCLUSION. The increase of the A/NP ratio was related to the decreased air column. In older children, air column and bilateral maxillary sinus volumes increased. In males, the adenoid width value was larger than that in females. There was no significant relationship between A/NP ratio and maxillary sinus volume or NP width values. However, higher A/NP ratio values were related to lower air column measurements.

KEYWORDS: children, adenoid width, NP width, A/NP ratio, air column, PNSCT.

INTRODUCTION

The development of the paranasal sinuses begins during the fetal life, continues after birth and matures around the age of 12¹⁻³. The development of the maxillary sinuses begins in the third week of gestation from the first branchial arch and continues through early adulthood⁴. This process includes two fast phases: 0-3 and 7-12 years old². Maxillary sinus volume increases with age in both sexes until 16 years of age¹. In the development and maturation of paranasal sinus (PNS) pneumatization, the nasopharyngeal area is estimated to provide positive pressure^{1,4}.

Adenoid hypertrophy is one of the most common diseases in the pediatric population. Due to its location, adenoid tissue may have negative effects on physiological development

and changes in facial development. Moreover, many known adverse effects of adenoid hypertrophy include maxillo-facial developmental disorders, Eustachian tube dysfunction and various degrees of ear diseases (acute, recurrent or chronic suppurative otitis media or otitis media with effusion), nasal and paranasal sinus diseases (acute, recurrent or chronic viral or bacterial rhinosinusitis)⁵⁻⁷.

Adenoid hypertrophy and narrowing in the air column can be shown on a lateral nasopharynx graphy. Adenoid hypertrophy can also be evaluated by CT scans and MRI, which are not routinely obtained for adenoid hypertrophy⁸.

The present study aims to examine the relationship between adenoid tissue size and the volume of the maxillary sinuses by examining the PNS computed tomography images retrospectively in children aged 7-14 years.

Corresponding author: Dr. Nuray Bayar Muluk, ENT Department, Kırıkkale University, Faculty of Medicine, Kırıkkale, Turkey

Address: Birlik Mahallesi, Zirvekent 2. Etap Sitesi, C-3 blok, No: 6-3/43, 06610, Çankaya / Ankara, Turkey

ORCID: <https://orcid.org/0000-0003-3602-9289>

e-mail: nuray.bayar@yahoo.com; nurayb@hotmail.com

Received for publication: June 13, 2023 / **Accepted:** July 12, 2023

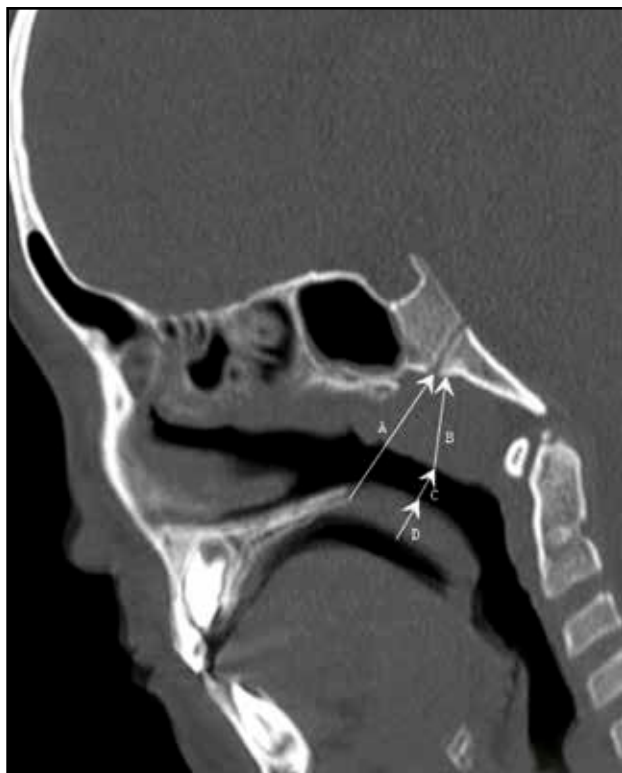


Figure 1. On sagittal PNSCT: (A) nasopharyngeal width (the distance between hard palate upper posterior superior edge and the sphenobasioccipital synchondrosis), (B) adenoid width (it is calculated from the maximal convexity point), (C) air column, which is the width of the nasopharyngeal air column from the maximal convexity point of the adenoid and soft palate) and (D) soft palate measurements are shown.

MATERIAL AND METHODS

This retrospective study was conducted in Pediatrics, Otorhinolaryngology and Radiology Departments of the Kırkkale University, Faculty of Medicine, according to the principles of the Declaration of Helsinki. Paranasal sinus computerized tomography (PNSCT) images were obtained from the database of the Radiology Department, Kırkkale University, Faculty of Medicine. Ethics committee approval was obtained from the Kırkkale University Non-invasive Research Ethics Committee (Date: February 19, 2020; Number: 2020.02.14).

Subjects

This study was performed retrospectively. PNSCT images of 41 children were included in the present study. According to the adenoid/nasopharynx (A/NP) ratio, two groups were identified: Group 1 (n=19): A/NP \leq 0.50; Group 2 (n=22): A/NP $>$ 0.50.

Indications for PNSCT in children in groups 1 and 2 were persistent nasal obstruction or discharge, chronic headache, chronic cough and periorbital diseases.

Subjects with previous trauma or surgery history, sinonasal polyposis, tumor, sinonasal CSF leak, marked nasal septal deformity, marked facial deformity, and chronic diseases, such

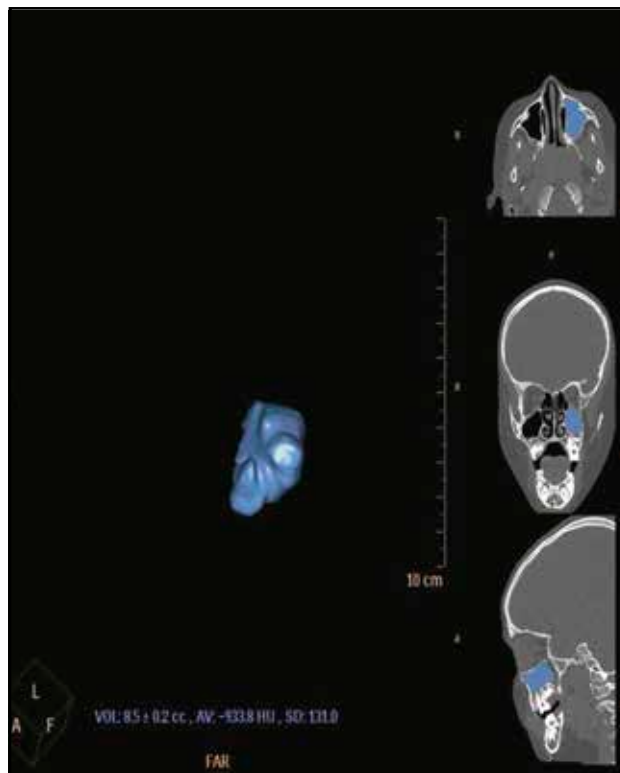


Figure 2. Three-dimensional (axial, coronal and sagittal planes) CT reconstruction images of maxillary sinus volume in a 10-year-old boy.

as chronic kidney failure, hyperparathyroidism, were not included in this study.

In children aged 7 to 14 years, PNSCT is not taken in routine medical approaches. Therefore, the number of children in groups 1 and 2 was small, which is the limitation of our study.

Paranasal Sinus Computed Tomography (PNSCT) Measurements

The CT scans were performed in the prone position, the head in hyperextension, without contrast and sedation. The routine paranasal CT protocol, 64-slice CT (Brilliance CT system; Philips Healthcare, Cleveland, OH) was used for computed tomographic examinations. The parameters used in imaging were: tube voltage = 120 kV; effective, mAs = 350; slice thickness = 1.00 mm; field of vision = 180 mm; and the image matrix = 768 x 768. Reconstruction images were obtained. The evaluation was performed on three-plane (axial, coronal and sagittal) images at the workstation.

After scanning, the volumes of the maxillary sinuses were automatically calculated with a volume rendering technique (VRT) in the workstation (Extended Brilliance; Philips Medical Systems).

The measurements were performed by the same radiologist (A.Ö.):

1. Adenoidal-nasopharyngeal ratios (A/NP ratios) were calculated according to the method of Fujioka et al.⁹ (Figure 1).

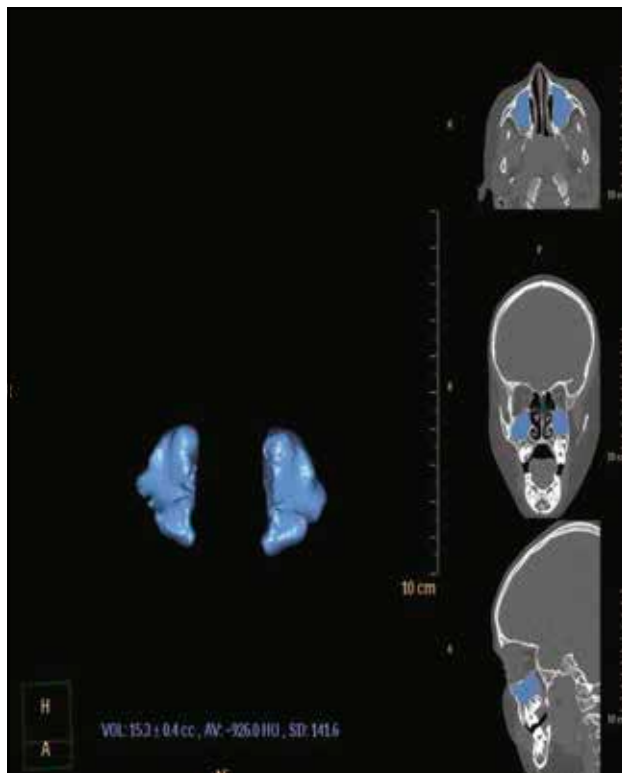


Figure 3. Three-dimensional (axial, coronal, and sagittal planes) reconstruction images of bilateral maxillary sinus volume of the same patient are shown.

The measurement of the adenoid (A) represents the distance from the point of maximal convexity along the inferior margin of the adenoid, measured along the straight section of the anterior margin of the basiocciput. The adenoidal measurement is determined by measuring along a line dropped perpendicular to its intersection point with the line drawn along the straight section of the anterior margin of the basiocciput. The measurement of the nasopharyngeal space (NP) is taken as the distance between the posterior-superior edge of the hard palate and the anteroinferior edge of the spheno-basilar synchondrosis. The A/NP ratio is obtained by dividing the measurement for A by the value for NP.

- Air column, which is the width of the nasopharyngeal air column from the maximal convexity point of the adenoid and the soft palate, and soft palate measurements were accomplished¹⁰ (Figure 1). The measurement of the soft palate was taken from the point of maximum convexity of the soft palate, perpendicular to the anterior wall of the soft palate.
- Volume calculations of the maxillary sinus were performed using clip section and volume section 3-plane staining stages. Aeration was calculated in the air modes (Figures 2, 3). After scanning, the volumes of the maxillary sinuses were automatically calculated with a volume rendering technique (VRT) in the workstation (Exten-

Table 1. Measurement results on PNSCT.

	Group 1 (A/NF≤0.50) (n=19)			Group 2 (A/NF>0.50) (n=22)			P
	Mean	Median	Std.Dev	Mean	Median	Std.Dev	
Age	11.31	12.00	1.63	10.72	10.50	1.54	0.227*
Measurements							
Adenoid width	10.97	10.81	2.26	16.11	16.27	2.26	0.000*
NF width	27.27	26.49	3.52	26.24	25.98	2.94	0.556*
A/NF ratio	0.40	0.41	0.07	0.61	0.60	0.07	0.000*
Air column	10.06	9.51	3.78	6.30	6.46	2.27	0.000*
Soft palate	7.91	7.75	1.12	7.48	7.54	0.83	0.314*
Volume R	10.66	10.50	3.67	9.75	9.40	3.46	0.448*
Volume L	10.46	9.50	4.08	10.24	9.60	3.61	0.844*
		n	%	n	%		203.75
Maxillary sinus	Mucosal thickening - R	Present	6	31.6	7	31.8	P=0.987 χ ² =0.000
		Absent	13	68.4	15	68.2	
	Mucosal thickening - L	Present	9	47.4	4	18.2	P=0.045 χ ² =4.011
		Absent	10	52.6	18	81.8	

*p value shows the results of Mann Whitney U test; **p value shows the results of Chi-square test; A/NF – adenoid/nasopharynx ratio; R – right; L – left.

Table 2. Correlation test results*.

		Adenoid width	NF width	A/NF ratio	Air column	Soft palate	Maxillary sinus volume	
							R	L
Adenoid width	r		0.268	0.876	-0.520	-0.155	-0.010	-0.128
	p		0.090	0.000	0.000	0.333	0.952	0.424
NF width	r	0.268		-0.182	0.191	-0.062	-0.109	-0.077
	p	0.090		0.256	0.231	0.700	0.497	0.632
Air column	r	0.876	-0.182			-0.648	-0.163	0.067
	p	0.000	0.256			0.000	0.307	0.678
Air column	r	-0.520	0.191	-0.648			0.185	0.165
	p	0.000	0.231	0.000			0.247	0.303
Soft palate	r	-0.155	-0.062	-0.163	0.185			0.037
	p	0.333	0.700	0.307	0.247			0.819
Maxillary sinus volume	R	r	-0.010	-0.109	0.067	0.165	0.037	
		p	0.952	0.497	0.678	0.303	0.819	
	L	r	-0.128	-0.077	-0.058	0.246	0.048	0.904
		p	0.424	0.632	0.720	0.121	0.765	0.000
Age	r	-0.222	-0.105	-0.149	0.343	0.167	0.505	0.471
	p	0.164	0.515	0.353	0.028	0.296	0.001	0.002
Gender	r	-0.330	-0.235	-0.226	-0.114	-0.114	0.211	0.281
	p	0.035	0.140	0.155	0.478	0.477	0.185	0.075
A/NF Group (Code 1: A/NF≤0.50, Code 2: A/NF>0.50)	r	0.769	-0.093	0.864	-0.616	-0.159	0.031	-0.120
	p	0.000	0.563	0.000	0.000	0.320	0.847	0.455

*p value shows the results of Spearman's correlation rho efficient test; r – shows correlation coefficient; p – shows statistically significance; R – right; L – left; A/NF – adenoid/nasopharynx ratio

ded Brilliance; Philips Medical Systems).

4. Radiologically, sinusitis was defined as thickening sinus ostium or sinus walls at least 3 mm in CT images.

Statistical Analysis

For the statistical analysis, the SPSS for Windows 16.0 (SPSS, INC, an IBM Company, Chicago, Illinois) was used. Chi-square test, Mann-Whitney U test, and Spearman's correlation rho efficient test were used. A p-value < 0.05 was considered statistically significant.

RESULTS

In Group 1 (A/NP≤0.50), there were nine (47.4%) males and 10 (52.6%) females. In Group 2 (A/NP>0.50), there were 16 (72.7%) males and six (27.3%) females. There were no significant differences between groups from the sex distri-

bution point of view (p=0.097, $\chi^2=2.755$). The mean age of Group 1 was 11.31±1.63 years (ranged from 9.00 to 13.00 years) and 10.72±1.54 years (ranged from 9.00 to 13.00 years) in Group 2. There were no significant differences between ages of groups (p=0.227).

Adenoid width

The adenoid width of Group 2 (16.11±2.26 mm) (min: 11.22 mm, max: 21.25 mm) was significantly higher than that of Group 1 (10.97±2.26 mm) (min: 5.67 mm, max: 15.10 mm) (p=0.000) (Table 1).

NP width

There were no significant differences between NP width values of Group 1 (27.27±3.52 mm) (min: 22.41 mm, max: 37.48 mm) and Group 2 (26.24±2.94 mm) (min: 21.17 mm, max: 33.22 mm) (p=0.556) (Table 1).

A/NP ratio

The A/NP ratio of Group 2 (0.61±0.07) was significantly

higher than that of Group 1 (0.40 ± 0.07) ($p=0.000$) (Table 1). This is an expected result as the groups were performed according to the adenoid/nasopharynx (A/NP) ratio (Group 1: $A/NP\leq 0.50$; Group 2 $A/NP>0.50$).

Air column

The air column value of Group 2 (6.30 ± 2.27 mm) (min: 0.82 mm, max: 9.98 mm) was significantly lower than that of Group 1 (10.06 ± 3.78 mm) (min: 5.75 mm, max: 23.52 mm) ($p=0.000$) (Table 1).

Soft palate

There were no significant differences between the soft palate values of Group 1 (7.91 ± 1.12 mm) (min: 5.77 mm, max: 11.35 mm) and Group 2 (7.48 ± 0.83 mm) (min: 5.57 mm, max: 8.81 mm) ($p=0.314$) (Table 1). The soft palate is also important for the air passage of the participants.

Maxillary sinus volume

There were no significant differences between maxillary sinus volumes of Groups 1 and 2 bilaterally ($p>0.05$) (Table 1). In Group 1, the right maxillary sinus volume was 10.66 ± 3.67 mm³ (min: 5.60 mm³, max: 17.90 mm³), the left maxillary sinus volume was 10.46 ± 4.08 mm³ (min: 5.20 mm³, max: 21.30 mm³). In Group 2, the right maxillary sinus volume was 9.75 ± 3.46 mm³ (min: 2.10 mm³, max: 16.30 mm³), the left maxillary sinus volume was 10.24 ± 3.61 mm³ (min: 2.00 mm³, max: 16.90 mm³).

Maxillary sinus mucosal thickening

In Group 1, maxillary sinus mucosal thickening on the left side was detected in 47.4% of the children. In Group 2, it was detected in 18.2% of the children ($p=0.045$) (Table 1).

On the right side, there were no significant differences between maxillary sinus mucosal thickness values of Groups 1 and 2 ($p=0.987$) (Table 1).

Correlation test results

As the adenoid width increased, the A/NP ratio increased and the air column decreased ($p<0.05$) (Table 2, Figure 4).

There were positive correlations between right and left maxillary sinus volume values ($p<0.05$) (Table 2). As the right maxillary sinus volume increased, the left maxillary volume also increased. There were no significant correlations between maxillary sinus volume and NF width, A/NF ratio ($p>0.05$) (Table 2). As the right ($p=0.001$, $r: -0.514$) and left maxillary sinus volume ($p:0.000$, $r: -0.563$) increased, left maxillary sinus mucosal thickening decreased. There were no significant correlations between right ($p=0.085$, $r: -0.273$) and left maxillary sinus volumes ($p=0.061$, $r: -0.295$) and right maxillary sinus mucosal thickening.

As age increased, the air column and bilateral maxillary sinus volumes increased ($p<0.05$) (Table 2).

In males, the adenoid width value was larger than that in females ($p<0.05$) (Table 2).

DISCUSSIONS

Upper respiratory tract and paranasal sinus diseases have an important place in the daily clinical practice of pediatri-

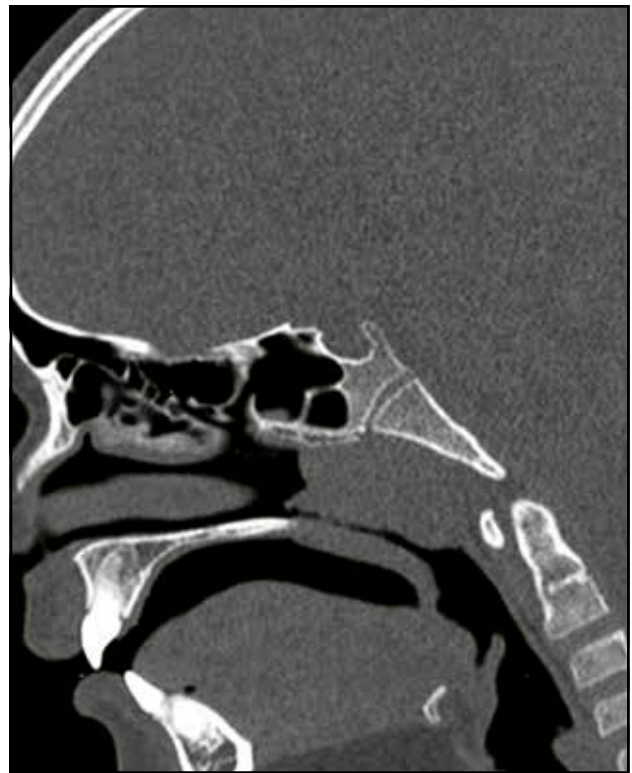

Figure 4. Sagittal PNSCT image of the patient with $A/NP>0.50$. The significant narrowing is observed in the air column.

cians and otolaryngologists. Adenoid hypertrophy is one of the most frequent disorders in the pediatric population. This study was planned to provide an understanding of the relationship of adenoid hypertrophy with the morphological structure and volume of the maxillary sinuses. Genetic effects are not the only main factor of craniofacial growth in childhood. Nasal obstruction caused by allergic rhinitis, adenoid hypertrophy and nasal septal disorders also affect craniofacial growth¹¹.

During the development process, adenoid tissue size may also affect the volume and aeration of the maxillary sinuses (paranasal sinuses). However, there are few studies in the literature that investigate these effects, which remained under-researched^{2,12}.

In the present study, we investigated the relationship between the adenoid volume, nasopharynx width and maxillary sinus volume in children aged ranged from 7 to 14, which corresponds to the rapid growth and development phase of the maxillary sinuses^{1,2,13,14}. The findings obtained in this study showed that there were no significant differences between NP width values of Group 1, patients with A/NP ratio ≤ 0.50 , (27.27 ± 3.52 mm) and Group 2, patients with A/NP ratio > 0.50 , (26.24 ± 2.94 mm). The adenoid width of Group 2 (16.11 ± 2.26 mm) was higher than that of Group 1 (10.97 ± 2.26 mm). In Group 2, with an A/NP ratio of 0.61 ± 0.07 , the air column value (6.30 ± 2.27 mm) was lower than that of Group 1

with an A/NP ratio of 0.40 ± 0.07 (air column value: 10.06 ± 3.78 mm).

There is a close relationship between adenoid tissue and paranasal sinuses. Maxillary sinuses are the largest sinuses in paranasal sinuses. Anatomical and developmental definitions of the maxillary sinus can be clinically significant. Pneumatization and normal development of children's sinuses can serve as a reference to assessing the normal or abnormal development of maxillary sinuses. Normal values and clinical indexes can be used in diagnosis, preoperative evaluation and treatment planning^{1,3}. Adenoidal-nasopharyngeal ratio affects and/or relates to the height of the maxilla in the "hypoplasia of the naso-maxillary complex" as a part of adenoid face features¹⁵.

Both in adults with obstructive sleep apnea syndrome (OSAS) and children with adenoid hypertrophy, in patients with narrow nasal and/or nasopharyngeal airway obstruction, there were differences between the maxilla sizes and other cranial bones (e.g., mandible)^{11,16}.

In our study, there were no significant differences between the soft palate values of Group 1 (7.91 ± 1.12 mm) and Group 2 (7.48 ± 0.83 mm). Similarly, maxillary sinus volume was not different in Groups 1 and 2. In Group 1, maxillary sinus mucosal thickening on the left side was detected in 47.4% of the children. In Group 2, it was detected in 18.2% of the children. There were positive correlations between right and left maxillary sinus volume values.

The development of the maxilla and mandible is related to the transfer of neural crest cells to the first branchial arch¹⁷. During the gradual expansion of the maxillary bone, the maxillary sinus is centered¹⁸. However, this process and growth stages are quite variable. At birth, the greatest width is observed in the anterior-posterior direction. Subsequently, during the first year, growth occurs towards the deep plane of the orbit. Between the ages of 4 and 9, lateral growth takes place, and beyond the age of nine, growth progresses towards the inferior part and the hard palate.

The formation of permanent teeth is the final phase of pneumatization¹⁸. Dentoalveolar heights of the maxillary molars and the rate of upper and lower anterior face heights seem to be associated with changes in the respiratory mode from mouth to nose breath after adenoidectomy¹⁹.

In the present study, as adenoid width increased, the A/NP ratio increased, and the air column decreased. The increase in the A/NP ratio was related to the decreased air column. In older children, air column and bilateral maxillary sinus volumes increased. In males, the adenoid width value was larger than that in females. Similarly, Talebian et al. found that male adenoid size on lateral neck radiography was significantly higher than that of the females²⁰.

The maxillary sinus that develops due to too many phases is very inevitable in volume and variation. Passing these maxillary growth phases in childhood and decreasing the nasal airflow due to the adenoid vegetation frequently seen in this period cause "a retropositioned hyoid bone, a narrow upper dental arch, retropositioned mandibular incisors, increased

anterior face-height, a narrower V-shaped maxillary arch, increased mandibular plane angle, and a posterior-rotated mandible" in comparison with healthy controls²¹.

Pediatric obstructive sleep apnea syndrome pathophysiology is multifactorial. The most common cause is the excessive growth of adenoids and tonsils, which cause upper airway restriction during sleep. Accordingly, primary care is called tonsillectomy with or without adenoidectomy²².

Obstructive sleep apnea syndrome prevalence is highest between the ages of 2-8, as the development of pharyngeal lymphatic tissue causes maximum narrowing of airway lumens. Sagittal Cranial MRI planes from 189 children and adults without clinical signs of adenoid hypertrophy showed that pharyngeal tonsils reach the maximum size between 7-10 years. Moderate to severe obstructive sleep apnea syndrome (AHI > 5/h) treatment in children with adenoid and/or tonsil hypertrophy is an adenotonsillectomy²³.

CONCLUSIONS

In conclusion, we showed no significant relationship between A/NP ratio and maxillary sinus volume or NP width values. However, higher A/NP ratio values were related to lower air column measurements.

Financial disclosure: There are no financial disclosures of the authors.

Conflict of interest: The author Serkan Tursun declares that he has no conflict of interest. The author Nuray Bayar Muluk declares that she has no conflict of interest. The author Adnan Özdemir declares that he has no conflict of interest. The author Gökçe Özel declares that he has no conflict of interest. The author Ziya Şencan declares that he has no conflict of interest.

Ethics committee approval: This study is retrospective. Ethics committee approval was obtained from Kırıkkale University Non-invasive Research Ethics Committee (Date: February 19, 2020; Number: 2020.02.14)

Informed consent: There is no need to take informed consent, because the data were evaluated retrospectively.

There are no funds for this article.

Author contributions: Serkan Tursun: Planning, designing, data collection, literature survey, writing. Nuray Bayar Muluk: Planning, designing, literature survey, statistical analysis, interpretation of the results, writing, submission. Adnan Özdemir: Planning, designing, data collection, literature survey. Gökçe Özel: Planning, designing, data collection, literature survey. Ziya Şencan: Planning, designing, data collection, literature survey, writing.

Authors' information:

Serkan Tursun, MD, Associate professor, Pediatrics Department, Kırıkkale University, Faculty of Medicine, Kırıkkale, Turkey. E-mail: drtursun@hotmail.com.

Nuray Bayar Muluk, MD, Professor, ENT Depart-

ment, Kırıkkale University, Faculty of Medicine, Kırıkkale, Turkey. E-mail: nuray.bayar@yahoo.com. ORCID: <https://orcid.org/0000-0003-3602-9289>.

Adnan Özdemir, MD, Associate professor, Radiology Department, Kırıkkale University, Faculty of Medicine, Kırıkkale, Turkey. E-mail: dradnanozdemir@hotmail.com.

Gökçe Özel, MD, Professor, ENT Clinics, Private Clinics, Ankara, Turkey. E-mail: gokceozel26@gmail.com.

Ziya Şencan, MD, Doctor Faculty Member, ENT Department, Kırıkkale University, Faculty of Medicine, Kırıkkale, Turkey. E-mail: drsencan@gmail.com.

REFERENCES

- Değermenci M, Ertekin T, Ülger H, Acer N, Coskun A. The age-related development of maxillary sinus in children. *J Craniofac Surg*. 2016;27(1):e38-44. DOI: 10.1097/SCS.0000000000002304.
- Apuhan T, Yıldırım YS, Özasan H. The developmental relation between adenoid tissue and paranasal sinus volumes in 3-dimensional computed tomography assessment. *Otolaryngol Head Neck Surg*. 2011;144(6):964-71. DOI: 10.1177/0194599811399712.
- Lorkiewicz-Muszynska D, Kociemba W, Rewekant A, Sroka A, Jonczyk-Potoczna K, Patelska-Banaszewska M, et al. Development of the maxillary sinus from birth to age 18. Postnatal growth pattern. *Int J Pediatr Otorhinolaryngol*. 2015;79(9):1393-400. DOI: 10.1016/j.ijporl.2015.05.032.
- Kim J, Song SW, Cho JH, Chang KH, Jun BC. Comparative study of the pneumatization of the mastoid air cells and paranasal sinuses using three-dimensional reconstruction of computed tomography scans. *Surg Radiol Anat*. 2010;32(6):593-9. DOI: 10.1007/s00276-009-0618-4.
- Pagella F, Colombo A, Gatti O, Giourgos G, Matti E. Rhinosinusitis and otitis media: the link with adenoids. *Int J Immunopathol Pharmacol*. 2010;23(1 Suppl):38-40.
- Nikakhlagh S, Rahim F, Boostani H, Shirazi STB, Saki N. The effect of adenotonsillectomy on quality of life in adults and pediatric patients. *Indian J Otolaryngol Head Neck Surg*. 2012;64(2):181-3. DOI: 10.1007/s12070-011-0244-4.
- Tuncer U, Aydoğan B, Soyulu L, Simsek M, Akcalı C, Kucukcan A. Chronic rhinosinusitis and adenoid hypertrophy in children. *Am J Otolaryngol*. 2004;25(1):5-10. DOI: 10.1016/j.amjoto.2003.10.003.
- Friedman M. Sleep apnea and snoring surgical and nonsurgical therapy. Saunders: Elsevier; 2009, pp. 425.
- Fujioka M, Young LW, Girdany BR. Radiographic evaluation of adenoidal size in children: adenoidal-nasopharyngeal ratio. *Am J Roentgenol*. 1979;133(3):401-4. DOI: 10.2214/ajr.133.3.401.
- Feres MFN, Hermann JS, Sallum AC, Pignatari SSN. Radiographic adenoid evaluation—suggestion of referral parameters. *J Pediatr (Rio J)*. 2014;90(3):279-85. DOI: 10.1016/j.jped.2013.09.004.
- Juliano ML, Machado MAC, Carvalho LBC, Zancanella E, Santos GMS, Prado LBF, et al. Polysomnographic findings are associated with cephalometric measurements in mouth-breathing children. *J Clin Sleep Med*. 2009;5(6):554-61.
- Berçin S, Kutluhan A, Çetin H, Yurttas V. Relationship between adenoid vegetation and anatomic variations of paranasal sinuses. *Acta Otolaryngol*. 2008;128(10):1116-9. DOI: 10.1080/00016480701854735.
- Park IH, Song JS, Choi H, Kim TH, Hoon S, Lee SH, et al. Volumetric study in the development of paranasal sinuses by CT imaging in Asian: a pilot study. *Int J Pediatr Otorhinolaryngol*. 2010;74(12):1347-50. DOI: 10.1016/j.ijporl.2010.08.018.
- Lee DH, Shin JH, Lee DC. Three-dimensional morphometric analysis of paranasal sinuses and mastoid air cell system using computed tomography in pediatric population. *Int J Pediatr Otorhinolaryngol*. 2012;76(11):1642-6. DOI: 10.1016/j.ijporl.2012.07.037.
- Ant A, Kemaloglu YK, Yılmaz M, Dilci A. Craniofacial deviations in the children with nasal obstruction. *J Craniofac Surg*. 2017;28(3):625-8. DOI: 10.1097/SCS.0000000000003409.
- Cuccia AM, Campisi G, Cannavale R, Colella G. Obesity and craniofacial variables in subjects with obstructive sleep apnea syndrome: comparison of cephalometric values. *Head Face Med*. 2007;3:41. DOI: 10.1186/1746-160X-3-41.
- Gilbert SF. *Developmental Biology*. 8th edition. Sunderland: Sinauer Associates; 2006.
- Scuderi AJ, Harnsberger HR, Boyer RS. Pneumatization of the paranasal sinuses: normal features of importance to the accurate interpretation of CT scans and MR images. *AJR Am J Roentgenol*. 1993;160(5):1101-4. DOI: 10.2214/ajr.160.5.8470585.
- Mahony D, Karsten A, Linder-Aronson S. Effects of adenoidectomy and changed mode of breathing on incisor and molar dentoalveolar heights and anterior face heights. *Aust Orthod J*. 2004;20(2):93-8.
- Talebian S, Sharifzadeh G, Vakili I, Golboie SH. Comparison of adenoid size in lateral radiographic, pathologic, and endoscopic measurements. *Electron Physician*. 2018;10(6):6935-41. DOI: 10.19082/6935.
- Raffat A, Hamid W. Cephalometric assessment of patients with adenoidal faces. *J Pak Med Assoc*. 2009;59(11):747-52.
- Bitners AC, Arens R. Evaluation and management of children with obstructive sleep apnea syndrome. *Lung*. 2020;198(2):257-70. DOI: 10.1007/s00408-020-00342-5.
- Tsara V, Amfilochiou A, Papagrigorakis JM, Georgopoulos D, Liolios E, Kadithis A, et al. Guidelines for diagnosing and treating sleep-related breathing disorders in adults and children (Part 3: obstructive sleep apnea in children, diagnosis and treatment). *Hippokratia*. 2010;14(1):57-62.

