

## ORIGINAL STUDY

# Laryngeal coccidioidomycosis in adults: systematic review of the literature and a case report

Carolina Verde Lizárraga<sup>1</sup> , José Roberto Reina Loaiza<sup>1</sup> , Karen Alejandra Leal Tapia<sup>2</sup> , Juan Antonio Lugo Machado<sup>1</sup> 

<sup>1</sup>Otorhinolaryngology Service, “Luis Donaldo Colosio Murrieta” Specialties Hospital No. 2, Mexican Institute of Social Security, Ciudad Obregon, Sonora, Mexico

<sup>2</sup>Pathological Anatomy Service, Regional General Hospital No. 1, Mexican Institute of Social Security, Ciudad Obregon, Sonora, Mexico

## ABSTRACT

**BACKGROUND.** Coccidioidomycosis spp. is a dimorphic fungus endemic to the southwestern United States and northern Mexico. Incidences in high-risk locations have increased over the last years.

**MATERIAL AND METHODS.** A systematic review has been carried out following the PRISMA guidelines of the reports found in PubMed, Scopus, Google Scholar databases from 1953 to 2023. We included articles written in the English language, with the following keywords “laryngeal” and “coccidioidomycosis” and “adults”, “upper respiratory tract” and “coccidioidomycosis” and “adults”.

**RESULTS.** In the review, we could access 8 publications with a total of 10 cases in which 7 men and 3 women were reported, with a mean age of 49.3 years. The ten reported cases were from the southern region of the United States, which borders our state of Sonora in the north. Also, we report the case of a 24-year-old male patient, who presented a chronic picture of more than 1 year with dysphonia, worsening in the last month. He underwent direct laryngoscopy with biopsy, resulting in the diagnosis of laryngeal coccidioidomycosis. Our patient had multiple comorbidities, among which chronic kidney disease in treatment with peritoneal dialysis, erythropoietin and prednisone, with a history of renal transplant in 2017, rejected in 2019.

**CONCLUSION.** Laryngeal coccidioidomycosis is a diagnostic challenge for the clinician, its characteristics may appear to be a malignant entity, up to the formation of abscesses and even present bone destruction. The geographical area in which we are located makes it necessary to always include coccidioidomycosis as a pathology to rule out in our patients.

**KEYWORDS:** larynx, coccidioidomycosis, adult, systematic review.

## INTRODUCTION

Coccidioides immitis is a dimorphic fungus endemic to the southwestern United States and northern Mexico<sup>1</sup>. Incidences in high-risk locations have increased from 5.3 cases per 100,000 in 1998 to 42.6 per 100,000 cases in 2011<sup>2</sup>. Contagion occurs when arthroconidia or spores of the fungus, which detach from the ground, are inhaled, thus colonizing the airway. The geographic areas with the largest endemic sources of infection are in California and Arizona, United States<sup>3,4</sup>. However, they can also be seen in Mexico and Central America<sup>1</sup>.

Coccidioidomycosis was first described in 1892 by Wer-

nicke, and it was not until 1937 that *C. immitis* was identified as the cause of the disease<sup>2</sup>. The first diagnosis in Mexico was made by Dr. Gastón Madrid in Hermosillo, Sonora, who reported a case in 1945<sup>3</sup>. The patient was referred for a possible diagnosis of tuberculosis to the Sanatorium in Hermosillo, the capital of Sonora, a state that shares the border between the United States and Mexico, bordering Arizona. The bacteriology for tuberculosis in this patient was negative despite the suggestive clinical and radiological features. A culture was ordered for a fungus, where *Coccidioides* spp. was isolated in the sputum. Three years later, Dr. Madrid reported a number of cases of coccidioidomycosis diagnosed in the region<sup>4</sup>.

The most common presentation includes symptoms of

**Corresponding author:** Juan Antonio Lugo Machado, Otorhinolaryngology Service, “Luis Donaldo Colosio Murrieta” Specialties Hospital No. 2, Mexican Institute of Social Security, Ciudad Obregon, Sonora, Mexico

**Address:** Calle Hidalgo Pte. S / N, Bellavista, 85130 Cd Obregón, Sonora, Mexico

**ORCID:** <https://orcid.org/0000-0003-4864-8546>. **e-mail:** otorrinnox@gmail.com

**Received for publication:** August 12, 2023 / **Accepted:** September 11, 2023

chronic fatigue, malaise and productive cough; episodes of occasional arthralgias are also common with a primary lung source<sup>5</sup>. The risk factors associated with severe or disseminated infections are immunosuppressed states, such as: AIDS, solid organ transplant recipients<sup>6,8</sup>, lymphomas, or long-term steroid use<sup>9</sup>. In 60% of coccidioidomycosis cases, lung infection may be asymptomatic or mild and may occur within an incubation period of 8 to 30 days<sup>10,11</sup>. While the vast majority of coccidioidomycosis infections have a primary pulmonary origin, primary coccidioidomycosis of the larynx is a very rare and unusual presentation<sup>6</sup>. In the lung, parenchyma arthroconidia take the form of spherules containing endospores triggering a local immune response<sup>7</sup>. However, when the endospores are released, the spread that causes the disease is generated, presenting a reaction strong enough to experience moderate to severe disease in almost 40% of the cases<sup>11,12</sup>. These pulmonary symptoms are often associated with fever, malaise, arthralgia, nocturnal diaphoresis, and sometimes with cutaneous signs such as erythema nodosum<sup>7</sup>. In less than 2% of the cases, the disease becomes disseminated, aggressive or fulminant<sup>10</sup>.

In a 2019 retrospective review of extrapulmonary manifestations of coccidioidomycosis, the organs affected in children were the bones, particularly the spine and joints (33%), the mediastinum (19%), the central nervous system (19%), cervical lymph nodes (15%), the larynx (6%) and the skin (5%)<sup>11</sup>, with limited reports of the larynx in adults.

Histologically, a mixed granulomatous and suppurative process is present. Mononuclear infiltration is observed when macrophages phagocytize spherules, forming multinucleated or Langerhans giant cells<sup>13</sup>. However, the granulomatous nature of *Coccidioides*-infected tissue can be confused with a

florid carcinoma of the larynx<sup>14</sup>. Ulcerations and erosions of the submucosa have been described<sup>15</sup>. It is still debated whether the laryngeal infection represents a primary infection or is the result of a direct inoculation of the lung secretions that carry the organism<sup>7</sup>. Approximately 7% of the cases have the head and neck region affected, with the larynx being a well-documented site<sup>14</sup>. Henley-Cohn et al. documented a series of 4 cases treated at the University of California, San Francisco; all 4 patients had shortness of breath and involved abscesses deep in the neck<sup>13</sup>.

## MATERIAL AND METHODS

A systematic literature review was conducted by a pair of reviewers independently, following the PRISMA guidelines of clinical cases found in PubMed, Elsevier and Google Scholar databases from 1953 to 2023. For the PubMed research, we used the Boolean Operator [AND]. The combination of terms that yielded better results in the search engines was the following: “*laryngeal*” and “*coccidioidomycosis*” and “*adults*”, “*upper respiratory tract*” and “*coccidioidomycosis*” and “*adults*”. Before proceeding to the selection of articles, the inclusion and exclusion criteria were defined.

The inclusion criteria were those articles with cases of adult patients ( $\geq 18$  years), with coccidioidomycosis of laryngeal involvement as the primary focus or due to pulmonary dissemination, articles written in the English language, in the indicated study period.

Articles addressing  $\leq 17$ -year-old cases, involving sites other than the larynx, and cases before 1953 were excluded.

The search and data collection were carried out by a cou-

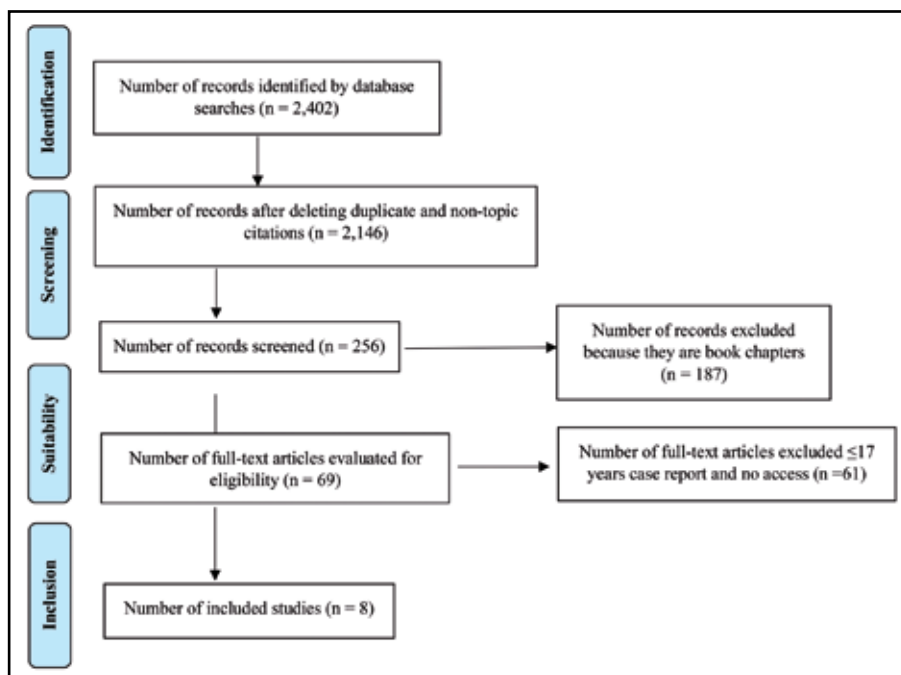


Figure 1. PRISMA diagram location and selection of articles.

ple of reviews independently, later they met to compare results and select the most relevant data to be summarized.

Our work presented some limitations to access a significant number of articles, which were of high economic cost to obtain them; this also generates a bias and limitation of our presented articles.

## RESULTS

A total of 2,402 articles were found, that included one or more of the keywords, in the indicated search databases. 2,391 articles were eliminated for being duplicates, animal studies, affection of other organs or structures, for being book chapters and for being reports of patients 17 years or younger, or not having access for consultation because it is paid, with a total of 8 writings for review. The Selection Diagram shows the flowchart for the selection of the writings (Figure 1).

In the period of review indicated, 8 articles were found, with 10 cases, in which there was a distribution by sex of 7 men and 3 women, the mean age was 49.3 years, with an age less than 34 years and greater than 75 years<sup>6,7,12,13,16-19</sup>. The ten cases reported were from the southern region of the United States, which borders our state of Sonora in the north. Table 1 summarizes the clinical characteristics of the cases.

It is evident how rare this entity is and the atypical presentation the disease can have. In all presented cases, there was a diversity of manifestations that do not give it specific characteristics. The most frequent associated symptom was dysphonia (hoarseness) in 8 patients<sup>6,7,12,13,16-18</sup> (80%) followed by dysphagia (5 patients, 50%)<sup>7,12,13,17</sup>, weight loss<sup>7,12,18,19</sup> and cough<sup>7,16,17,19</sup> (4 patients each, 40%), fever<sup>6,16,18</sup> and odynophagia<sup>7,12,19</sup> (3 patients each, 30%), sore throat<sup>6,19</sup> (2 patients), haemoptysis<sup>18,19</sup> (2 patients), dyspnea<sup>13,18</sup> (2 patients), adenopathy<sup>16</sup> (1 patient). It can manifest as a chronic process of long evolution until debuting with the formation of abscesses.

The most frequent areas of the larynx involved were the epiglottis (3 patients)<sup>7,12,17</sup>, vocal cords (3 patients)<sup>6,18,19</sup>, the ventricular bands (2 patients)<sup>17,19</sup>, the aryepiglottic folds (2 patients)<sup>7,17</sup>, arytenoids, the glottic lumen and the pyriform sinuses (1 patient each)<sup>7,17</sup>.

Most of the cases were approached thinking about more common entities, such as tuberculosis or malignant diseases. The differential diagnosis was made by sputum examination, chest X-ray, CT scans, bronchoscopy. In all cases, the positive diagnosis was established by biopsy and histopathologic examination.

The treatment of choice was antifungal therapy. In only one case the treatment consisted in iodine and irradiation without improvement<sup>12</sup>.

The cases included in our review present very marked differences in years between the cases, since cases starting with 1953 until more recently in 2020 are described. This makes it difficult to have a standardized description with limitations of imaging studies that are very different from each year to an-

other. Furthermore, one of the common characteristics of these reports is the endemic geographical area that makes it necessary to have to rule out this infrequent and difficult-to-diagnose pathology. Otherwise, it is not thought of as a diagnostic possibility, considering the epidemiology of our region and its proximity to the southern states of the United States.

## CASE REPORT

A 24-year-old male patient referred at the Emergency Department with dysphagia and dysphonia. As a history of importance, the patient presented chronic kidney disease in treatment with peritoneal dialysis, erythropoietin and prednisone, with a renal transplant in 2017 and rejection in 2019; secondary arterial hypertension with treatment based on Nifedipine, Telmisartan and Prazosin, in addition to anxiety disorder and depression in treatment with Amitriptyline.

The presenting symptoms started 1 year prior to our consultation, with slowly progressive dysphonia, which reached aphonia with excessive use of the voice, related to the infectious picture of the upper respiratory tract, apparently viral. 1 month prior, dysphonia was exacerbated and accompanied by dysphagia to solids, with poor tolerance to soft and liquid diet, for which he presented to the emergency department. An interconsultation was performed in our department for assessment and management.

*Physical Examination:* A calm, cooperative patient was observed, oriented in his three neurological spheres, skin and integuments with slight pallor.

*Videolaryngoscopy with 70° lens* revealed prominent tongue base, significant edema in the glossoepiglottic folds, epiglottis with highly edematous mucosa, arytenoids with abundant redundant and edematous mucosa; no ulcers or bleeding sites were observed; an apparent pink tumor was seen at the level of the arytenoid cartilage in the right posterolateral region, a rest of non-assessable structures, non-assessable glottic lumen (see Figure 2).

A chest tele-x-ray was performed, showing a nodular reticulatum pattern (see Figure 3).

The contrast-enhanced tomography of the neck (Figure 4) revealed an obstruction of more than 90% of the glottic lumen, without uptake of the contrast material in the coronal plane, a round pedicled lesion in the axial section; at the level of the epiglottis, thickening with irregular edges was observed.

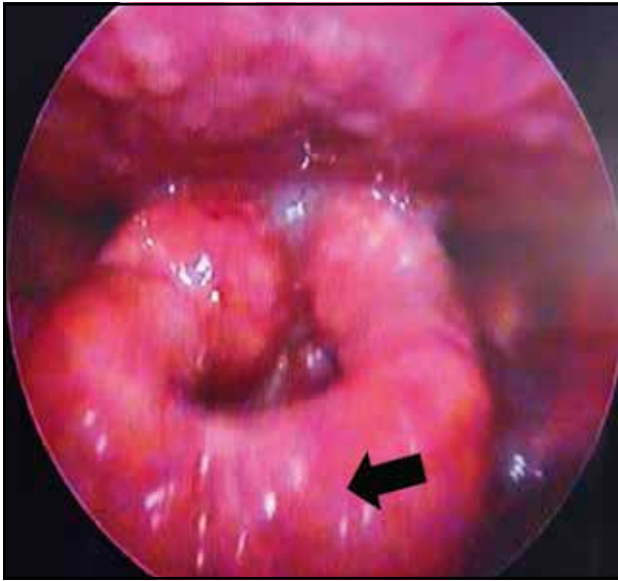
He was admitted for the direct laryngoscopy procedure and biopsy. He underwent direct laryngoscopy under general anaesthesia. His hospital stay was stable, he was discharged the following day and made an appointment to see the results 2 weeks later, with a pathology study report.

The histopathological study report indicated that under 10X100 vision of the laryngeal mucosa stained with hematoxylin and eosin, a spherule with endospores inside was observed, in addition to mononuclear infiltration, with macrophages forming multinucleated giant cells or

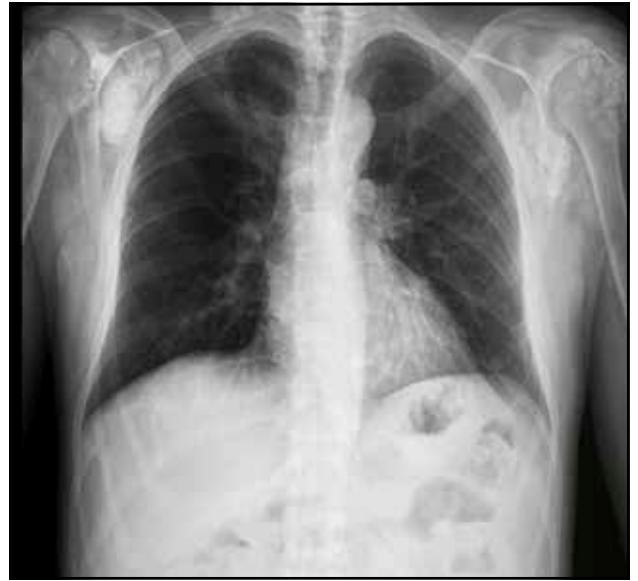Table 1. Summary of selected papers on laryngeal Coccidioidomycosis in adults.

Article	State/Country	Case no.	Age	Gender	Clinical features	Histopathological description	Treatment
Mumma <sup>2</sup> , 1953	Los Angeles, California, US	1	37 years	Male	<ul style="list-style-type: none"> <li>• Symptoms: pharyngodynia (4-5-month evolution), dysphagia, gradual dysphonia, 4.1 kg weight loss in 4 months.</li> <li>• Epiglottitis – invaded by a granulomatous lesion with no evidence of superficial ulceration.</li> <li>• Ten sputum test – negative for Mycobacterium tuberculosis</li> <li>• Chest x-Ray – normal</li> <li>• Tests with coccidioidin elicited a positive reaction 1+.</li> <li>• The complement fixation reaction for coccidioidomycosis was positive</li> </ul>	Coccidioides immitis spherules	Iodine and irradiation without improvement
Singh et al. <sup>17</sup> , 1956	Chicago, Illinois, US	1	34 years	Male	<ul style="list-style-type: none"> <li>• Symptoms: moderately productive cough of three-month duration, dysphonia and dysphagia of one-month duration; granulomatous skin lesion on the back of the nose.</li> <li>• Chest X-ray – multiple and small pulmonary radiopacities of calcium density.</li> <li>• Direct laryngoscopy – extensive granuloma fungoides affecting the oral vestibule and endolarynx; the epiglottis was thickened, with the presence of an ulcer, with considerable edema of both arytenoid cartilage and aryepiglottic folds, with distortion of the normal contour; a pale white granuloma that extended to both ventricles; the glottic lumen was slit shaped and was fixed almost entirely by the tumor mass.</li> </ul>	Trachea tissue biopsy: Spherules filled with Coccidioides immitis endospores and granulomatous tissue	150 mg. intravenous injection with dihydroxystilbamidine four times daily (total of 20 doses)
Platt <sup>18</sup> , 1977	Tucson, Arizona, US	1	45 years	Male	<ul style="list-style-type: none"> <li>• Symptoms: fever, malaise, haemoptysis, weight loss of 14 kg, dyspnea, headache, dysphonia.</li> <li>• Repeated sputum cultures – negative for mycobacteria and fungi.</li> <li>• Chest X-ray – notable bilateral irregular infiltrates with cavitations.</li> <li>• Laryngoscopy – irregular area of granulomatous appearance involving the vocal cords and limiting their movement.</li> </ul>	Laryngeal tissue biopsy: pseudoepithelial hyperplasia, giant cells, inflammatory cells, spherules of Coccidioides immitis	For two years he was treated with amphotericin B, sputum studies remained positive for C. immitis, so he was switched to miconazole nitrate; ten weeks later the laryngoscopy showed cleaning of the vocal cords
Henley-Cohn et al. <sup>13</sup> , 1979	San Francisco California, US	3 adults and 1 child	75 years	Male	<ul style="list-style-type: none"> <li>• Symptoms: pain and deep neck abscess in the retropharyngeal space, dysphagia, dyspnea, voice changes.</li> <li>• Coccidioidin negative in the skin.</li> <li>• The complement fixation reaction for coccidioidomycosis was positive.</li> </ul>	Spherules of Coccidioides immitis	Amphotericin B, presenting involution of the retropharyngeal mass
			37 years	Male	Disseminated coccidioidomycosis, in the axial skeleton, cervical region (including spinal cord), sternum, clavicle and pelvis, presenting fever, pulmonary involvement, mediastinum, fracture and osteomyelitis from the fourth to the sixth cervical vertebra.	Biopsy of abscess tissue: Coccidioides immitis spherules	Miconazole, at two weeks presented signs of resistance, it was changed to amphotericin B. The patient presented toxicity data and died from cardiac damage.
			55 years	Male	<ul style="list-style-type: none"> <li>• Symptoms: Pain to cervical mobility, dysphagia time of evolution</li> <li>• Physical examination revealed a retropharyngeal mass.</li> <li>• Cervical X-ray – lytic lesion in the body of C3.</li> <li>• Coccidioidin positive in the skin.</li> </ul>	Biopsy of abscess tissue: Coccidioides immitis spherules	Management was started with amphotericin B, with clear improvement of the initial picture.

Boyle et al. <sup>16</sup> , 1991	Tucson, Arizona, US	1	40 years	Female	<ul style="list-style-type: none"> <li>• Symptoms: hoarseness, cervical adenopathy, fever, dry cough and fatigue for 6 months; bilateral neck soft lymphadenopathy, particularly a 2 cm ganglion in the right middle jugular lymph node region.</li> <li>• The larynx revealed a mucosa with marked erythema and edema, without focal lesions. The airway was moderately compromised, the chordal function was normal.</li> <li>• Chest X-ray – normal</li> <li>• Coccidioidin negative in the skin.</li> </ul>	<p>Cervical adenopathy biopsy: non-caseous granulomatosis.</p> <p>Excisional biopsy of the right perijugular nodes: hypertrophic lymph node, with caseating granulomas containing multinucleated giant cells and double-walled spherules with <i>Coccidioides immitis</i> endospores.</p>	<p>Tracheostomy to secure the airway.</p> <p>The patient was placed on an experimental treatment protocol with fluconazole, with great improvement after 7 days of treatment</p>
Allen et al. <sup>7</sup> , 2011	Sacramento, California, US	1	52 years	Female	<ul style="list-style-type: none"> <li>• Symptoms: non-progressive dysphonia and cough of 1 year of evolution. With personal pathological history of pulmonary coccidioidomycosis diagnosed 23 years before (1984) and treated with antifungals until 1998. Immobile left vocal cord in paramedial position. No abnormalities were observed in the mucosa, a vocal cord medialization procedure with hydroxyapatite was performed.</li> <li>• 3 weeks later – dysphagia, odynophagia, weight loss.</li> <li>• Videolaryngoscopy – severe erythema, edema and pseudomembranous exudate affecting the epiglottis, aryepiglottic folds and pyriform sinuses.</li> <li>• Chest CT scan – large pneumatoceles and bilateral lung damage.</li> </ul>	<p>Biopsy of both vocal cords and arytenoid area: <i>Coccidioides immitis</i>.</p>	<p>Oral Fluconazole 400 mg twice daily.</p> <p>A good response was seen.</p>
Antony, <sup>8</sup> 2015	El Paso, Texas, US	1	59 years	Female	<ul style="list-style-type: none"> <li>• Symptoms: hoarseness, sore throat, fever of 2 to 3 months of evolution, for which management was provided with quinolones, without clinical improvement.</li> <li>• Laryngoscopy – soft tissue mass just above the vocal cords on the left side.</li> <li>• No cervical lymphadenopathy.</li> <li>• Chest X-ray – normal.</li> <li>• Chest CT scan – two pulmonary nodules in the upper segment of the left lower lobe.</li> <li>• The complement fixation titer of <i>C. immitis</i> was negative.</li> <li>• Fungal cultures were consistent with <i>Coccidioides immitis</i>.</li> </ul>	<p>Laryngeal lesion biopsy: spherules with endospores, accompanying granulomas</p>	<p>Fluconazole 400 mg per day for 6 months with improvement at the 3-month follow-up</p>
Convers et al. <sup>19</sup> , 2020	Colton, California, US	1	52 years	Male	<ul style="list-style-type: none"> <li>• Symptoms: sore throat, odynophagia, productive cough (clear-white, blood-tinged sputum), weight loss in the previous three months, vomiting, polydipsia and polyuria.</li> <li>• Chest X-ray – diffuse bilateral reticulonodular opacities with a possible lingular cavity lesion.</li> <li>• Thoracic CT scan without contrast – numerous, bilateral nodular densities, especially in the upper lobes; lingular cavity lesion.</li> <li>• Three sputum samples – negative for acid-fast bacilli.</li> <li>• Bronchoscopy – lesions with irregular edges in the ventricular bands, vocal cords with erythema and edema and two polyps, inflammation in the subglottic space, and several bilaterally pink endobronchial lesions.</li> <li>• <i>Coccidioides</i> complement fixation with strongly positive results.</li> <li>• Culture revealed <i>Coccidioides immitis</i>.</li> </ul>	<p>Bronchial lavage: predominance of neutrophils with spherules and endospores, consistent with <i>Coccidioides immitis</i> or <i>Rhinosporidium seberi</i>.</p>	<p>Itraconazole every three months with improvement after two weeks of treatment</p>



**Figure 2.** Laryngoscopy shows granulomatous lesions of the supraglottis involving epiglottis (see black arrow), ventricular bands, false and true cords, causing an obstruction of 80% of the glottic lumen.



**Figure 3.** Chest X-ray shows a nodular reticulum pattern predominantly for the bilateral hilar regions, the central trachea; preserved cardiac silhouette.

Langerhans cells (Figure 5). The aspect was significant for coccidioidomycosis.

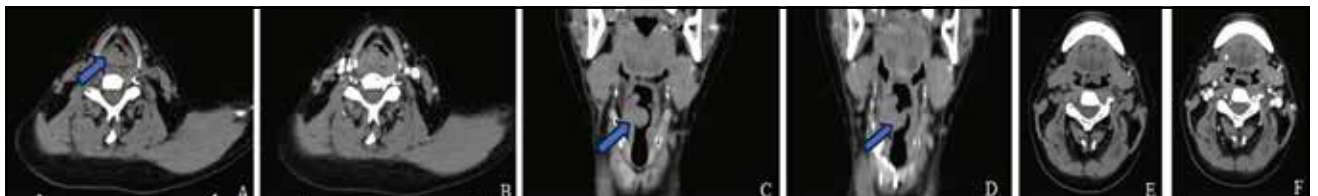Upon re-evaluation with the histopathological results, it was decided to admit the patient in the internal medicine department responsible for infectious diseases and a joint management with nephrology. However, days after admission and after being subjected to haemodialysis, he presented electrolyte abnormalities, causing the patient's death without having started antimicrobial management.

## DISCUSSIONS

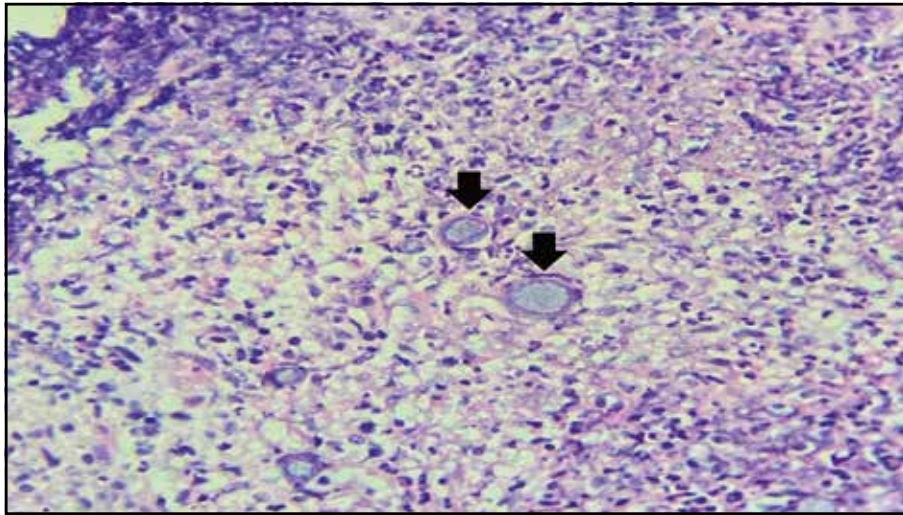
Although tuberculosis has been considered as the great simulator, when it comes to clinical manifestations, there are infections such as coccidioidomycosis with a similar behaviour<sup>20</sup>. Like tuberculosis, coccidioidomycosis represents an infection that, in addition to being similar due to the granulomatous lesions that they form, from the histopathological point of view, shows a variety of presentations that would be

“worthy” of being considered, as in our case and the few cases that have been reported in the literature<sup>14,19,21</sup>. On the other hand, it has been estimated that more than 50% of coccidioidomycosis cases are asymptomatic or with mild and self-limited symptoms<sup>19</sup>. The clinical presentation in coccidioidomycosis is very nonspecific, such as a picture that begins with fever, headache, fatigue, coryza and malaise and at the pulmonary level may present cough and pleuritic or dull chest pain<sup>21</sup>. For this reason, the vast majority of patients are treated with antibiotics for suspected bacterial pneumonia before making a more accurate diagnosis<sup>19</sup>. They may also have immune-mediated extrapulmonary manifestations, such as mono or oligoarthritis, especially of the knee, erythema nodosum, and erythema multiforme<sup>7</sup>. The manifestations in our patient were with involvement of the upper respiratory tract, with dysphonia of long evolution, dyspnea and difficulty swallowing, and the case was approached as a possibly malignant lesion.

Macroscopically, due to its granulomatous nature, tissue infected by *Coccidioides* can be mistaken for a florid car-



**Figure 4.** Simple and contrasted tomography of the neck: A. axial section at the level of the thyroid cartilage – obstruction of more than 90% of the glottic space (see blue arrow); B. it is observed that, when applying contrast medium, there is no capture; C. coronal plane – round pedunculated lesion (see blue arrow), with density similar to soft tissues, irregular (see blue arrow), located in the supraglottic region and posterior wall; D. without data of contrast medium uptake; E. and F. axial slice tomography at the level of epiglottis – thickened with irregular edges. In image F, no reinforcement to the contracting medium is observed.



**Figure 5.** Histopathological study-spherules with endospores inside are observed in the central image (see black arrow), in addition to necrosis and infiltration by polymorphonuclear cells (hematoxylin and eosin staining, 40X)

cinoma of the larynx<sup>14</sup>. Histologically, a mixed granulomatous and suppurative process is present. Mononuclear infiltration is observed when macrophages phagocytize spherules and giant Langerhans cells before the foreign body form granulomas<sup>15</sup>.

Among various risk factors, pregnancy and race have been indicated. An increase in prevalence has been reported in Mexicans, Filipinos and blacks as racial subgroups<sup>15</sup> and in solid organ transplant patients<sup>3</sup>. Our patient presented a history of renal transplantation (performed in 2017 and rejected in 2019), at the moment of diagnosis being diagnosed with chronic kidney disease in treatment with peritoneal dialysis, erythropoietin and prednisone.

It is noted that patients with a *Coccidioides* laryngeal infection often present with a threatened airway. Approximately 50% of them need immediate airway intervention, either tracheostomy or intubation<sup>16</sup>. Apparently, the presentation of laryngeal involvement in adults is even rarer than in pediatric cases, considered so by the low volume of reports in this age group<sup>6</sup>.

We consider that, in our case, having undergone the transplant procedure and the use of immunosuppression drugs that this event entails, together with an endemic area of coccidioidomycosis, were the favouring elements for the presentation of this disease. Rosen et al.<sup>22</sup> described a case of laryngeal coccidioidomycosis in a 14-year-old kidney recipient, similar to ours, but of pediatric age.

## CONCLUSIONS

Laryngeal coccidioidomycosis represents a diagnostic challenge for the clinician, given its characteristics and manifestations. This condition can affect the airway, presenting initially as a potential malignancy before manifesting as an

infectious process with abscess formation and even involving bone destruction.

The area in which we are geographically makes it necessary to always include coccidioidomycosis as an entity to be ruled out in our patients.

**Financial disclosure:** There are no financial disclosures of the authors.

**Conflicts of interest:** The authors declare that they have no conflict of interest.

**Contribution of authors:** All authors contributed equally to the writing of the article.

**Sources of funding:** This work was funded entirely by the authors and did not receive any type of payment.

**Acknowledgements:** I want to thank widely and strongly the most capable woman in the scientific and academic field to Miss Dr. Alexandra Elbakyan who, thanks to her creation Sci-Hub, was able to access the articles of the cases cited there; without those facilities, this writing would not have been conceived as a review.

### Authors' information:

Carolina Verde Lizárraga, Resident physician, Otorhinolaryngology Service, "Luis Donaldo Colosio Murrieta" Specialties Hospital No. 2, Mexican Institute of Social Security, Ciudad Obregon, Sonora, Mexico. E-mail: carolinavlga@hotmail.com. ORCID: <https://orcid.org/0000-0001-7958-3445>.

Karen Alejandra Leal Tapia, Medical Pathologist, Pathological Anatomy Service of the Regional General Hospital No. 1, Mexican Institute of Social Security, Ciudad Obregon, Sonora, Mexico. E-mail: karenale\_29@hotmail.com. ORCID: <https://orcid.org/0000-0002-6087-0935>.

Juan Antonio Lugo-Machado, MD, Otorhinolaryngology Service, "Luis Donaldo Colosio Murrieta" Specialties

Hospital No. 2, Mexican Institute of Social Security, Ciudad Obregon, Sonora, Mexico. E-mail: otorrinox@gmail.com. ORCID: <https://orcid.org/0000-0003-4864-8546>.

José Roberto Reina Loaiza, Medical Pathologist, Pathological Anatomy Service of the Regional General Hospital No. 1, Mexican Institute of Social Security, Ciudad Obregon, Sonora, Mexico. E-mail: joseroberto1@gmail.com. ORCID: <https://orcid.org/0000-0002-8615-4072>.

## REFERENCES

1. Stewart ER, Thompson GR. Update on the epidemiology of coccidioidomycosis. *Curr Fungal Inf Rep*. 2016;10:141-6. DOI: 10.1007/s12281-016-0266-1.
2. Dickson EC. "Valley Fever" Of The San Joaquin Valley And Fungus *Coccidioides Cal West Med*. 1937;47(3):151-55.
3. Colombo AL, Tobon A, Restrepo A, Queiroz-Telles F, Nucci M. Epidemiology of endemic systemic fungal infections in Latin America. *Med Mycol*. 2011;49(8):785-98. DOI: 10.3109/13693786.2011.577821.
4. Gonzalez A, Gonzalez Mendoza A. Micosis en Mexico. *Salud Públ Méx*. 1959;1(2):103-15.
5. Barker BM. The changing epidemiology and diagnosis of Valley Fever. *Clin Microbiol Newsl*. 2017;39(20):159-64. DOI: 10.1016/j.clinmicnews.2017.09.007.
6. Antony N. Isolated laryngeal Coccidioidomycosis - a case report and review of the literature. *J Immunol Infect Dis*. 2015;1(2):101. DOI: 10.15744/2394-6512.1.201.
7. Allen JE, Belafsky PC. Laryngeal coccidioidomycosis with vocal fold paralysis. *Ear Nose Throat J*. 2011;90(5):E1-5. DOI: 10.1177/014556131109000510.
8. Antony SJ, Dummer SJ, McNeil KK, Salas I. Coccidioidomycosis in renal transplant recipients. *Infect Dis Clin Pract*. 2005;13(5):250-4. DOI: 10.1097/01.idc.0000179883.64882.41.
9. Kahn A, Carey EJ, Blair JE. Universal fungal prophylaxis and risk of coccidioidomycosis in liver transplant recipients living in an endemic area. *Liver Transpl*. 2015;21(3):353-61. DOI: 10.1002/lt.24055.
10. Batsakis JG. Pathology consultation. Coccidioidomycosis of the larynx. *Ann Otol Rhinol Laryngol*. 1984;93(5 Pt 1):528-9. DOI: 10.1177/000348948409300523.
11. Naeem F, McCarty J, Mhaisen MN, Ha S, Rongkavilit C. Extrapulmonary coccidioidomycosis among children in central california: a retrospective review. *Pediatr Infect Dis J*. 2019;38(12):1189-94. DOI: 10.1097/INF.0000000000002470.
12. Mumma CS. Coccidioidomycosis of the epiglottis. *AMA Arch Otolaryngol*. 1953;58(3):306-9.
13. Henley-Cohn J, Boles R, Weisberger E, Ballantyne J. Upper airway obstruction due to coccidioidomycosis. *Laryngoscope*. 1979;89(3):355-60. DOI: 10.1288/00005537-197903000-00002.
14. Copeland B, White D, Buenting J. Coccidioidomycosis of the head and neck. *Ann Otol Rhinol Laryngol*. 2003;112(1):98-101. DOI: 10.1177/000348940311200118.
15. Ward PH, Berci G, Morledge D, Schwartz H. Coccidioidomycosis of the larynx in infants and adults. *Ann Otol Rhinol Laryngol*. 1977;86(5 Pt 1):655-60. DOI: 10.1177/000348947708600521.
16. Boyle JO, Coulthard SW, Mandel RM. Laryngeal involvement in disseminated coccidioidomycosis. *Arch Otolaryngol Neck Surg*. 1991;117(4):433-8. DOI: 10.1001/archotol.1991.01870160087016.
17. Singh H, Yast CJ, Gladney JH. Coccidioidomycosis with endolaryngeal involvement. *AMA Arch Otolaryngol*. 1956;63(3):244-7. DOI: 10.1001/archotol.1956.03830090016003.
18. Platt MA. Laryngeal coccidioidomycosis. *JAMA*. 1977;237(12):1234-5.
19. Converse C, Dey A, Decker S, Arabian S, Neeki M. Coccidioidomycosis of the vocal cords presenting in sepsis: a case report and literature review. *Case Rep Crit Care*. 2020;2020:8025391. DOI: 10.1155/2020/8025391.
20. Maldonado R, Faugier E, Flores A, Lara PB. Tuberculosis the great simulator, really is lupus? A clinical case report. *Pediatr Rheumatol Online J*. 2014;12(Suppl 1):P337. DOI: 10.1186/1546-0096-12-S1-P337.
21. Crum NF. Coccidioidomycosis: a contemporary review. *Infect Dis Ther*. 2022;11(20):713-42. DOI: 10.1007/s40121-022-00606-y.
22. Rosen EJ, Newlands SD, Patel J, Kalia A, Friedman NR. Reactivated laryngeal coccidioidomycosis. *Otolaryngol Head Neck Surg*. 2001;125(1):120-1. DOI: 10.1067/mhn.2001.116785.

© 2023 Carolina Verde Lizárraga, José Roberto Reina Loaiza, Karen Alejandra Leal Tapia, Juan Antonio Lugo Machado, published by Romanian Rhinologic Society



This is an open access article published under the terms and conditions of the Creative Commons Attribution-NonCommercial-NoDerivatives 4.0 International (CC BY-NC-ND 4.0) License (<https://creativecommons.org/licenses/by-nc-nd/4.0/>). CC BY-NC-ND 4.0 license requires that reusers give credit to the creator by citing or quoting the original work. It allows reusers to copy, share, read, download, print, redistribute the material in any medium or format, or to link to the full texts of the articles, for non-commercial purposes only. If others remix, adapt, or build upon the material, they may not distribute the modified material.