

ORIGINAL STUDY

Anterior palatoplasty as a treatment for mild and moderate obstructive sleep apnea: our experience

Ionut Tanase^{1,2,3} , Shirley Tarabichi^{1,2} 

¹“Carol Davila” University of Medicine and Pharmacy, Bucharest, Romania

²ENT&HNS Department, “Sfanta Maria” Hospital, Bucharest, Romania

³CESITO Center, “Sfanta Maria” Hospital, Bucharest, Romania

ABSTRACT

BACKGROUND. Obstructive sleep apnea (OSA) is characterized by frequent episodes of breathing cessation during sleep, resulting in low oxygen and high carbon dioxide levels, leading to daytime sleepiness, cognitive issues, and increased cardiovascular risk. The objective of this study was to assess the effectiveness of the anterior palatoplasty (AP) procedure in the treatment of patients with mild and moderate obstructive sleep apnea.

MATERIAL AND METHODS. Sixteen patients diagnosed with mild and moderate OSA underwent AP in our clinic between 2021-2023. All patients were > 18 years old, body mass index < 30, with an apnea-hypopnea index (AHI) from 10 to 40 and dysfunction of the velopharyngeal or of the retropalatal space. Patients underwent a one-night polysomnography examination prior to the surgical procedure, as well as six months after the procedure. Additionally, patients were asked to complete the Epworth Sleepiness Scale (ESS) both prior to and six months following the surgery. The procedure was done under general anaesthesia and involved AP surgery with or without reducing of the uvula.

RESULTS. The average of total AHI values decreased from 28.89 per hour prior to surgery to 11.14 per hour six months after surgery. The oxygen desaturation index decreased after surgery with 2.57%. ESS scores of patients also decreased from 10.40 to 7.80 and all patients felt less tired.

CONCLUSION. We believe that AP is an effective technique in the treatment of mild and moderate OSA caused by a dysfunction of the velopharyngeal or retropalatal space. Additionally, we consider that AP is linked with a lower incidence of post-surgical complications compared to other surgical options.

KEYWORDS: anterior palatoplasty, obstructive sleep apnea, apnea hypopnea index, Epworth Sleepiness Scale, polysomnography.

INTRODUCTION

Obstructive sleep apnea (OSA) is a condition that is quite common and complex. It is characterized by recurrent and intermittent pauses in breathing during sleep. This results in decreased oxygen levels and increased carbon dioxide in the blood, leading to neurocognitive dysfunction, daytime drowsiness, diminished quality of life, and a heightened risk of developing or worsening cardiovascular diseases¹⁻³.

In a study by Young et al. involving 602 patients who underwent monitored overnight polysomnography, it was observed that OSA was present in 24% of males and

9% of females, but it is well known that the majority of the patients remain undiagnosed⁴.

OSA occurs due to the upper airway's tendency to collapse during sleep. This collapse can be triggered by negative pressure acting on the soft tissues of the upper airway, potentially causing complete or partial blockage that interrupts breathing⁵. The most frequent site of collapse in patients with OSA is the retropalatal space⁶. As a result, the majority of surgical interventions designed to address OSA focus on inducing scar formation in the palate, leading to fibrosis and consequent stiffening of the palate. This stiffening process aims to inhibit the palate from vibrating or collapsing^{7,8}.

Corresponding author: Ionut Tanase, MD, PhD, Assistant Professor, “Carol Davila” University of Medicine and Pharmacy, ENT&HNS Department, CESITO Center, “Sfanta Maria” Hospital, Bucharest, Romania, **Address:** 37-39 Ion Mihalache Blvd., District 1, Bucharest, Romania

ORCID: <https://orcid.org/0000-0003-4475-7737>

e-mail: ionut.tanase@medicover.ro

Received for publication: January 26, 2024 / **Accepted:** February 29, 2024

Uvulopalatopharyngoplasty (UPPP), originally introduced by Fujita et al.⁹ in 1981, was the surgery most frequently utilized to treat OSA. Nevertheless, the failure rates for UPPP are quite variable, ranging from 30% to 90%. These failures are often attributed to incorrect identification of the obstruction site in the upper airway or inadequate methods of patient selection. Due to these challenges, surgeons have been motivated to innovate new surgical techniques targeting the velopharyngeal area, leading to the development of various surgical approaches for the reconstruction of the palate^{10,11}.

In 1994, Ellis et al.¹² introduced the concept of anterior palatal stiffening surgery, which involves removing a tiny portion of mucosa from the uvula and palate. Subsequently, Mair et al.¹³ further developed this technique, resulting in the cautery-assisted palatal stiffening surgery (CAPSO). Pang et al.¹⁴ improved the CAPSO approach, leading to positive results for patients suffering from snoring and moderate OSA. In 2009, the CAPSO procedure became known as anterior palatoplasty, as it involves the anterior surface of the soft palate rather than being a modification of the CAPSO technique¹⁵.

The literature data indicates that many studies assessing the outcomes of anterior palatoplasty note a reduction of over 50% in the postoperative apnea-hypopnea index (AHI) scores and a notable increase in the minimum oxygen saturation levels¹⁶.

In this study, we aimed to evaluate the effectiveness of anterior palatoplasty procedure in the management of the patients with mild and moderate OSA, by analyzing the outcomes before and after the procedure through both objective (polysomnography) and subjective (Epworth Sleepiness Scale (ESS)) evaluations.

MATERIAL AND METHODS

Study protocol

This study included sixteen patients suffering from mild and moderate OSA. Patients were selected from those attending the outpatient clinic of the ENT Department of “Sfanta Maria” Clinical Hospital, from 2021 until 2023. We received approval from the Ethical Council of the Hospital and all patients signed a consent before taking part in the study. For the management of OSA, anterior palatoplasty (AP) surgery was performed on all our patients who were included in the study.

Patients included in the study had to meet the following inclusion criteria: 18-year-old patients or older, with a body mass index (BMI) below 30 and who were diagnosed with mild and moderate obstructive sleep apnea, which is characterized by an apnea-hypopnea index of more than 10 but less than 40. Another inclusion criteria was represented by the presence of a disfunction of the velopharyngeal or of the retropalatal space.

The exclusion criteria for the study encompassed patients below the age of 18, those with a body mass index exceeding 30, and patients suffering from severe obstructive sleep apnea with an apnea-hypopnea index above 40. Additionally, it ruled out patients with unmanaged hypothyroidism, diabetes mellitus, or any chronic illness, as well as those presenting with pronounced deformities of the upper or lower jaw.

All patients included in the study underwent a comprehensive evaluation process that included clinical assessment and physical assessment (general examination, complete ENT examination and flexible nasopharyngoscopy).

Patients were evaluated with one night polysomnography and completed also ESS before the surgery.

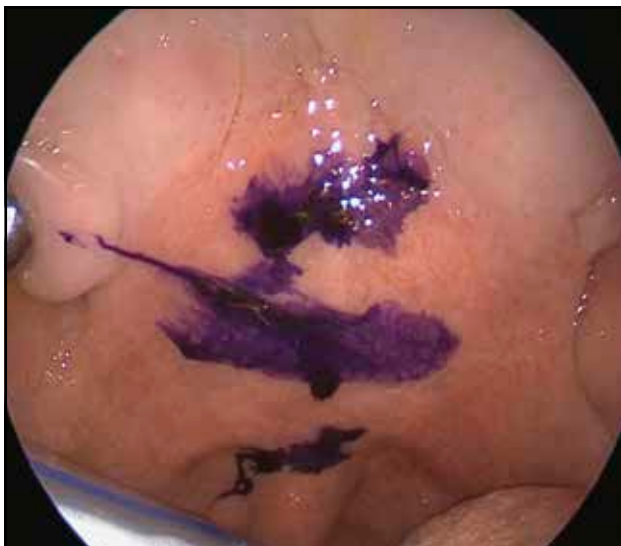

Figure 1. Anterior palatoplasty intraoperative picture – palatine veil marked.

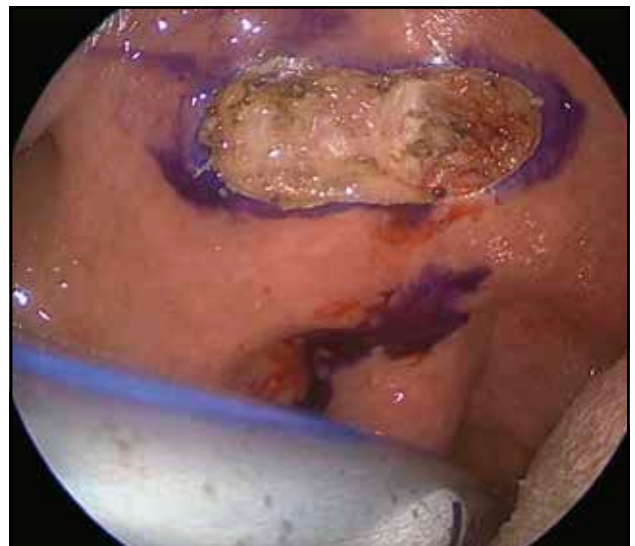

Figure 2. Horizontal rectangular strip of mucosa was removed – intraoperative view.

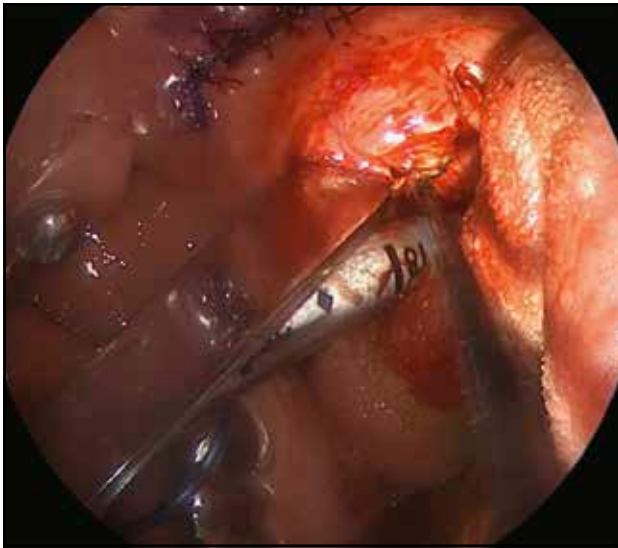


Figure 3. Reducing of the uvula and suture of the stripped area.

Surgical technique

We performed the anterior palatoplasty surgery under general anaesthesia with nasotracheal intubation to have a better visual field. But it can also be done as an office-based procedure under local anaesthesia.

We marked the boundary at the hard palate level and established the caudal boundary at the uvula's root. Additionally, a third demarcation was made, equidistant between the two prior marks, effectively dividing the soft palate into three equal segments. The central third of the palatine veil was then marked for surgery (Figure 1).

The designated area for surgery is rectangular, with dimensions ranging from 0.8cm to 1cm in width and 2 cm to 2.5 cm in length. With a Radiofrequency electrode, the rectangular strip of the mucosa of the above-mentioned territory was removed, respecting the established limits (Figure 2). The deep limit is represented by the muscular plane (palato-pharyngeal muscle, tensor muscle of the palatine veil and palatoglossal muscle). The area from where the mucosa was removed was then sutured, in order to reposition the soft palate both anteriorly and superiorly. We also vaporized the posterior tonsillar pillars to obtain a wider oropharyngeal isthmus and to avoid tensioning the sutures at the level of the palatal wave. In some cases, when it was necessary, the procedure was associated also with reduction of the uvula (Figure 3).

The final result of the surgery – AP and uvula reduction associated with the posterior tonsillar pillars vaporization – is illustrated in the Figure 4.

After surgery, pain control was managed by giving local anaesthetic lozenges and systemic non-steroidal anti-inflammatory drugs for 5 days to all the patients. Oral antibiotics agents were generally recommended following surgery to prevent the infection.

Also, all patients were advised to follow a diet of

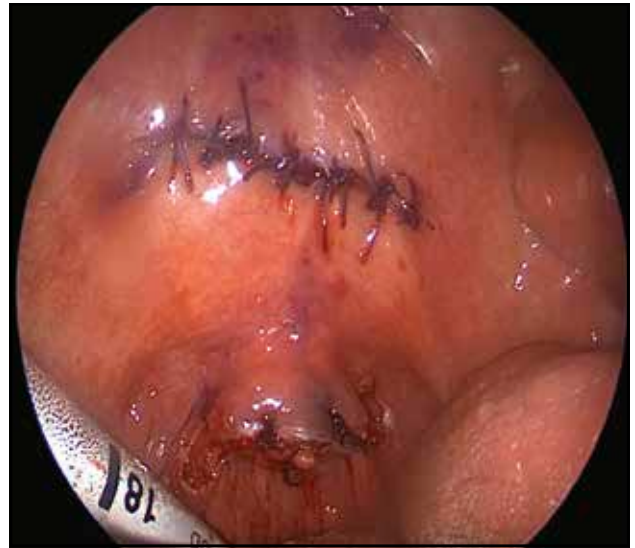

Figure 4. Final view of anterior palatoplasty, uvula reduction and posterior tonsillar pillars vaporization (intraoperative view).

soft, blended foods during the first week following the procedure.

The follow-up period was up to six months, and consisted of a series of evaluations including ESS and polysomnography.

No complications such as palatine veil necrosis or velar insufficiency with reflux of food into the nasal cavity were encountered (Figure 5).

The study's outcome measures utilized subjective and objective methods to evaluate improvement. Subjective improvement in daytime sleepiness was quantified using the ESS. Objectively, the efficacy of the AP was evaluated by analyzing the changes in the polysomnographic data. This objective data was instrumental in assessing the physiological improvements in sleep patterns and breathing, offering a scientific basis to deter-

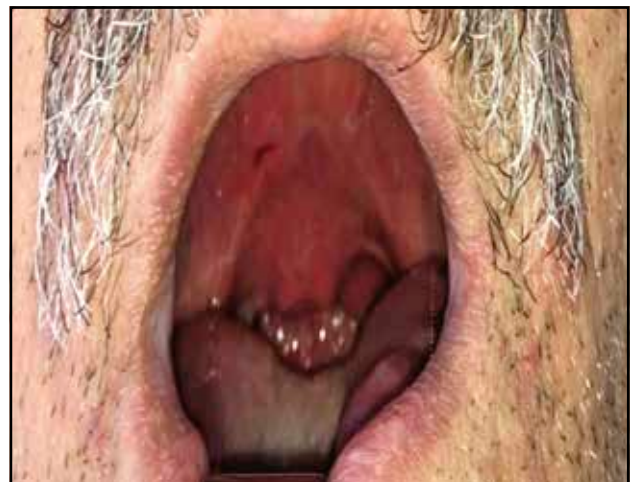

Figure 5. Postoperative aspect at 3 weeks after surgery (anterior palatoplasty and reduction of the uvula).

Table 1. Study population data.

Number of patients	16
Age	40.4 years (21-58 years)
BMI	25.7 kg/m ² (20.7 – 28.8 kg/m ²)
AHI	28.89/h (38/h – 19/h)

mine the success of the AP.

Data analysis was centralized and analyzed using SPSS software for macOS by determining the mean and standard deviation. It was established that the results were statistically significant at a confidence level of 95%, which corresponds to a $p < 0.05$.

RESULTS

The group consisted of 11 males and 5 females, with an average age of 40.4 years (ranging from 21 to 58 years), and an average BMI of 25.7 kg/m² (range 20.7-28.8 kg/m²) (Table 1).

In all patients included in the study, there was a notable decrease in the frequency of obstructive sleep apneas six months following surgery, leading to an improved postoperative condition. Statistically significant differences ($p < 0.01$) were registered comparing the preoperative and postoperative AHI. Starting from an average preoperative AHI value of 28.89/h (moderate obstructive sleep apnea), we obtained, 6 months postoperatively, an average residual AHI of 11.14/h, which corresponds to a mild obstructive apnea. The postoperative AHI decrease was of 61.43% when compared to the initial mean values (Table 2).

The decrease in the maximum duration of obstructive respiratory events during sleep was also statistically significant at 6 months after surgery. A decrease of 6.37 seconds

Table 2. Pre- and postoperative AHI results in patients with anterior palatoplasty.

Number of patients	16
Preoperative AHI (mean)	28.89 events/h
Postoperative AHI (mean)	11.14 events/h
P value	<0.01
Reduction of AHI (%)	61.43%

was observed postoperatively, from 34.25 seconds to 27.88 seconds ($p < 0.025$) (Table 3).

In terms of snoring events, a postoperative reduction to 133.05 events from 204.23 events preoperatively was observed following the anterior palatoplasty procedure ($p < 0.025$) (Table 3). In each patient, there was a noticeable reduction in the snoring they were experiencing, and the patients and their sleep partners were pleased with the results.

When evaluating the oxygen saturation (SpO₂) status in our study group, we observed an improvement of 2.57% in the lowest oxygen saturation values after surgery, compared with the levels registered before surgery ($p < 0.025$) (Table 3). Preoperatively, the average of the lowest oxygen saturation was 80.68% and after surgery it increased to 83.25%.

Furthermore, after undergoing anterior palatoplasty, there was a decrease of 2.60 points on the ESS (from 10.40 to 7.80), indicating an improvement in daytime sleepiness ($p < 0.01$).

Despite recommendations for weight management, there were no significant differences in pre-operative and post-operative weights and no substantial reductions in BMI were observed in any of the patients included in the present study.

Table 3. The average results of the study summarized.

Parameters	Preoperative values	Postoperative values	P value
AHI	28.89/h	11.14/h	<0.01
Oxygen saturation (lowest SpO ₂ values)	80.68%	83.25%	<0.025
Snoring	204.23 events	133.05 events	<0.025
Maximum duration of obstructive respiratory events	34.25 seconds	27.88 seconds	<0.025
ESS (points)	10.40	7.80	<0.01

It was noticed that none of the patients experienced post-operative bleeding after the surgery.

The patients who underwent reducing of the uvula in addition to the anterior palatoplasty reported more intense pain, indicating that the uvulectomy was likely the main source of discomfort rather than the palatoplasty.

None of the patients experienced a postoperative increase in their AHI, implying no worsening of their sleep apnea condition.

DISCUSSIONS

Obstructive sleep apnea is characterized by repeated incidents of partial or full blockage of the airway during sleep. These frequent instances of oxygen deprivation and interrupted sleep result in a range of negative health outcomes. Disrupted sleep can lead to poor sleep quality, excessive daytime drowsiness, a decrease in alertness, brief unintended periods of sleep, and impaired brain function. Given the detrimental impact on cognitive functions, it is theorized that OSA could negatively influence the patient lifestyle^{17,18}.

The retropalatal space is frequently implicated as the primary area of concern in OSA. In patients suffering from OSA, this area tends to be particularly prone to collapse during sleep, leading to the obstruction of airflow. Consequently, a significant number of surgical techniques developed to treat obstructive sleep apnea are centered on modifying the structural integrity of the palate. These procedures aim to initiate the formation of scar tissue, which progresses to fibrosis, thereby increasing the rigidity of the soft palate^{6,8}.

Uvulopalatopharyngoplasty (UPPP) is a surgical technique intended to correct the upper airway narrowing at the level of the soft palate¹⁹. While UPPP can alleviate the narrowing in the upper airway, it is associated with long-term morbidities such as globus sensation, nasal regurgitation, difficulty in swallowing and velopharyngeal insufficiency^{20,21}.

These complications arise from the post-surgical exposure of the pharyngeal muscles and nervous tissues, which can lead to various issues following the surgery like postoperative haemorrhage and great pain^{9,22,23}.

Also, the success rate of UPPP is described in the literature as inconsistent, with failure rates spanning from 30% to as high as 90%^{10,11}.

Anterior palatoplasty is considered to be an effective surgical method for the treatment of OSA. This type of surgery is directly addressed to the anatomical structures involved in airway obstruction and targets the anterior portion of the soft palate, where the creation of scar tissue can lead to a desired firmness, preventing the soft palate from falling back against the throat during sleep.

Numerous studies have sustained that AP surgery is effective, demonstrating notable enhancements in the

AHI of the patients¹⁶. Most authors report improvement of AHI after anterior palatoplasty in the treatment of patients with mild and moderate OSA secondary to retropalatal obstruction. In 2009, Pang et al.¹⁵ had 39 OSA patients. They report that in these patients, the AHI was reduced from 25.3 ± 12.6 to 11.0 ± 9.9 after anterior palatoplasty ($p < 0.05$), while the lowest SpO₂ levels increased from 81.4% to 92.0%¹⁵. In 2018, Pang et al.²⁴ conducted a systematic evaluation that demonstrated that anterior palatoplasty yields similarly positive outcomes compared to other procedures of palatal surgery in adults. They included in the review 6 studies, with a total of 240 OSA patients (arange between 13 and 77, mean age from 21 to 51 years) which were evaluated with polysomnography before and after anterior palatoplasty with or without multilevel surgery. They reported an improvement in all evaluated parameters: AHI mean values decreased from 16.3/h to 7.1/h, ESS reduced from 11.3 to 7.3, with an overall success rate of 72.5%²⁴.

Marzetti et al.²⁵, in 2013, performed a prospective study on 38 consecutive patients with mild-moderate OSA comparing the results of anterior palatoplasty (AP) and of uvulopalatal flap (UPF) by AHI, ESS scores, snoring questionnaire (SQ), changes in collapse degree at Muller maneuver. In the AP patients, the authors reported that AHI improved from 22 ± 12.5 to 8.6 ± 6.8 ($p < 0.001$), the ESS mean decreased from 8.5 ± 3.7 to 4.9 ± 3.2 ($p < 0.001$) and the Muller maneuver noted a collapse degree improved from 2.7 ± 1.0 to 1.1 ± 0.9 ($p < 0.001$). In the UPF patients, the AHI improved from 23 ± 12.3 to 9.6 ± 7.8 ($p < 0.001$), the ESS scores dropped from 8.1 ± 3.5 to 5.2 ± 3.2 , and the collapse degree from 2.8 ± 1.1 to 1.8 ± 1.1 ($p < 0.05$). The overall success rate was of 86% in patients undergoing AP and of 84% in patients with UPF, the most significant difference between the two groups being represented by the pain degree – mean duration for AP = 7.1 days and 10.8 days for UPF patients ($p < 0.05$). Ugur et al.²⁶ evaluated the long-term efficacy of anterior palatoplasty on 42 patients with mild and moderate OSAS. They reported a success rate of 57.1% after 2 years, with a significant reduction in total AHI ($p < 0.025$), oxygen desaturation index ($p < 0.025$), snoring VAS and ESS scores ($p < 0.001$). In a study published in 2014, Salamanca et al.²⁷ evidenced a reduction in the AHI from 8.9 to 3.8 and in mean snoring VAS score from 9.2 to 2.9 on 24 patients who performed barbed anterior palatoplasty.

From the postoperative pain point of view, in the research conducted by Haytuglu and colleagues²⁸, it was determined that anterior palatoplasty is associated with less postoperative pain when compared to the uvulopalatal flap procedure ($p < 0.009$). The overall success rate in AHI reduction was of 81.8% in the anterior palatoplasty group and of 82.6% in patients who underwent the flap procedure²⁸.

In the meta-analysis published in 2018, Binar et al.¹⁶ evaluated the surgical success rate and the general out-

comes of anterior palatoplasty. They defined the surgical success rate as “a reduction in the apnea-hypopnea index of 50% or greater and an AHI of less than 20 postoperatively”. On 170 patients included in the meta-analysis, the surgical success rate was of 60.6%.

In our study, we investigated the efficiency of AP technique in the treatment of 16 patients with mild and moderate OSA. The results indicate that every patient experienced a significant reduction in the number of obstructive sleep apneas 6 months after surgery, resulting in improved postoperative health. The overall success rate in our study group was of 61.43%, the findings being similar to those reported by other researchers. It was also highlighted in our study that the lowest oxygen saturation levels had increased in all patients, with an average rise of 2.57% from preoperative measurements. This indicated that the oxygen saturation levels had improved.

While polysomnographic findings provide objective data in the assessment of patients with OSA, they may not always correlate with the patient’s quality of life, symptoms, and overall satisfaction. In the treatment of OSA, it was observed that subjective reports of improvement often are higher than objective outcomes recorded by polysomnography²⁹. Weaver et al.³⁰ have noted that polysomnographic indices might fail to register all the significant aspects for patients with mild and moderate OSA. Therefore, it is necessary to evaluate clinical outcomes that reflect the patient’s perspective, despite the subjective nature of such measures. Our study recorded a notable decrease in daytime sleepiness as assessed by the ESS, with scores dropping by 2.60 points on average (from a preoperative score of 10.40 to a postoperative score of 7.80). This reduction in the ESS score reflects a significant improvement in daytime alertness and a reduction in the likelihood of falling asleep during daily activities, which can be a critical aspect of improved quality of life for patients suffering from sleep apnea.

In our study, postoperative bleeding was not noted among the patients who underwent AP with or without reducing of the uvula, similar to the data found in the literature. In contrast, postoperative bleeding has been reported in 2 - 6% of patients following UPPP^{9,22}.

Another frequent complication associated with surgery of the soft palate and of the lateral pharyngeal walls is velopharyngeal insufficiency. According to the literature, velopharyngeal insufficiency was seen in 56% of patients at 6 weeks after UPPP surgery and persisted in 24% of patients after one year³¹. Based on the literature, the percentage of patients who experienced velopharyngeal insufficiency after AP surgery was significantly lower than that of UPPP patients^{32,33}. In our study, we did not observe any velopharyngeal insufficiency 6 months after surgery.

Despite the relatively small number of patients (n=16), each patient experienced a notable decrease in their AHI values and a marked improvement in their lowest oxygen

saturation levels. These objective improvements were paralleled by subjective enhancements in terms of reduced sleepiness and decreased snoring intensity, as reported by both the patients and their sleep partners.

The subjective and objective improvements that have been noticed may suggest that the fibrotic scarring of the palate attained through the anterior palatoplasty technique is substantially more effective than other techniques that have been documented.

CONCLUSIONS

The anterior palatoplasty procedure that was used in our research has shown to have positive results in the treatment of patients who have mild and moderate obstructive sleep apnea.

In addition, the AP tends to have less postoperative complications and it associates less pain compared to other methods that are used to treat mild to severe obstructive sleep apnea.

To precisely evaluate the effectiveness and reliability of this procedure, it is imperative to carry out comparative and randomized controlled prospective studies that yield long-term outcomes, including preoperative and postoperative data.

Funding: None.

Conflicts of interest: The authors declare that they have no conflicts of interest.

Contribution of authors: All authors equally contributed to this article.

Financial disclaimer: None.

Authors’ information

Ionut Tanase, ENT specialist, PhD, Assistant Professor, “Carol Davila” University of Medicine and Pharmacy, ENT&HNS Department, “Sfanta Maria” Hospital, Bucharest, Romania. E-mail: ionut.tanase@medicover.ro. ORCID: <https://orcid.org/0000-0003-4475-7737>.

Shirley Tarabichi, ENT Resident Doctor, PhD student, “Carol Davila” University of Medicine and Pharmacy, ENT&HNS Department, “Sfanta Maria” Hospital, Bucharest, Romania. E-mail: shirley.tarabichi@gmail.com. ORCID: <https://orcid.org/0000-0002-5966-3314>.

REFERENCES

1. Eckert DJ, Malhotra A. Pathophysiology of adult obstructive sleep apnea. *Proc Am Thorac Soc.* 2008;5(2):144-53. DOI: 10.1513/pats.200707-114MG.
2. Peppard PE, Young T, Palta M, Skatrud J. Prospective study of the association between sleep-disordered breathing and hypertension. *N Engl J Med.* 2000;342(19):1378-84. DOI: 10.1056/NEJM200005113421901.
3. Walia HK, Li H, Rueschman M, Bhatt DL, Patel SR, Quan SF, et al. Association of severe obstructive sleep apnea and elevated blood pressure despite antihypertensive medication use. *J Clin Sleep Med.* 2014;10(8):835-43. DOI:

- 10.5664/jcsm.3946.
4. Young T, Palta M, Dempsey J, Skatrud J, Weber S, Badr S. The occurrence of sleep-disordered breathing among middle-aged adults. *N Engl J Med.* 1993;328(17):1230-5. DOI: 10.1056/NEJM199304293281704.
 5. Yagi H, Nakata S, Tsuge H, Yasuma F, Noda A, Morinaga M, et al. Morphological examination of upper airway in obstructive sleep apnea. *Auris Nasus Larynx.* 2009;36(4):444-9. DOI: 10.1016/j.anl.2008.11.003.
 6. Marques M, Genta PR, Azarbarzin A, Sands SA, Taranto-Montemurro L, Mes-sineo L, et al. Retropalatal and retroglossal airway compliance in patients with obstructive sleep apnea. *Respir Physiol Neurobiol.* 2018;258:98-103. DOI: 10.1016/j.resp.2018.06.008.
 7. Yaremchuk K. Palatal procedures for obstructive sleep apnea. *Otolaryngol Clin North Am.* 2016;49(6):1383-97. DOI: 10.1016/j.otc.2016.07.011.
 8. Li HY. Palatal surgery for obstructive sleep apnea: from ablation to reconstruction. *Sleep Med Clin.* 2019;14(1):51-8. DOI: 10.1016/j.jsmc.2018.10.006.
 9. Fujita S, Conway W, Zorick F, Roth T. Surgical correction of anatomic abnormalities in obstructive sleep apnea syndrome: uvulopalatopharyngoplasty. *Otolaryngol Head Neck Surg.* 1981;89(6):923-34. DOI: 10.1177/019459988108900609.
 10. Zhang P, Ye J, Pan C, Sun N, Kang D. The role of obstruction length and height in predicting outcome of velopharyngeal surgery. *Otolaryngol Head Neck Surg.* 2015;153(1):144-9. DOI: 10.1177/0194599815576719.
 11. Woodson BT, Robinson S, Lim HJ. Transpalatal advancement pharyngoplasty outcomes compared with uvulopalatopharyngoplasty. *Otolaryngol Head Neck Surg.* 2005;133(2):211-7. DOI: 10.1016/j.otohns.2005.03.061.
 12. Ellis PD. Laser palatoplasty for snoring due to palatal flutter: a further report. *Clin Otolaryngol Allied Sci.* 1994;19(4):350-1. DOI: 10.1111/j.1365-2273.1994.tb01245.x.
 13. Mair EA, Day RH. Cautery-assisted palatal stiffening operation. *Otolaryngol Head Neck Surg.* 2000;122(4):547-56. DOI: 10.1067/mhn.2000.106475.
 14. Pang KP, Terris DJ. Modified cautery-assisted palatal stiffening operation: new method for treating snoring and mild obstructive sleep apnea. *Otolaryngol Head Neck Surg.* 2007;136(5):823-6. DOI: 10.1016/j.otohns.2006.11.014.
 15. Pang KP, Tan R, Puraviappan P, Terris DJ. Anterior palatoplasty for the treatment of OSA: three-year results. *Otolaryngol Head Neck Surg.* 2009;141(2):253-6. DOI: 10.1016/j.otohns.2009.04.020.
 16. Binar M, Karakoc O. Anterior palatoplasty for obstructive sleep apnea: A systematic review and meta-analysis. *Otolaryngol Head Neck Surg.* 2018;158(3):443-9. DOI: 10.1177/0194599817739857.
 17. Gagnon K, Baril AA, Gagnon JF, Fortin M, Décaray A, Lafond C, et al. Cognitive impairment in obstructive sleep apnea. *Pathol Biol (Paris).* 2014;62(5):233-40. DOI: 10.1016/j.patbio.2014.05.015.
 18. Morsy NE, Farrag NS, Zaki NFW, Badawy AY, Abdelhafez SA, El-Gilany AH, et al. Obstructive sleep apnea: personal, societal, public health, and legal implications. *Rev Environ Health.* 2019;34(2):153-69. DOI: 10.1515/reveh-2018-0068.
 19. Weaver EM, Woodson BT, Yueh B, Smith T, Stewart MG, Hannley M, et al. Studying life effects & effectiveness of palatopharyngoplasty (SLEEP) study: subjective outcomes of isolated uvulopalatopharyngoplasty. *Otolaryngol Head Neck Surg.* 2011;144(4):623-31. DOI: 10.1177/0194599810394982.
 20. Wischhusen J, Qureshi U, Camacho M. Laser-assisted uvulopalatoplasty (LAUP) complications and side effects: a systematic review. *Nat Sci Sleep.* 2019;11:59-67. DOI: 10.2147/NSS.S178540.
 21. Varendh M, Berg S, Andersson M. Long-term follow-up of patients operated with Uvulopalatopharyngoplasty from 1985 to 1991. *Respir Med.* 2012;106(12):1788-93. DOI: 10.1016/j.rmed.2012.09.010.
 22. Friedman M, Ibrahim H, Lowenthal S, Ramakrishnan V, Joseph NJ. Uvulopalatoplasty (UP2): a modified technique for selected patients. *Laryngoscope.* 2004;114(3):441-9. DOI: 10.1097/00005537-200403000-00011.
 23. Friedman M, Tanyeri H, La Rosa M, Landsberg R, Vaidyanathan K, Pieri S, et al. Clinical predictors of obstructive sleep apnea. *Laryngoscope.* 1999;109(12):1901-7. DOI: 10.1097/00005537-199912000-00002.
 24. Pang KP, Pang EB, Pang KA, Rotenberg B. Anterior palatoplasty in the treatment of obstructive sleep apnoea - a systemic review. *Acta Otorhinolaryngol Ital.* 2018;38(1):1-6. DOI: 10.14639/0392-100X-1641.
 25. Marzetti A, Tedaldi M, Passali FM. Preliminary findings from our experience in anterior palatoplasty for the treatment of obstructive sleep apnea. *Clin Exp Otorhinolaryngol.* 2013;6(1):18-22. DOI: 10.3342/ceo.2013.6.1.18.
 26. Ugur KS, Ark N, Kurtaran H, Kizilbulut G, Yuksel A, Gunduz M. Anterior palatoplasty for selected mild and moderate obstructive sleep apnea: preliminary results. *Eur Arch Otorhinolaryngol.* 2014;271(6):1777-83. DOI: 10.1007/s00405-013-2701-z.
 27. Salamanca F, Constantini F, Mantovani M, Bianchi A, Amaina T, Colombo E, et al. Barbed anterior pharyngoplasty: an evolution of anterior palatoplasty. *Acta Otorhinolaryngol Ital.* 2014;34(6):434-8.
 28. Haytoğlu S, Arıkan OK, Muluk NB, Tuhanoğlu B, Çörtük M. Comparison of anterior palatoplasty and uvulopalatal flap placement for treating mild and moderate obstructive sleep apnea. *Ear Nose Throat J.* 2018;97(3):69-78. DOI: 10.1177/014556131809700321.
 29. Friedman M, Ibrahim H, Joseph NJ. Staging of obstructive sleep apnea/hypopnea syndrome: a guide to appropriate treatment. *Laryngoscope.* 2004;114(3):454-9. DOI: 10.1097/00005537-200403000-00013.
 30. Weaver EM, Woodson BT, Steward DL. Polysomnography indexes are discordant with quality of life, symptoms, and reaction times in sleep apnea patients. *Otolaryngol Head Neck Surg.* 2005;132(2):255-62. DOI: 10.1016/j.otohns.2004.11.001.
 31. Haavisto L, Suonpää J. Complications of uvulopalatopharyngoplasty. *Clin Otolaryngol Allied Sci.* 1994;19(3):243-7. DOI: 10.1111/j.1365-2273.1994.tb01224.x.
 32. Ugur KS, Kurtaran H, Ark N, Kizilbulut G, Yuksel A, Gunduz M. Comparing anterior palatoplasty and modified uvulopalatopharyngoplasty for primary snoring patients: preliminary results. *B-ENT.* 2013;9(4):285-91.
 33. ElSalmawy A, fathy H, Safwat M, Al Najjar A. The role of anterior palatoplasty for treatment of snoring and obstructive sleep apnea. *Pan Arab Journal of Rhinology.* 2018;8(2):39-43.

