

## CASE REPORT

# Blast injury with foreign body in maxillary sinus: A case report

Jibin C Joshi, Aparna G Chavan, Shaila Sidam, Anjan Kumar Sahoo<sup>ORCID</sup>

Department of ENT and Head & Neck Surgery, All India Institute of Medical Sciences, Bhopal, India

### ABSTRACT

**BACKGROUND.** Foreign bodies of paranasal sinuses are very rare in ENT clinical practice.

**CASE REPORT.** We will discuss the case of a 38-year-old gentleman who showed up at our Emergency Room with loss of vision in his left eye following a blast injury. The initial physical examination identified a ruptured globe in the left eye, which caused left-eye blindness. An immediate plain X-ray revealed a metallic object lodged in the left maxillary sinus, reaching up to the left sphenoid sinus. The external approach was used to manage the patient surgically, with no intra- or postoperative complications.

**CONCLUSION.** Inadequate managing of foreign bodies in the paranasal sinuses might result in significant morbidity. They must be removed surgically, either endoscopically or via an external method.

**KEYWORDS:** maxillary sinus, paranasal sinus, foreign bodies.

### INTRODUCTION

Foreign bodies are more commonly seen in children. Paranasal sinus foreign bodies are very rare, in which the maxillary sinus is the most common location due to its proximity to the oral cavity and skin surface<sup>1</sup>.

Blast injuries can cause facial trauma. Industrial, car, and home accidents can all result in these injuries. In Indian houses, explosions from pressure cookers and liquefied petroleum gas cylinders in the kitchen are the two most frequent sources of unintentional blast injuries. Such incidents may result in ingesting foreign objects into the paranasal sinuses. However, only approximately 25% of paranasal sinus foreign bodies are accident-related; the majority (60%) are iatrogenic. Maxillary sinus involvement occurs most frequently (80%)<sup>2</sup>. Iatrogenic foreign bodies are most frequently found following dental operations, such as implants, titanium plates, and gutta-percha. Different foreign bodies, including wooden sticks and toothpicks, have been discovered in accidents. Typically, these foreign bodies are only found when a patient has chronic sinusitis or just by chance during a radiological evaluation.

The maxillary sinus is sometimes injured by weapons

such as bomb blasts, gunshots, and knife wounds. However, these injuries are usually accompanied by other facial wounds. In the sinuses, pellets may be present and trigger problems in the future.

Many techniques are used to remove foreign objects from the sinus. The foreign body's size, form and location define the kind of management. The removal of foreign bodies frequently involves the lateral window technique, endoscopic sinus surgery, and the Caldwell-Luc method<sup>3</sup>.

This case study describes a foreign body found in the maxillary sinus after penetrating the malar area and was extracted through the same entry wound.

### CASE REPORT

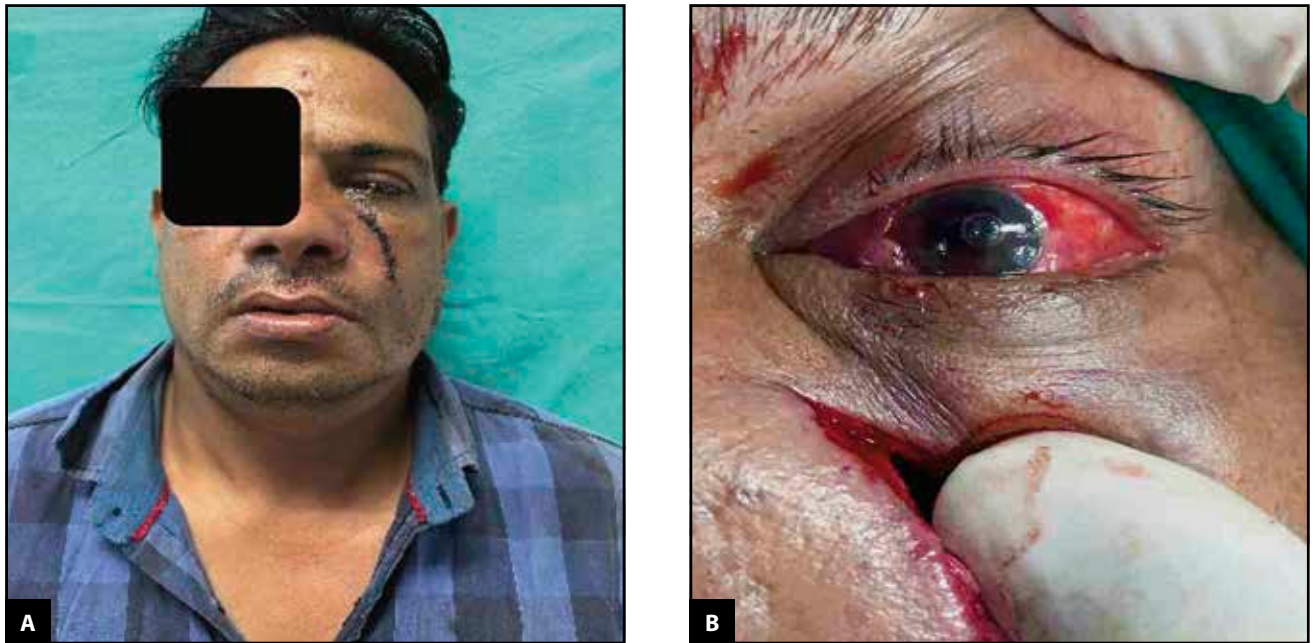A 38-year-old gentleman, who is a refrigerator mechanic by profession, presented to the Emergency Department with complaints of loss of vision in the left eye following a trauma 3 days back. The patient sustained an injury to the left eye as well as the left malar area, following a blast while operating on the compressor of a refrigerator. He consulted the nearby local hospital in view of laceration of the face and loss of vision in the left eye. These symptoms were associated with numbness and paraesthesia of the left infraorbital

**Corresponding author:** Dr Anjan Kumar Sahoo, Associate Professor, Department of ENT and Head & Neck Surgery, All India Institute of Medical Sciences, Bhopal, India, **Address:** Department of ENT, 2nd floor, Academic Block, AIIMS, Bhopal, India, PIN: 462020

**ORCID:** <https://orcid.org/0000-0002-8073-6549>

**e-mail:** anjan.ent@aiimsbhopal.edu.in

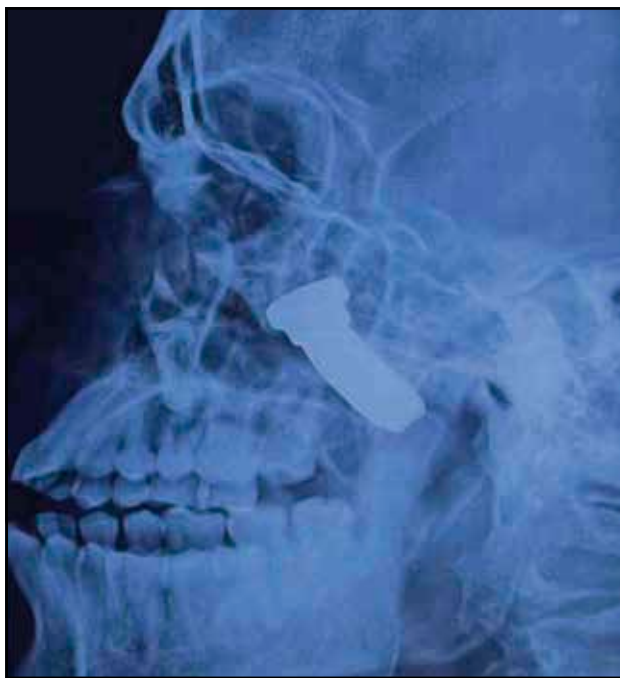**Received for publication:** August 10, 2024 / **Accepted:** September 5, 2024



**Figure 1. A:** Sutured lacerated wound of around 5 cm in the left nasolabial fold; **B:** Conjunctival congestion with corneal rupture and entrapment of air in the anterior chamber of the left eye ball.

bital area. The laceration was sutured, and the patient was referred to us for further management.

On examination, there was a sutured laceration of 5 cm in the region of the left nasolabial fold, extending superiorly till 1.5 cm below the lower lid (Figure 1A). There was conjunctival congestion with corneal rupture and entrap-



**Figure 2.** X-ray of the nose and paranasal sinuses (lateral view) showing an abnormal curved radio-opaque shadow near the posterior wall of the left maxillary sinus.

ment of air in the anterior chamber of the left eyeball (Figure 1B). The vision was only hand movements close to the eye on the left side with a projection of light present from all the quadrants.

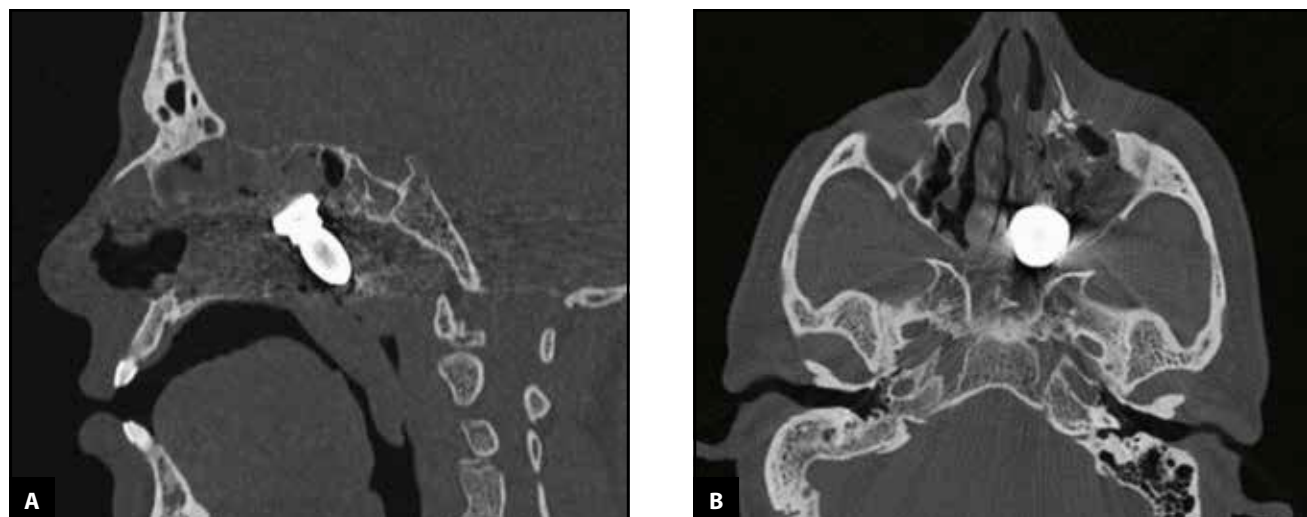The loss of vision was aggressively managed by the Ophthalmology Department, with a grave prognosis. The final result was no change in the loss of vision in the left eye.

The X-ray of the nose and paranasal sinuses showed an abnormal curved radio-opaque shadow (metallic object) located near the posterior wall of the left maxillary sinus, with one end extending to the left nasal cavity (Figure 2).

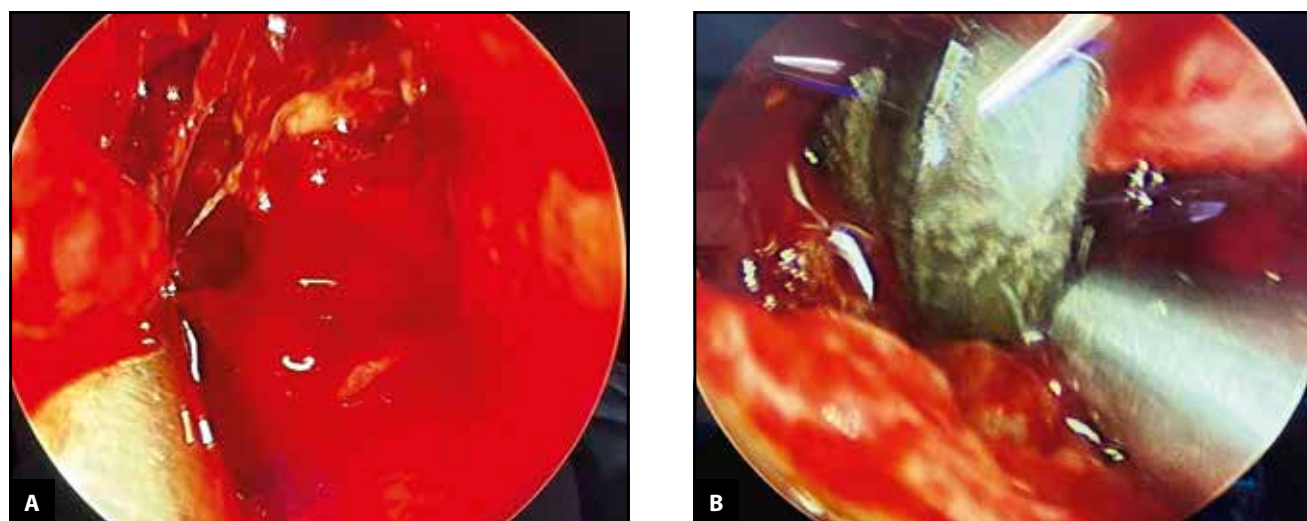
A CT scan of the nose and paranasal sinuses without contrast was performed. The scan revealed a retained big dense foreign body in the posterior wall of the left maxillary sinus reaching up to the left sphenoid sinus, a ruptured left globe, a fracture of the left inferior orbital wall, and fat herniation from the same aperture (Figure 3 A,B).

In order to save the left eye, the patient was prepared and brought instantaneously to the operating room (OR). Endoscopic evaluation of the left nasal cavity was done, and one end of the metallic foreign body was coming out through the exit wound, just above the posterior end of the left inferior turbinate (Figure 4A and 4B).

The previously sutured left malar laceration was opened, and the wound was inspected. A metallic foreign body was found touching the posterior wall of the left maxillary sinus, around 5 cm deep from the skin surface, with complete destruction of the floor of the left orbit and was associated with globe injury. The foreign body (a metallic pipe of 4 cm length) was removed through the entry wound itself (Figure 5). An antibiotic irrigation was done



**Figure 3.** Cranio-facial CT scan – sagittal (A), axial (B) – showing a big dense foreign body in the posterior wall of the left maxillary sinus reaching up to the left sphenoid sinus, a ruptured left globe, a fracture of the left inferior orbital wall, and fat herniation from the same aperture.



**Figure 4.** Metallic foreign body seen during endoscopic evaluation in the left nostril (A and B).



**Figure 5.** Mettallic refrigerator pipe of 4 cm long.

in the entry wound. The wound was closed in layers using 3.0 vicryl and 3.0 Ethilon.

Postoperatively, the patient improved clinically with reduction in facial edema and conjunctival congestion. The entry wound healed properly with no signs of infection. But the vision loss persisted even after steroid therapy.

### DISCUSSIONS

Various accidental foreign bodies have been documented, but most of them are preceded by a dental procedure’s history. The oroantral fistula formed following a dental extraction makes it simple for different dental materials to enter the maxillary sinus. Additionally, when these fistulas close over time, it is very challenging to diagnose a foreign body. Actually, they are discovered by chance when

a patient complains of nasal symptoms, which can range from mild nasal discharge to headaches to facial puffiness. Foreign bodies in paranasal sinuses are very rare, and when they occur, they are most frequently seen in the maxillary sinus<sup>4</sup>. Maxillary sinus foreign bodies can be due to traumatic causes or non-traumatic causes.

Traumatic causes can be divided into iatrogenic or accidental. Nontraumatic causes are mainly due to ectopic molars<sup>4</sup>. The maxillary sinus is sometimes injured by munitions such as bomb blasts, gunshots, and knife wounds. However, these injuries are usually accompanied by other facial wounds.

In such cases of foreign bodies of maxillary sinuses, we should go with radiological investigations like X-ray of the paranasal sinuses or a plain computerized tomography of paranasal sinuses for exact localization and surgical planning.

Maxillary sinus foreign bodies can be removed endoscopically as well as through external approaches like Caldwell-Luc procedures, but our case was treated by an approach through the entry wound, since it was reaching the nasopharynx and the left sphenoid sinus. One option for removing the foreign bodies from the maxillary sinus is middle meatal antrostomy (MMA), but it is not the ideal option because of its high failure rate and lack of assurance of superior surgical results.

After middle meatal antrostomy failed to treat maxillary sinus illness, the Caldwell-Luc method has been the standard surgical treatment for more than 100 years. Compared to endoscopic procedures and their indications, the Caldwell-Luc method is still significant since it provides easier and safer access to the anterior wall and floor of the maxillary sinus<sup>5</sup>.

## CONCLUSIONS

Foreign bodies are rarely found in paranasal sinuses. The size and location of the foreign body determine the surgical method that should be used. The endoscopic method was impractical in this situation, and the external approach produced outstanding results. The purpose of presenting this case is to provide a general overview of how to handle a situation with an impacted metallic foreign body in the maxillary sinus following a blast injury and determine the optimum method of removal.

Blast injuries require a complete evaluation by a detailed history, examination and imaging, because the sequence of

events in a blast kind of injury is quick and foreign materials may be missed in these emergency cases. Even when a patient has to be transported to an emergency facility for surgery, a radiological postoperative examination is required. Although a foreign body is a rare cause of chronic unilateral sinusitis or rhinorrhea, it should be considered as a differential diagnosis for patients who also have these conditions. A thorough previous history could reveal the presence of a foreign body.

**Funding:** None. Our institute is a central government hospital, and all the treatments are free.

**Contribution of authors:** Dr Jibin and Dr Shaila: Preparation of manuscript, editing. Dr Aparna and Dr Anjan: Drafting, Final Editing

**Conflict of interests:** None.

**Financial disclosure:** Nil.

### Authors' information

Jibin C Joshi, Senior Resident, Department of ENT and Head & Neck Surgery, All India Institute of Medical Sciences, Bhopal, India. E-mail: deptofenths@aiimsbhopal.edu.in.

Aparna G Chavan, Professor, Department of ENT and Head & Neck Surgery, All India Institute of Medical Sciences, Bhopal, India. E-mail: aparna.ent@aiimsbhopal.edu.in.

Shaila Sidam, Associate Professor, Department of ENT and Head & Neck Surgery, All India Institute of Medical Sciences, Bhopal, India. E-mail: shaila.ent@aiimsbhopal.edu.in.

Anjan Kumar Sahoo, Associate Professor, Department of ENT and Head & Neck Surgery, All India Institute of Medical Sciences, Bhopal, India. E-mail: anjan.ent@aiimsbhopal.edu.in. ORCID: <https://orcid.org/0000-0002-8073-6549>

## REFERENCES

1. Agarwal S, Kumar S. Foreign bodies in maxillary sinus: Causes and management. *Astrocyte*. 2014;1(2):89.
2. Preda M, Sarafoleanu C. Foreign body of endodontic origin in the maxillary sinus. *Romanian Journal of Rhinology*. 2021;11(43):111-7. DOI: 10.2478/rjr-2021-0019
3. Alrasheed MA, Albhaddad MS, Almuahiny NA, Almohammedali AA. An unusual maxillary sinus foreign body: A case report. *Am J Case Rep*. 2021;22:e928534-1-e928534-9. DOI: 10.12659/AJCR.928534.
4. Kayabasoglu G, Karaman M, Kaymaz R, Nacar A. A rare entity causing chronic sinusitis: ectopic tooth in maxillary sinus. *Eur J Gen Med*. 2015;12(1):86-9.
5. Hajjioannou J, Exarchos S, Lachanas V, Bizakis J. In the era of endoscopic sinus surgery, is there still a place for the Caldwell-Luc procedure? *B-ENT*. 2016;12(2):99-102.

