




## CASE REPORT

# Prosthetic restoration in frontal maxillary area using digital technologies: Case presentation (Part II)

Mihai David<sup>1</sup>, Elena Georgiana Radu<sup>1</sup>, Madalina Adriana Malita<sup>1</sup> , Viorel Stefan Perieanu<sup>1</sup>,   
 Maria Antonia Stetiu<sup>2</sup>, Florentina Caministeanu<sup>1</sup>, Ruxandra Stanescu<sup>1</sup>, Mircea Popescu<sup>1</sup>,  
 Mihai Burlibasa<sup>1</sup> , Mihaela Chirila<sup>1</sup>

<sup>1</sup>“Carol Davila” University of Medicine and Pharmacy, Bucharest, Romania

<sup>2</sup>“Lucian Blaga” University, Sibiu, Romania

## ABSTRACT

Digital technologies represent new alternatives in prosthetic rehabilitation of all kind of maxillary or mandibular spans. This article is composed of two parts, in which different technological aspects will be presented regarding the prosthetic restoration of frontal maxillary areas using the CAD-CAM technology, but using different material for resistance framework, both veneered with ceramic materials to restore the aesthetics. The main material that will be used are: Co-Cr dental alloy and zirconium dioxide (zirconia).

**KEYWORDS:** Co-Cr dental alloy, dental bridges, ceramic masses.

## INTRODUCTION

The maxillary frontal area at the level of the oral cavity is the most visible area when a person smiles. Practically, during the smile, all the teeth belonging to the upper frontal group are highlighted (usually the labial surfaces of these teeth), on either side of the median line, but also the buccal faces of the upper premolars (especially of the first premolars).

## GENERAL DATA

At the present time, each individual places a great deal of emphasis on the smile, sometimes resorting to certain dental procedures to improve their physiognomy, and, implicitly, their smile as well<sup>1-4</sup>. And if there is an alteration of the smile of dental nature, meaning that the upper and/or lower front dental teeth are affected (see carious processes, trauma, colour changes, etc.), that indi-

vidual will be willing to make considerable efforts both from a financial point of view, but also of time to restore his image.

Using state-of-the-art technology and materials, high-quality prosthetic restorations can be achieved, as well as their long-lasting durability. The most used materials for manufacturing the resistance structures of prosthetic restorations used in current dental practice are zirconium dioxide (zirconia), as well as alloys based on chromium, cobalt-chromium (Co-Cr) and nickel-chromium (Ni-Cr), which later are plated for physiognomic purposes with ceramic masses of different categories<sup>1-4</sup>.

Thus, in this second part of the material, the prosthetic rehabilitation in the maxillary frontal area with the help of a dental bridge will be presented. The resistance infrastructure will be made of cobalt-chromium dental alloy (Co-Cr) through CAD-CAM digital technology, infrastructure later plated with ceramic masses for aesthetic purposes<sup>1-4</sup>.

**Corresponding author:** Madalina Adriana Malita, MD, PhD, Lecturer, “Carol Davila” University of Medicine and Pharmacy, Bucharest, Romania

**Address:** 4 Eforie, District 5, Bucharest

**ORCID:** <https://orcid.org/0009-0005-1027-3218>

**e-mail:** madalina.malita@umfcd.ro

**Received for publication:** March 29, 2025 / **Accepted:** April 10, 2025



**Figure 1.** Functional maxillary impression, mandibular impression and the occlusal record.

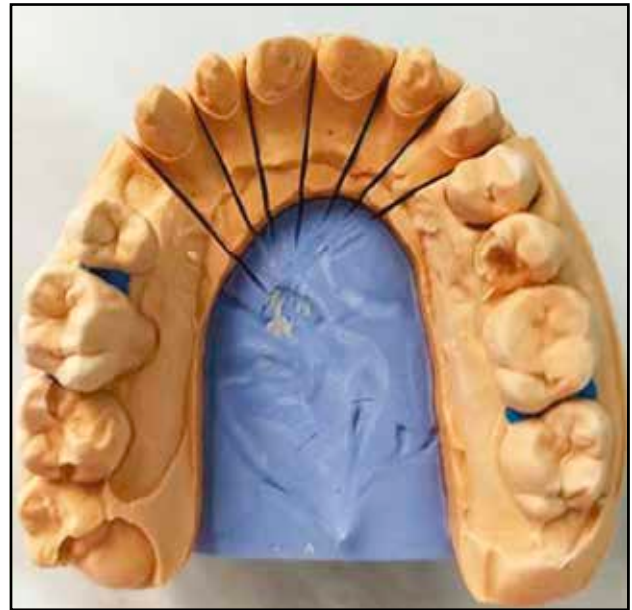## CASE PRESENTATION

Metal-ceramic full coverage prosthetic restoration in maxillary frontal area on a metallic support based on cobalt-chromium alloy (Co-Cr).

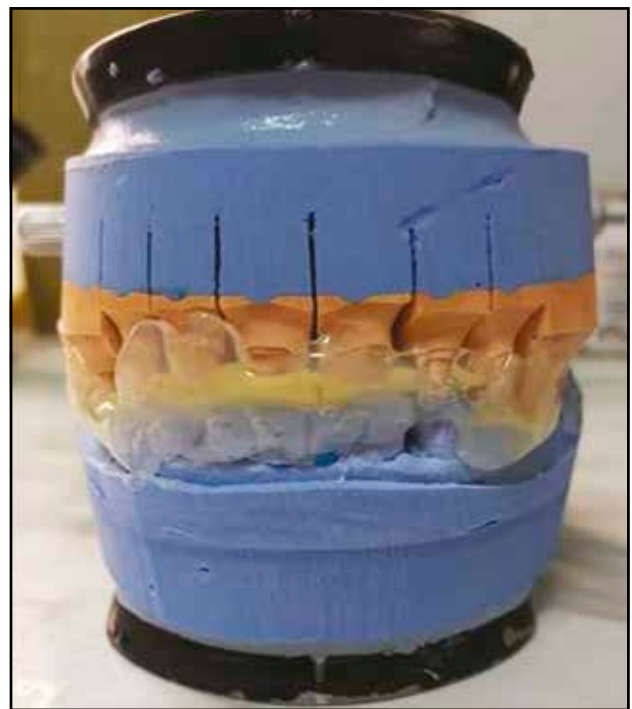A 36-year-old female patient came to the dental office to improve the aesthetic appearance of the frontal area of teeth 1.3-2.3, which are still intact on the arch, but are affected by multiple carious processes – some treated correctly, others incorrectly, some untreated or with physiologically outdated fillings. At the same time, the patient also had an issue at the level of the upper first premolar dentition, namely 1.4.

Taking into account the patient's desire regarding the aesthetic rehabilitation of the maxillary frontal area, the dentist, together with the dental technician, having the written consent of the patient, opted for a prosthetic restoration of the 6 teeth (1.3-2.3) with an extension at the level of 1.4. The substructure was made of cobalt-chromium (Co-Cr) dental alloy, obtained through CAD-CAM technology, and later veneered with ceramic masses for aesthetic purposes. After performing the endodontic treatments on teeth 1.3-2.3, all 6 teeth were shaped, obtaining the corresponding dental abutments, in order to make a dental bridge.

The dentist took the functional impression (Figure 1) in a standard impression tray in 2 steps, with condensation silicone materials of different consistencies: putty and light body. The occlusal relationship was recorded separately with the aid of a condensing silicone strip of putty consistency. The impression of the antagonistic mandibular arch was also made in the standard impression tray, but only with a putty consistency silicone condensation material. The impressions were decontaminated by



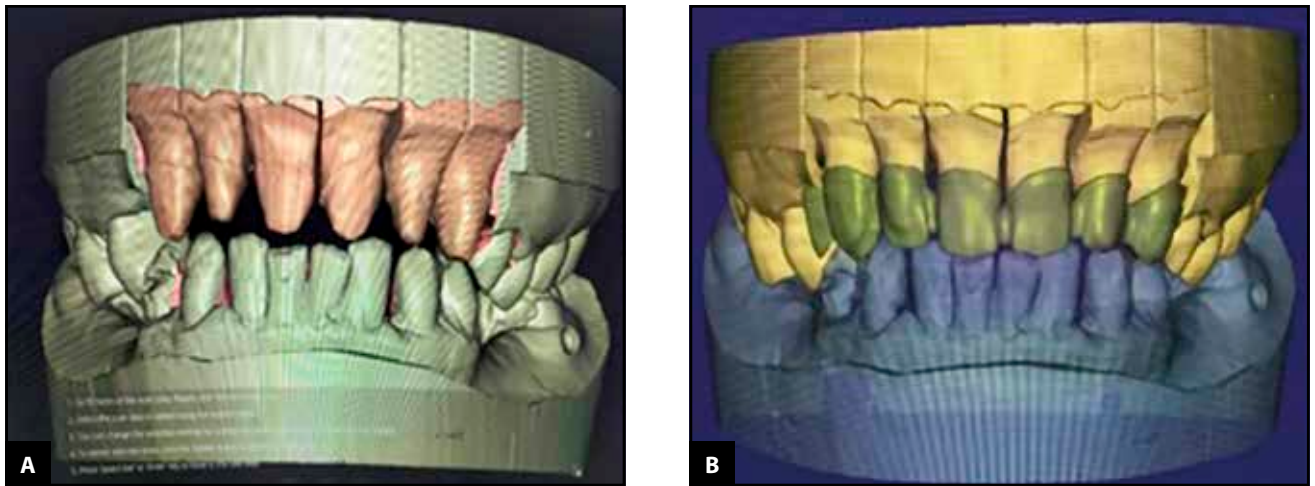
**Figure 2.** The sectional maxillary model obtained using the Pindex system.



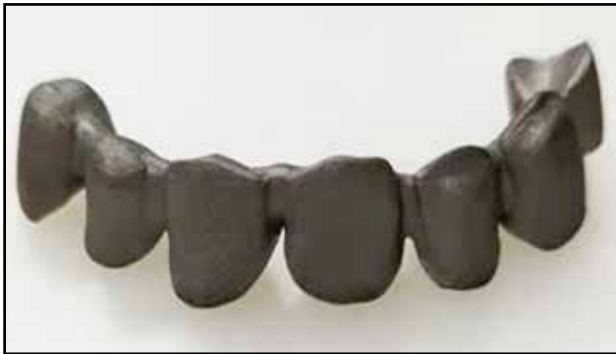**Figure 3.** The models mounted in the occlusal simulator using the record sent from the dental office

immersion in specific antimicrobial disinfectants, following the manufacturers' recommendations.

The sectional maxillary model was obtained using the Pindex system (Figure 2). The main model was made of type IV dental stone, while the base of the model was made of type III dental stone. The mandibular antagonistic model was made using classic technique and type III dental stone.



**Figure 4.** The virtual models positioned using the occlusal record (a); The design of the metallic substructure that will be made of Co-Cr dental alloy (b).



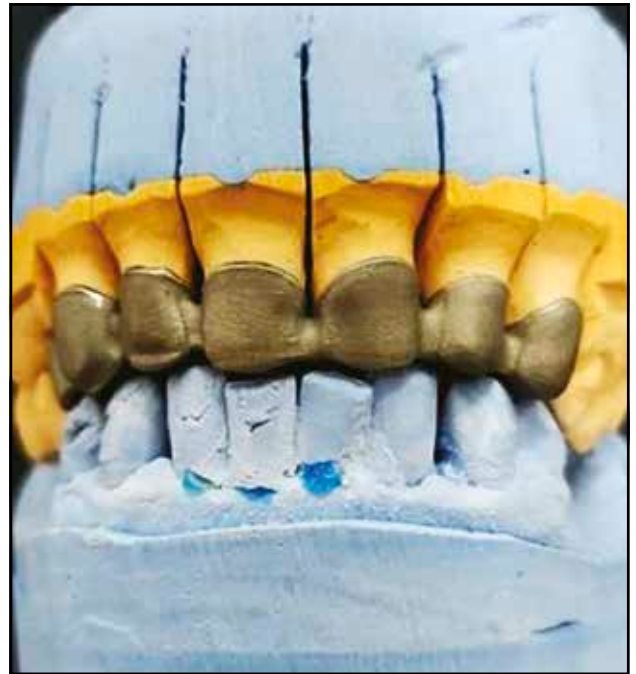**Figure 5.** Metal substructure obtained after computerized milling.

Each individual die of the maxillary model was trimmed to highlight the marginal preparation. A layer of die spacer was applied to create the space necessary for luting cement. The models were mounted in the occlusal simulator based on the occlusal record made by the dentist (Figure 3).

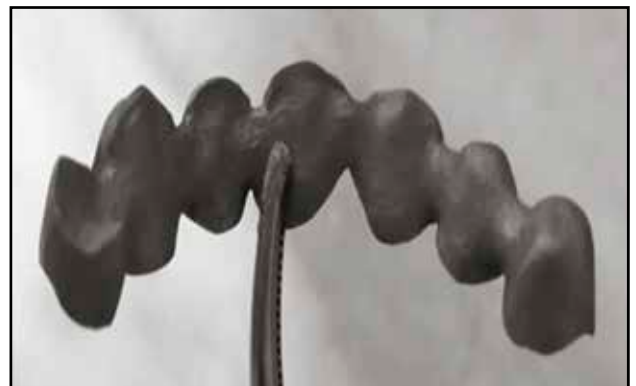
Both maxillary and mandibular models were scanned using a dental laboratory scanner. On the virtual model, the limit of the preparations is drawn and different settings as type of prosthetic restoration, neighbouring teeth, opposing teeth are selected so the software (Exocad) can provide a personalized design for the virtual pattern (Figure 4a). In this clinical case, the virtual pattern is designed to be manufactured from dental alloy for a metal-ceramic restoration (Figure 4b).

The virtual pattern was sent in STL format to a computerized milling centre, to obtain the metal support of the future metal-ceramic full coverage prosthetic restoration (Figure 5).


The metal substructure was adapted to the maxillary functional model (Figure 6), in occlusion with respect to the mandibular model, but also in the patient's oral cavity (the last operation was per-



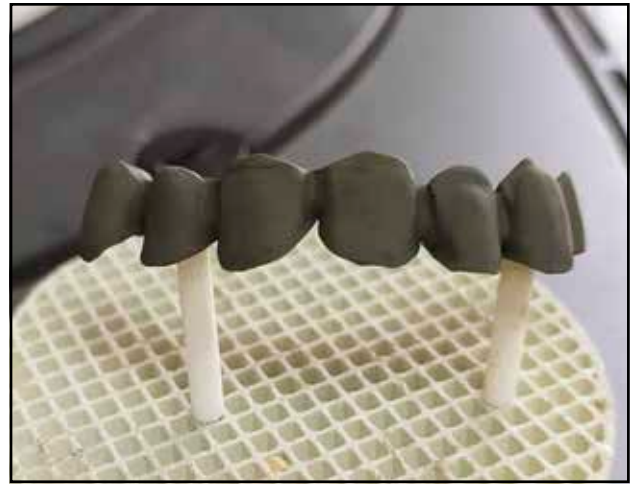**Figure 6.** Metal substructure fitted on the functional model.



**Figure 7.** The metal substructure at the end of the sandblasting process.



**Figure 8.** The metal substructure at the beginning of the oxidation program using the firing furnace.

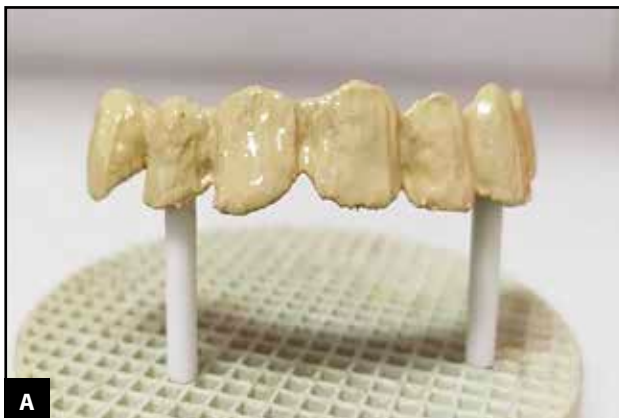

**Figure 9.** The metal substructure at the end of the oxidation process.

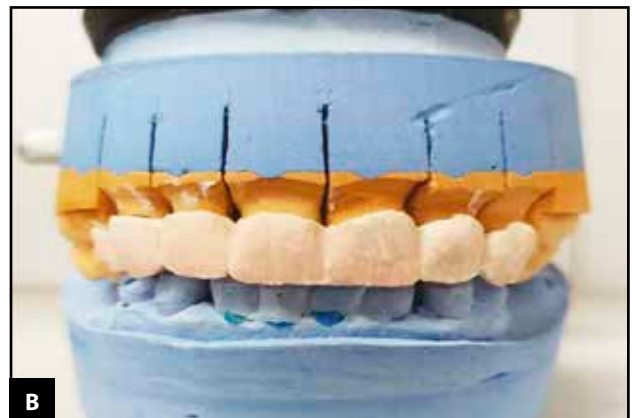
formed by the dentist in the specialized office). It was then washed and decontaminated using chemicals with antimicrobial potential, following the manufacturers' instructions, in order to remove

any traces of saliva and/or blood.

The metal infrastructure was sandblasted, a process followed by an oxidation process in the firing furnace, following an oxidation program with a

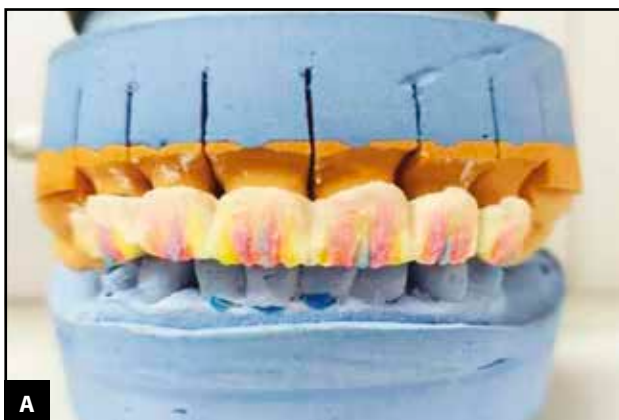


**A**

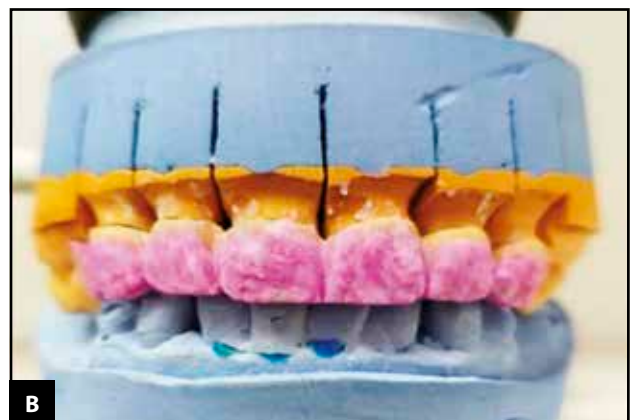

**B**

**Figure 10.** The aspect of opaque layers applied on the metal substructure at the end of the firing process (a); The dentin layers applied to create the general shape of the teeth (b).

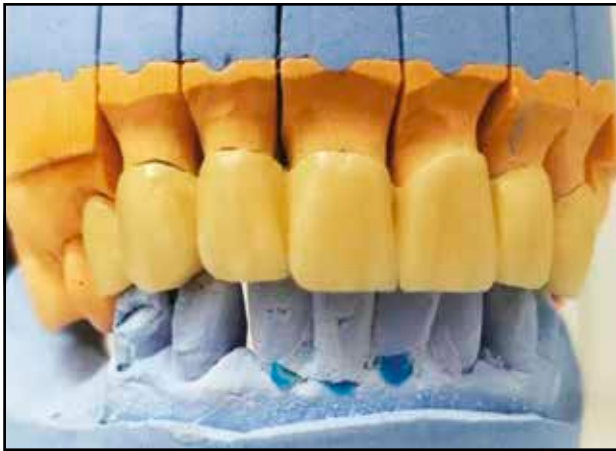

**A**

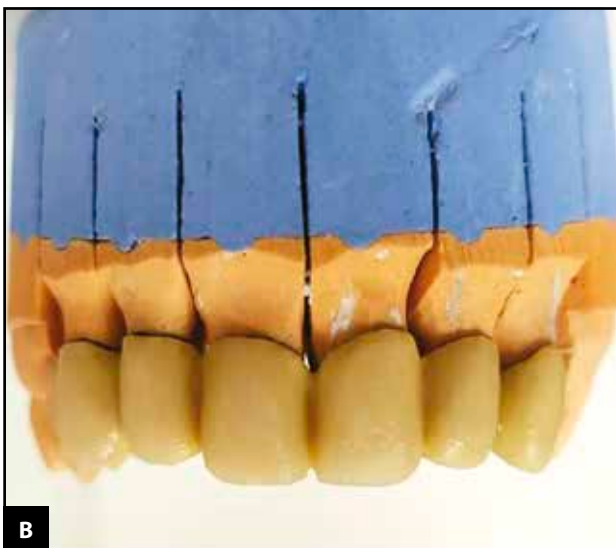
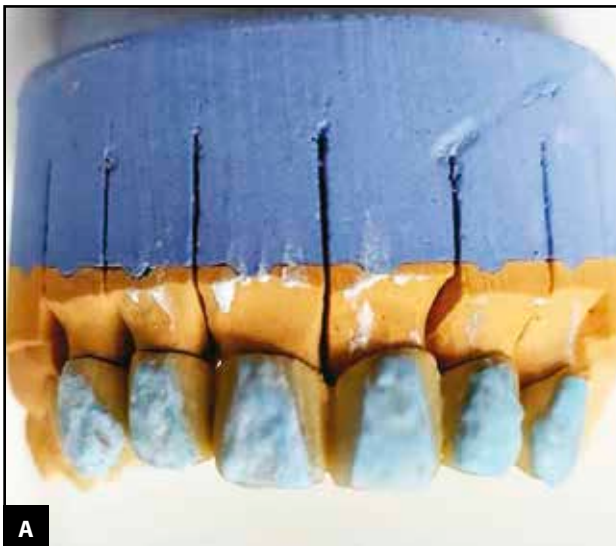

**B**

**Figure 11.** Special ceramic applied to create visual effects (a); The enamel layer (b).



**Figure 12.** The prosthetic restoration after applying the aesthetic component ready to be sent for try in.



**Figure 13.** Applying correction material based on indications made by the dentist before (a) and after firing (b).

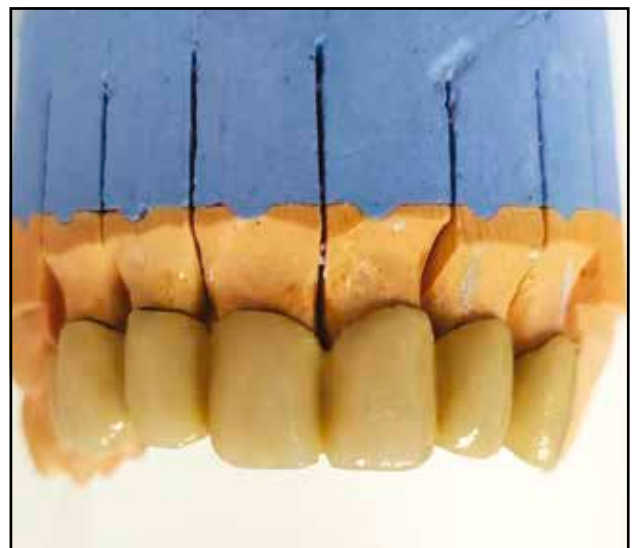
temperature of approximately 980°C (Figure 7, Figure 8, Figure 9).

Obtaining the aesthetic component consists in veneering the metal substructure with ceramic masses, respecting specific stages: the application of wash-dentin, the application of opaque layers by brushing (for covering the colour of the metal substructure), the application of dentin layers and the creation of coloristic effects, as well as the enamel layers (Figure 10, Figure 11). Each stage is followed by specific firing programs, adapted according to the material used. After firing the last layer of enamel, the aesthetic component is processed with the help of burs and diamond discs, and the prosthetic restoration is sent to the dental office, for try in (Figure 12).

The last technical stages consisted of making corrections if they were necessary, as well as applying the glaze layer and firing it (Figure 13). At the end, the prosthetic restoration was sent to the dental office for cementation (Figure 14).

## DISCUSSIONS

The new technologies that appeared in the technological flow of prosthetic restorations, even if they have clearly superior advantages, are limited due to financial considerations<sup>5,6</sup>. The financial effort to implement a fully digital workflow is high, which is why many technicians opt for fragmented solutions, focused especially on the area of digital scanning and design<sup>7,8</sup>. The translation from digital to real is outsourced to other labora-



**Figure 14.** The final aspect of prosthetic restoration before being sent to the dental office for cementation.

tories or centres specially equipped for milling and sintering.

Choosing such an option reduces the time that a technician spends in making the metal component without a decrease in the quality of the metal component obtained<sup>9,10</sup>. The final stage, that of applying the ceramic mass to obtain the shape of the teeth, falls to the dental technician and is based on the experience accumulated over time and the information sent from the office<sup>11,12</sup>.

Obtaining the metal component either by milling or by laser sintering eliminates a number of inconveniences compared to obtaining the metal component by the lost wax technique. The virtual model on which the mock-up is made can be carefully analyzed, the enlargement of the image allowing a much more correct selection of the margin of the preparation and implicitly a superior marginal adaptation<sup>13,14</sup>. At the same time, the virtual model is free of dimensional variations compared to the wax used in classic technologies and can be made with a much better controlled thickness<sup>15,16</sup>. The calibration of the equipment made the adaptation of the metal component as precise as possible and free of the casting defects found in the classic procedure.

## CONCLUSIONS

With the help of CAD-CAM milling centres, prosthetic restorations with zirconia infrastructure, as well as those made from various metal alloys for dental use (stainless alloys such as Co-Cr, Ni-Cr, titanium and titanium alloys), are produced much faster than the prosthetic restorations made using the already known classical technologies.

Practically, the manufacture of such prosthetic restorations, some particularly complex, can be completed even within 24 hours, and the materials used are in continuous development and improvement, aspects that contribute significantly to the development of dentistry, and implicitly, of dental technology as well.

**Funding:** None.

**Conflict of interest:** The authors have no conflict of interest.

**Contribution of authors:** All the authors have equally contributed to this work.

**Financial disclosure:** There are no financial disclosures of the authors.

### Authors' information

Mihai David, MD, PhD, Lecturer, "Carol Davila" University of Medicine and Pharmacy, Bucharest, Romania. E-mail: mihai.david@umfcd.ro.

Elena Georgiana Radu, Dental Technician, "Carol Davila" University of Medicine and Pharmacy, Bucharest, Romania. E-mail: trili\_poli@yahoo.com.

Madalina Adriana Malita, MD, PhD, Lecturer, "Carol Davila" University of Medicine and Pharmacy, Bucharest, Romania. E-mail: madalina.malita@umfcd.ro. ORCID: <https://orcid.org/0009-0005-1027-3218>.

Viorel Stefan Perieanu, MD, PhD, Lecturer, "Carol Davila" University of Medicine and Pharmacy, Bucharest, Romania. E-mail: viorelperieanu@yahoo.com. ORCID: <https://orcid.org/0000-0002-8411-3875>.

Maria Antonia Stetiu, Student, "Lucian Blaga" University, Sibiu, Romania. E-mail: stetium@yahoo.com.

Florentina Caministeanu, MD, PhD, Assistant Professor, "Carol Davila" University of Medicine and Pharmacy, Bucharest, Romania. E-mail: florentina.caministeanu@drd.umfcd.ro.

Mircea Popescu, PhD Student, "Carol Davila" University of Medicine and Pharmacy, Bucharest, Romania. E-mail: mircea.popescu@drd.umfcd.ro.

Mihai Burlibasa, MD, PhD, Professor, "Carol Davila" University of Medicine and Pharmacy, Bucharest, Romania. E-mail: mburlibasa@gmail.com. ORCID: <https://orcid.org/0000-0001-8672-5579>.

Mihaela Chirila, MD, PhD, Associated Professor, "Carol Davila" University of Medicine and Pharmacy, Bucharest, Romania. E-mail: mihaela.chirila@umfcd.ro.

## REFERENCES

1. Cristache CM, Totu EE. CAD-CAM – O tehnologie a mileniului trei in stomatologie. Ed. Didactica si Pedagogica, Bucuresti; 2016.
2. Bratu D, Nussbaum R. Bazele clinice si tehnice ale protezarii fixe. Ed. Medicala, Bucuresti; 2006.
3. Gligor MR, Malita MA, Perieanu VS, Costea RC, Beuran IA, Burlibasa M. Aspecte teoretice si practice in tehnologia protezelor unidentare – Parte I. In: Gligor MR, Malita MA, Perieanu VS, Costea RC, Beuran IA, Burlibasa M. Tendinte moderne in stiintele biomedicale. Ed. Matrix Rom, Bucuresti; 2021, pp. 9-153.
4. Gligor MR, Malita MA, Perieanu VS, Costea RC, Beuran IA, Burlibasa M. Aspecte teoretice si practice in tehnologia protezelor unidentare – Parte II. In: Gligor MR, Malita MA, Perieanu VS, Costea RC, Beuran IA, Burlibasa M. Tendinte moderne in stiintele biomedicale. Ed. Matrix Rom, Bucuresti; 2021, pp. 154-336.
5. Joda T, Zarone F, Ferrari M. The complete digital workflow in fixed prosthodontics: a systematic review. *BMC Oral Health*. 2017;17(1):124. DOI: 10.1186/s12903-017-0415-0.
6. Stanley M, Paz AG, Miguel I, Coachman C. Fully digital workflow, integrating dental scan, smile design and CAD-CAM: case report. *BMC Oral Health*. 2018;18(1):134. DOI: 10.1186/s12903-018-0597-0.
7. Joda T, Bragger U. Digital vs. conventional implant prosthetic workflows: a cost/time analysis. *Clin Oral Implants Res*. 2015;26(12):1430-5. DOI: 10.1111/clr.12476.
8. Bessadet M, Drancourt N, El Osta N. Time efficiency and cost analysis between digital and conventional workflows for the fabrication of fixed dental prostheses: A systematic review. *J Prosthet Dent*. 2025;133(1):71-84. DOI: 10.1016/j.prosdent.2024.01.003.

9. Pan S, Guo D, Zhou Y, Jung RE, Hammerle CHF, Muhlemann S. Time efficiency and quality of outcomes in a model-free digital workflow using digital impression immediately after implant placement: A double-blind self-controlled clinical trial. *Clin Oral Implants Res.* 2019;30(7):617-26. DOI: 10.1111/chr.13447.
10. Tallarico M. Computerization and digital workflow in medicine: focus on digital dentistry. *Materials (Basel).* 2020;13(9):2172. DOI: 10.3390/ma13092172.
11. Pieper CM, Waldemarin RF, Camacho GB. Masking ability of opaque thickness on layered metal-ceramic. *Acta Odontol Latinoam.* 2016;29(2):162-7.
12. Daou EE. Effect of ceramic layering on the fit of cobalt-chromium alloy 3-unit fixed dental prostheses fabricated by additive, soft milling, and casting technologies. *J Prosthet Dent.* 2021;126(1):130.e1-130.e7. DOI: 10.1016/j.prosdent.2021.03.033.
13. Watanabe H, Fellows C, An H. Digital technologies for restorative dentistry. *Dent Clin North Am.* 2022;66(4):567-90. DOI: 10.1016/j.cden.2022.05.006.
14. Takaichi A, Fueki K, Murakami N, Ueno T, Inamochi Y, Wada J, et al. A systematic review of digital removable partial dentures. Part II: CAD/CAM framework, artificial teeth, and denture base. *J Prosthodont Res.* 2022;66(1):53-67. DOI: 10.2186/jpr.JPR\_D\_20\_00117.
15. Silva LH, Lima E, Miranda RBP, Favero SS, Lohbauer U, Cesar PF. Dental ceramics: a review of new materials and processing methods. *Braz Oral Res.* 2017;31(suppl 1):e58. DOI: 10.1590/1807-3107BOR-2017.vol31.0058.
16. Demirci F, Bahce E, Baran MC. Mechanical analysis of three-unit metal-free fixed dental prostheses produced in different materials with CAD/CAM technology. *Clin Oral Investig.*;26(9):5969-78. DOI: 10.1007/s00784-022-04623-6.

© 2025 Mihai David, Elena Georgiana Radu, Madalina Adriana Malita, Viorel Stefan Perieanu, Maria Antonia Stetiu, Florentina Caministeanu, Ruxandra Stanescu, Mircea Popescu, Mihai Burlibasa, Mihaela Chirila, published by Romanian Rhinologic Society



This is an open access article published under the terms and conditions of the Creative Commons Attribution-NonCommercial-NoDerivatives 4.0 International (CC BY-NC-ND 4.0) License (<https://creativecommons.org/licenses/by-nc-nd/4.0/>). CC BY-NC-ND 4.0 license requires that reusers give credit to the creator by citing or quoting the original work. It allows reusers to copy, share, read, download, print, redistribute the material in any medium or format, or to link to the full texts of the articles, for non-commercial purposes only. If others remix, adapt, or build upon the material, they may not distribute the modified material.