

**CASE REPORT****Orbital cellulitis - complication of an untreated rhinosinusitis: Case report****Lucian Lapusneanu<sup>1</sup>, Elena Dobre<sup>2</sup>, Andreea Naca<sup>3</sup>, Luciana Lapusneanu<sup>4</sup>, Sebastian-Ionut Arjoca<sup>4</sup>**<sup>1</sup>ENT Clinic, Emergency County Clinical Hospital, Braila, Romania<sup>2</sup>Ophthalmology Clinic, Emergency County Clinical Hospital, Braila, Romania<sup>3</sup>Department of Radiology, Emergency County Clinical Hospital, Braila, Romania<sup>4</sup>“George Emil Palade” University of Medicine, Pharmacology, Sciences and Technology, Targu Mures, Romania**ABSTRACT**

Sinusitis not properly treated can generate multiple complications. Among these complications, oculo-orbital manifestations can be difficult to treat and can lead to vision loss, despite modern antibiotic therapy.

In this paper, we aimed to discuss the orbital complications of rhinosinusitis, especially orbital cellulitis, and the method of treatment, highlighted by the presentation of a clinical case diagnosed and treated medically and surgically in the ENT and Ophthalmology Departments, within the Braila County Emergency Clinical Hospital.

**KEYWORDS:** orbital cellulitis, subperiosteal abscess, preseptal cellulitis, proptosis, chemosis.

**INTRODUCTION**

Sinusitis not properly treated can generate multiple complications. Among these complications, those occurring in the orbit can be difficult to treat and can lead to vision loss, despite modern antibiotic therapy. If patients are insufficiently treated, orbital complications can occur in almost 43% of cases<sup>1</sup>.

The germs most commonly involved, especially in children, are *Haemophilus influenzae*, *Staphylococcus Aureus*, *Streptococcus pneumoniae* or beta-haemolytic streptococci<sup>2</sup>.

Before the introduction of antibiotic treatment, more than 20% of patients with periorbital cellulitis developed vision loss and more than 17% died<sup>1</sup>. Even in the era of antibiotics, the condition can be complicated with vision loss, in a percentage between 3 and 11%, but there is a decrease in the mortality rate to 1-2.5%<sup>1</sup>. Most of the cases with orbital complications, although treated with medication, also require the association of surgical treatment with rhinosinusal drainage and orbital decompression, which must not be delayed, in order to avoid vision loss.

According to the Chandler classification<sup>2</sup>, orbital complications comprise 5 stages (Table 1, Figure 1). Later, in 1987, Moloney modified the classification proposed by Chandler,

stating that preseptal anterior orbital infections have a lower priority compared to intra-orbital ones<sup>3</sup> (Table 2). In 1997, Mortimer S. and Wormald PJ. introduced the possibility of imaging investigations (CT) to differentiate periorbital cellulitis from periorbital abscess<sup>4</sup> (Table 2).

Orbital complications of rhinosinusitis are determined by the anatomical relationships between the walls of the orbit, which are common with the paranasal sinuses, thus creating favourable conditions for the expansion of inflammatory and tumoral processes from one area to another<sup>4</sup>. They represent 74-85% of the complications arising from acute sinusitis, especially in the case of acute ethmoiditis<sup>5</sup>. In the specialized literature, we cannot speak of a common opinion related to the sinus that would more frequently cause orbital complications.

Orbital cellulitis is most frequently caused, in all age groups, by ethmoid sinusitis, representing more than 90% of all cases<sup>6</sup>.

In this paper, we aimed to discuss the orbital complications of rhinosinusitis, especially orbital cellulitis, and the method of treatment, highlighted by the presentation of a clinical case diagnosed and treated medically and surgically in the ENT and Ophthalmology Departments, within the Braila County Emergency Clinical Hospital.

**Corresponding author:** Lucian Lapusneanu, MD, ENT Clinic, Emergency County Clinical Hospital, 2 Buzau Street, Braila, Romania

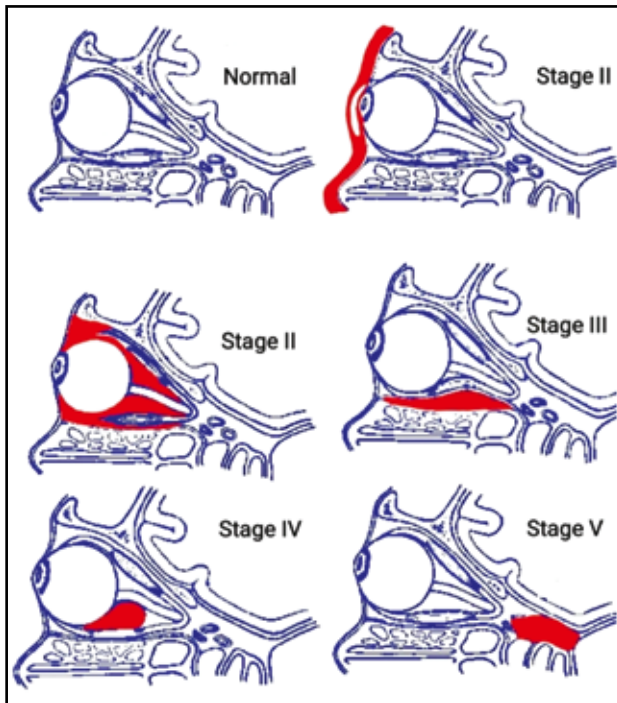
**ORCID:** <https://orcid.org/0000-0002-3817-4837>

**e-mail:** llapusneanu@gmail.com

**Received for publication:** December 29, 2022 / **Accepted:** February 3, 2023

**Table 1. Chandler classification of oculo-orbital complications of rhinosinusitis<sup>2</sup>.**

Stages	Description
I	Preseptal cellulitis; inflammatory edema of the eyelids
II	True orbital cellulitis: diffuse edema of the orbital contents, posterior to the septum
III	Subperiosteal abscess: collection of purulent material between the periorbita and the orbital wall (usually medially and superolateral)
IV	Orbital abscess: abscess collection in the orbital tissue
V	Cavernous sinus thrombosis

**Figure 1.** Stages of oculo-orbital complications of rhinosinusitis.

## CASE REPORT

We present the case of a 19-year-old female patient, with recurrent episodes of rhinosinusitis in the last 5 years, who was urgently admitted to the Ophthalmology Department, for the exacerbation of an exophthalmia that started about 3 days before admission and progressively worsened until the time of admission. This was accompanied by edema in the inner angle of the eye, as well as superior and inferior eyelid edema, chemosis, decreased visual acuity and mobility of the right eyeball, pain when trying to mobilize the eyeball, with the impossibility of opening the eye. Anteroposterior fetid

**Table 2. Moloney and Groote classifications of oculo-orbital complications of rhinosinusitis<sup>3,4</sup>.**

Moloney, 1987	Groote Schuur modification (Mortimer S., Wormald PJ., 1997)
Preseptal cellulitis	Preseptal: a. cellulitis b. abscess
Subperiosteal abscess	Postseptal (subperiosteal): a. phlegmon/cellulitis b. abscess
Orbital cellulitis	Postseptal (intraconal): a. cellulitis b. abscess
Orbital abscess	Localized Diffuse
Cavernous sinus thrombosis	Considered an intracranial complication

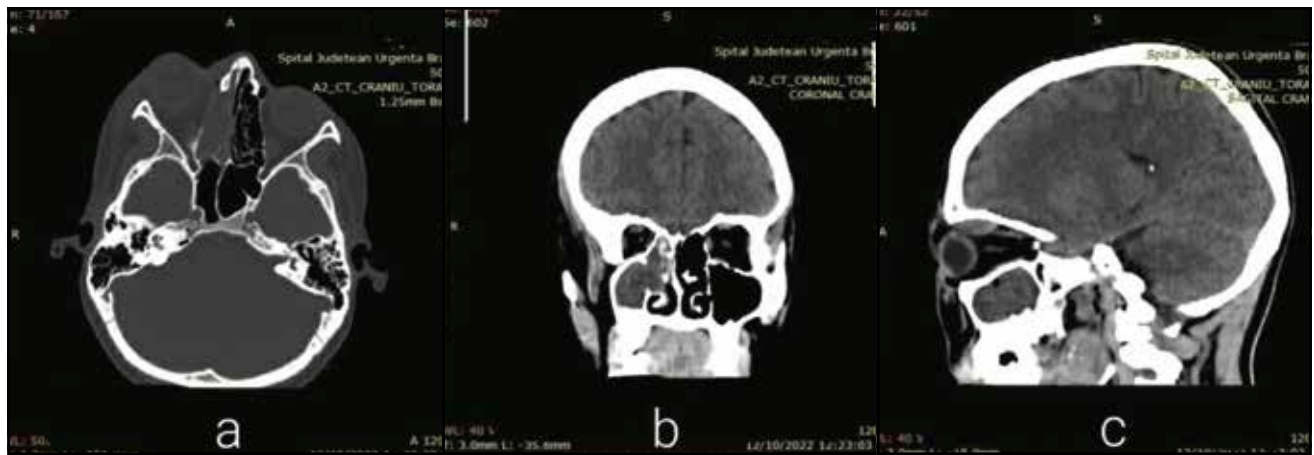purulent rhinorrhea, nasal obstruction, headache, facial pressure in the right maxillo-orbital area, fever were other symptoms that the patient presented. The onset of the condition was approximately 10 days before admission, the patient being treated with various antibiotics (cefaclor 3 days, amoxicillin/clavulanic acid 5 days), administered orally.

The ENT clinical examination revealed proptosis of the right eyeball, with superior and inferior palpebral edema, total occlusion of the palpebral fissure, reduced eyeball mobility and visual acuity (right eye visual acuity (VA) 1/5). During nasal endoscopy, it was possible to observe hyperemia and hypertrophy of the lower and middle nasal turbinates, high nasal septal lateral deviation on the right side, and purulent secretions at the level of the right middle meatus, observed after the anemization of the nasal mucosa.

The native craniofacial CT examination revealed: significant proptosis of the right eyeball, with elongation of the optic nerve; hypodense accumulations that completely occupied the frontal, anteroposterior ethmoidal, maxillary sinuses and circumferential inflammation of the right sphenoidal sinus mucosa, with obstruction of the ostiomeatal complex; the internal wall of the maxillary sinus, respectively the anterior wall of the right sphenoidal sinus appears interrupted; areas of hyper- and hypodensity at the level of the orbital fat; right septal lateral deviation, inferior nasal turbinate hypertrophy (Figure 2). No CT signs of intracranial extension.

Taking into account the clinical aspect, the nasal endoscopic aspect, supplemented by the craniofacial CT examination, the diagnosis of chronic recurrent right pansinusitis (fronto-maxillo-ethmoid-sphenoidal) was established, complicated with right orbital cellulitis.

It was decided to transfer the patient from the Ophthalmology Department to the ENT Department, for specialized



**Figure 2.** Cranio-facial CT examination (a. axial section; b. coronal section; c. sagittal section): important accumulations with mixed fluid and parafluid densities that completely occupy the cavities of the fronto-maxillary sinuses and the ethmoid cells on the right side, but also the nasal cavity on the same side, with obstruction of the ostiomeatal complex (a,b,c); the internal wall of the maxillary sinus, respectively the anterior wall of the right sphenoidal sinus appears interrupted (a,b); important diffuse densification of the periorbital and anterior adipose tissue on the right side with an inflammatory substrate that extends extraconally; exophthalmia on the same side (a).

medical and surgical treatment, through rhinosinusal drainage and orbital decompression. Approximately 24 hours preoperatively, intravenous infusion treatment with Imipenem 2g/day, associated with Metronidazole 2g/day, hydrocortisone hemisuccinate 100mg/day, Dexamethasone 8mg/2ml/day was instituted.

Endoscopic surgery was performed under OTI general anaesthesia. In the first stage, the high lateral-deviated portion of the nasal septum, which blocked the access to the right middle meatus, was removed. Subsequently, we performed the maxillary antrostomy and the anteroposterior ethmoidectomy on the right side, with the drainage of a significant amount of dense fetid purulent secretion and the maxillary and ethmoid irrigation with saline solution.

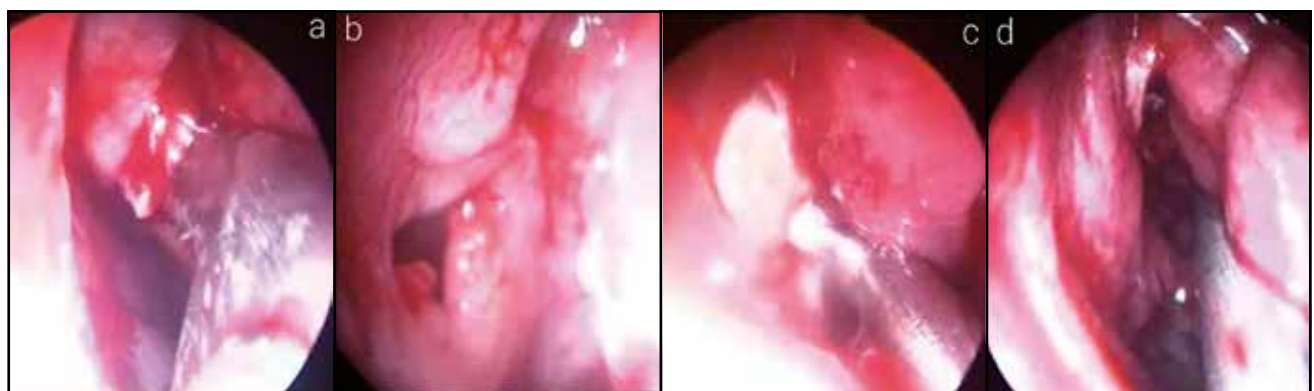
The appearance of the maxillary-ethmoidal mucosa showed inflammatory degeneration and a tumor formation of about 5 mm in diameter was removed from the anterior ethmoidal sinus, which was sent for histopatho-

logical examination. The intraoperative sample taken from this area did not show a specific flora. We continued with the removal of the lamina papyracea, exposing the periorbita, with the externalization of minimal purulent secretions from this level and frontal sinus drainage Draf type I on the right side. (Figure 3).

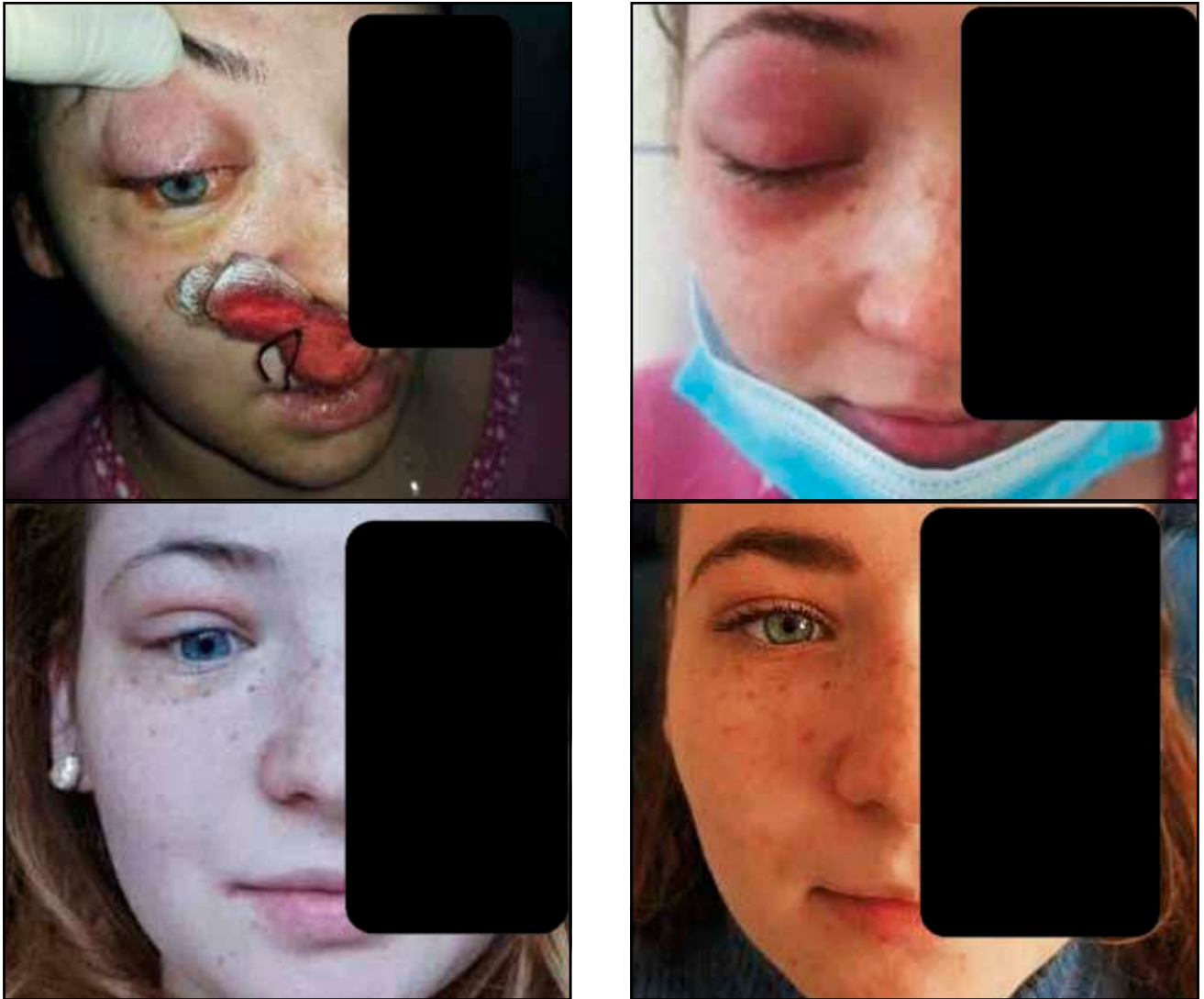The intrasinus irrigation was performed with saline solution, then a partial inferior turbinectomy with removal of the anterior-posterior-inferior portion of the inferior nasal turbinate that completely obstructed the inferior meatus.

Finally, after checking haemostasis, anterior nasal packing was performed at the level of the middle meatus with a Mero-cel® haemostatic tampon and gauze into the inferior meatus, which was removed after 24 hours.

The histopathological examination of the analyzed surgical piece highlighted a polypoid formation lined with respiratory epithelium, with edematous stroma and mixed inflammatory infiltrate.



**Figure 3.** Intraoperative aspect: **a.** removal of the lateral-deviated portion of the nasal septum; **b.** right antrostomy; **c.** right ethmoidectomy with drainage of purulent secretions; **d.** exposure of lamina papyracea.



**Figure 4.** Postoperative evolution, evolving clinical appearance on postoperative days 1, 3, 8, and 15 – progressive reduction of the superior-inferior palpebral edema, of chemosis; restoration of eyeball mobility and visual acuity.

Postoperatively, the evolution of the patient was favourable, with the improvement of visual acuity and the mobility of the eyeball, as well as the disappearance of proptosis. The reduction of the superior-inferior palpebral edema and of the edema in the internal angle of the eye was achieved during the first postoperative week (Figure 4).

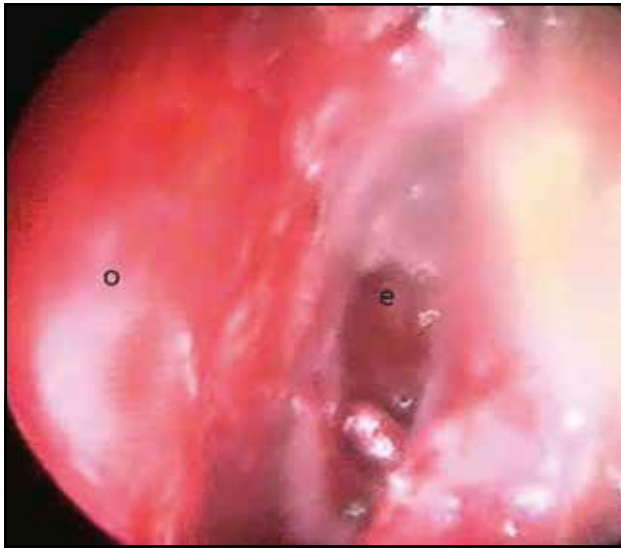
The patient received infusion therapy with antibiotics (Imipenem) for 8 days postoperatively, Metronidazole for another 4 days and anti-inflammatories (Dexamethasone for another 5 days, hydrocortisone hemisuccinate for another 7 days), antihistamine medication, rhinosinusual lavage with saline solution and daily aspiration of the nasal fossae.

At the same time, ophthalmological checks were carried out, with visual acuity testing and fundus examination, administration of local topical treatment (Netilmicin, solution with Dexametasone and Neomicin, Fluorometholone - 2

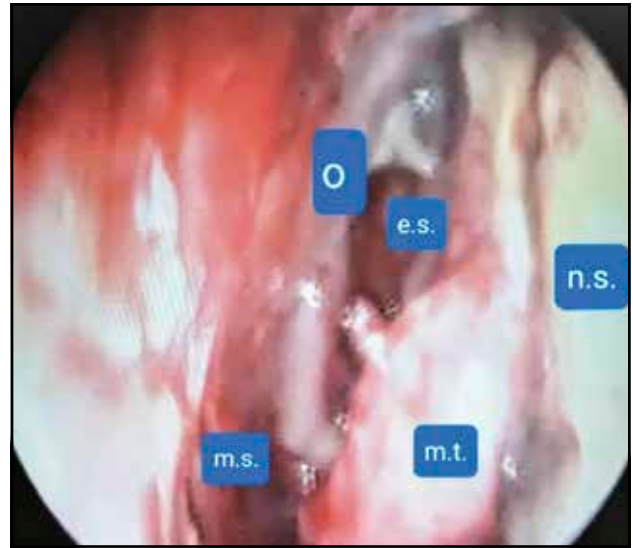
drops each x 4 times/day, ointment with Tobramycin and Dexametasone for eyelid and conjunctival applications). These examinations showed, in dynamics, a progressive recovery of visual acuity and mobility of the eyeball, as follows:

- on the first postoperative day – right eye VA = 2/3, persistence of palpebral edema, chemosis present, but reduced, the palpebral fissure opening is voluntary up to one-third, reduced horizontal eye mobility and normal vertical eye mobility;
- on the 3<sup>rd</sup> day after surgery – right eye VA = 1/2, moderate eyelid edema, disappearance of chemosis, the eyelid opens halfway, ocular mobility present horizontally and vertically;
- on the 5<sup>th</sup> day after surgery – right eye VA = 2/3, in medication-induced mydriasis and with one stenopeic point, eyelid edema in remission, right eye with intact eyeball.





**Figure 5.** Nasal endoscopic examination – aspect at 7 days postoperatively (o - orbit, e - ethmoid) – crusty secretions and inflammatory edema at the level of the ethmoid cells.



**Figure 6.** Endoscopic control performed 2 weeks postoperatively (o - orbit, e.s.- ethmoid sinus, m.s. - maxillary sinus, m.t. - middle turbinate, n.s. - nasal septum).

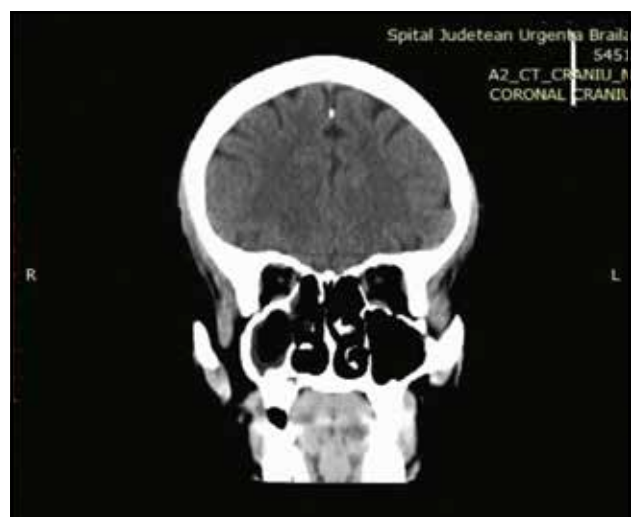
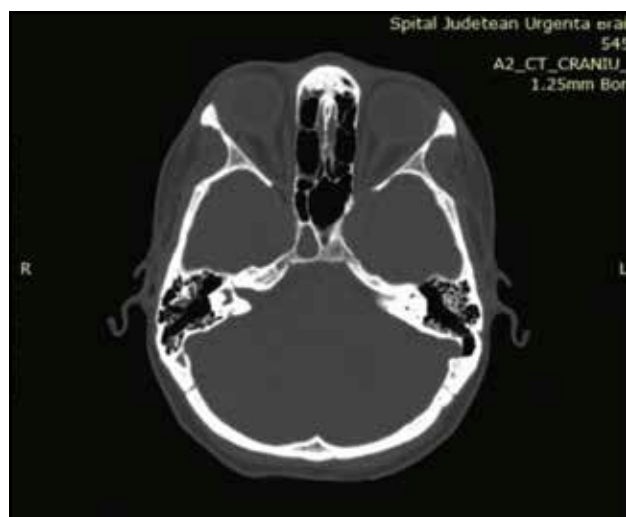On the 7<sup>th</sup> and 15<sup>th</sup> day postoperatively, the patient had normal visual acuity and mobility of the eyeball, the superior and inferior eyelid edema and chemosis disappearing completely. The nasal cavity showed crusty secretions on the 7<sup>th</sup> day after surgery (Figure 5), which disappeared completely 15 days after surgery (Figure 6).

The follow-up craniofacial CT scan, performed on the 8<sup>th</sup> day after surgery, revealed the disappearance of paraf fluid and hypodense processes at the level of the right frontal, maxillary and ethmoid sinuses, reduction of the inflammatory reaction in the intraconal fat and muscle edema, but also the return of the eyeball to its normal position (Figure 7).

## DISCUSSIONS

Acute and especially chronic rhinosinusitis can produce, in some conditions (anatomical particularities, in our case the high deviation of the nasal septum, overlapping of respiratory viral infections, local traumas), a series of complications, some particularly serious from a vital and functional point of view, such as orbital and endocranial complications. These complications are caused by the anatomical position of the sinus cavities, interposed between the nasal fossae, the orbit, the anterior and middle floors of the skull base.

There are several theories that try to explain the spread of the infection from the level of the paranasal sinuses to the



**Figure 7.** Native cranio-facial CT examination (axial, coronal sections) 8 days postoperatively: the significant reduction of changes in the right pansinusitis, the edematous periorbital cellulitis as well as exophthalmia.

neighbouring structures. The infection can spread to the orbit or endocranium most often by contiguity, since the sinuses have neighbouring relationships with the orbit. Another possibility for intraorbital and intracranial extension of the sinus infection is through the vascular, lymphatic and perineural network, represented by the anastomoses between the vessels of the nasal fossae, paranasal sinuses, orbit, and pterygoid plexus. Bone dehiscence (congenital or post-traumatic) represents another way of spreading the infection through a direct mechanism.

In orbital cellulitis, the evolution of the infection can also generate serous cellulitis, frequently unilateral, which when deep, has an orbital pseudo-phlegmonous aspect, which can lead to partial immobilization of the eyeball<sup>7,8</sup>. The orbital infectious process can cause elongation and compression of the optic nerve. In this case, ischemia and hypoxemia of the nerve can occur, causing blindness<sup>8</sup>. The general signs in this case are marked by exophthalmos and palpebral edema, marked decrease in visual acuity, immobilization and pain of the eyeball. Cellulite expansion can cause "orbital apex syndrome", which would involve the anatomical structures at the orbital apex (cranial nerves II-VI, ophthalmic arteries and veins).

Orbital cellulitis is a serious, life-threatening complication that requires surgical treatment of the affected sinus and immediate surgical decompression of the orbit<sup>9</sup>.

Depending on age and etiology, there can be various pathogens. *Streptococcus pneumoniae* is the most common pathogen associated with sinus infection, while *Staphylococcus aureus*, respectively *Staphylococcus pyogenes*, can predominate when the infection is triggered after local trauma. *Haemophilus influenzae* type b was frequently involved, until widespread vaccination was introduced. Fungi are unusual pathogens that can cause orbital cellulitis in diabetic or immunosuppressed patients<sup>10</sup>. In pediatric patients up to the age of 15, the infection is in most cases polymicrobial, associating aerobic and anaerobic bacteria. In small children, under the age of 9, a single aerobic organism is most frequently responsible<sup>11</sup>.

Currently, the management of the inflammatory pathology of the orbit caused by rhinosinusitis is based on local and general antibiotic therapy, anti-inflammatories, antihistamines, surgical treatment of rhinosinusitis associated with or without drainage of the secondary suppurative orbital focus<sup>2</sup>. These do not guarantee the absence of relapses, because resistant germs manage to spread and cannot be identified. There is also a risk of developing adverse reactions, due to the impossibility of differential diagnosis between bacterial and viral etiology, but also due to the increased frequency of fungal sinusitis.

Antibacterial treatment is initially empirical. Since orbital cellulitis is commonly caused by staphylococcus and streptococcus species, penicillins and cephalosporins are generally the best choices for intravenous antibiotic treatment. Depending on the predominant microflora (determined after the nasal secretion examination), its resistance in the re-

spective area and the form of the pathology, the treatment is further decided according to the antibiotic sensitivity of the detected bacterial germ<sup>2</sup>. The selected antibiotic must have the ability to cross the blood-brain barrier in order to prevent intracranial complications following orbital infections. Surgical intervention in intraorbital inflammatory pathologies is necessary in 12-66% of all orbital complications of rhinosinusogenic etiology<sup>2</sup>.

According to the American Academy of Ophthalmology<sup>12</sup>, the management of orbital cellulitis requires hospitalization and the start of treatment with broad-spectrum intravenous antibiotics that target the most common pathogens. Blood cultures and nasal/pharyngeal exudates may be performed, and antibiotics should be changed based on the results. In infants with orbital cellulitis, a third-generation cephalosporin such as cefotaxime, ceftriaxone, or ceftazidime is usually initiated along with a penicillinase-resistant penicillin. In older children and adults, since sinusitis is most commonly associated with aerobic and anaerobic organisms, clindamycin may be another option. Metronidazole is also increasingly used in children. If there is concern for MRSA infection, vancomycin can also be added. As previously mentioned, the antibiotic regimen should be modified based on culture results, if necessary<sup>13</sup>. Intravenous corticosteroids may also be administered in the management of pediatric orbital cellulitis<sup>2</sup>.

The use of corticosteroids in the treatment of orbital cellulitis is controversial. The possibility of suppressing the immune system and worsening the disease process should be considered<sup>7</sup>.

According to the literature, rhinosinusal surgical treatment that also includes orbital decompression is indicated in the presence of the following criteria<sup>11,14</sup>:

- Progression of symptoms or lack of improvement within 24-48 hours of antibiotic treatment;
- Detection of an orbital abscess on the craniofacial CT examination;
- Decreased visual acuity (20/60); in these cases there is a major risk of blindness;
- Severe orbital complications on the background of ipsilateral sinusitis (blindness, associated pupillary reflex, ophthalmoplegia, exophthalmia).

Surgical treatment includes a wide spectrum of procedures, ranging from extranasal ethmoidectomy to endoscopic surgery. The interventions are aimed at removing the pathological focus, by draining both the sinus and the orbit. The introduction of the endoscopic technique into medical practice has radically changed the direction of the treatment of sinusitis and its complications<sup>10,11,14</sup>. The external surgical approach can be performed in cases where we face a subperiosteal abscess, which is located in the superomedial part of the orbit. The treatment is carried out complexly in the ophthalmology and ENT departments.

The antibiotic and corticosteroid treatment administered in orbital complications has made it possible to sig-

nificantly improve the prognosis of the respective pathology, but it did not reduce the number of patients, due to the high virulence of the bacterial microflora, acquired resistance to the action of broad-spectrum antibacterial drugs, increase in the etiological role of viruses in sinusitis and the immunological changes that occur in the human body<sup>7,10</sup>.

## CONCLUSIONS

Orbital cellulitis is one of the complications of rhinosinusitis not treated appropriately.

The appearance of edema in the inner angle of the eye and in the superior and inferior eyelid, reduced mobility of the eyeball, exophthalmia, local pain, the impossibility of opening the eye, decreased visual acuity are important signs of this condition, and the disappearance of the perception of the colour red marks the beginning of vision loss.

Early diagnosis is important to prevent this type of complications. Conservative treatment can be applied in small subperiosteal abscesses when vision is normal and there is no preseptal cellulitis, orbital cellulitis or limitation of eye movements. In addition to correctly administered medical treatment, sinus drainage and orbital decompression should not be delayed.

In cases where there is a limitation of eye movements and a decrease in visual acuity, surgical drainage should be performed urgently.

**Conflict of interest:** The authors have no conflict of interest.

**Contribution of authors:** All the authors have equally contributed to this work.

**Financial disclaimer:** There are no financial disclosures of the authors.

### Authors' information:

Lucian Lapusneanu, MD, ENT Clinic, Emergency County Clinical Hospital, Braila, Romania. E-mail: llapusneanu@gmail.com. ORCID: <https://orcid.org/0000-0002-3817-4837>.

Elena Dobre, MD, Ophthalmology Clinic, Emergency County Clinical Hospital, Braila, Romania. E-mail: elena\_dobre\_dryahoo.com.

Andreea Naca, MD, Department of Radiology, Emergency County Clinical Hospital, Braila, Romania. E-mail: andreeacarmennaca@yahoo.com.

Luciana Lapusneanu, Medical Student, "George Emil Palade" University of Medicine, Pharmacology, Sciences and Technology, Targu Mures, Romania. E-mail: lucianalapusneanu@gmail.com.

Sebastian-Ionut Arjoca, Medical Student, "George Emil Palade" University of Medicine, Pharmacology, Sciences and Technology, Targu Mures, Romania. E-mail: arjoca\_sebastian@yahoo.com.

## REFERENCES

- Liao JC, Harris CJ. Subperiosteal abscess of the orbit: evolving pathogens and the therapeutic protocol. *Ophthalmology*. 2015;122(3):639-47. DOI: 10.1016/j.ophtha.2014.09.009.
- Chandler JR, Langenbrunner DJ, Stevens ER. The pathogenesis of orbital complications in acute sinusitis. *Laryngoscope*. 1970;80(9):1414-28. DOI: 10.1288/00005537-197009000-00007.
- Moloney JR, Badham NJ, McRae A. The acute orbit. Preseptal (periobital) cellulitis, subperiosteal abscess and orbital cellulitis due to sinusitis. *J Laryngol Otol Suppl*. 1987;12:1-18.
- Mortimore S, Wormald PJ. The Groote Schuur hospital classification of the orbital complications of sinusitis. *J Laryngol Otol*. 1997;111(8):719-23. DOI: 10.1017/s0022215100138459.
- Suhaili DNP, Goh BS, Gendeh BS. A ten year retrospective review of orbital complications secondary to acute sinusitis in children. *Med J Malaysia*. 2010;65(1):49-52.
- Gushchin AG. Orbital cellulitis. [Internet]. Medscape. Available from: <https://emedicine.medscape.com/article/1217858-overview>.
- Ababii I, Maniuc M, Sandul A, et al. Otorinolaringologie. *Medicina*, Chisinau; 2019, p.111.
- Liu IT, Kao SC, Wang AG, Tsai CC, Liang CK, Hsu WM. Preseptal and orbital cellulitis: a 10-year review of hospitalized patients. *J Chin Med Assoc*. 2006;69(9):415-22. DOI: 10.1016/S1726-4901(09)70284-9.
- Yen MT, Yen KG. Effect of corticosteroids in the acute management of pediatric orbital cellulitis with subperiosteal abscess. *Ophthalmic Plast Reconstr Surg*. 2005;21(5):363-6; discussion 366-7. DOI: 10.1097/01.iop.0000179973.44003.f7.
- Sorbalo I. Afecțiuni inflamatorii ale orbitei ca complicație rinosinusogenă (revista literaturii). *Analele Stiintifice ale USMF "N. Testemitanu"*. 2011;4(12):393-9.
- Chang CC, Inaudo GA, Gershwin ME. Diseases of the sinuses: a comprehensive textbook of diagnosis and treatment. 2<sup>nd</sup> ed. Springer; 2014.
- Mawn LA, Hong CJ, Dmitriev P, Feldman BH, Epley KD, Adamopoulou C, et al. Orbital cellulitis. [Internet]. EyeWiki. Available from: [https://eyewiki.aaao.org/Orbital\\_Cellulitis](https://eyewiki.aaao.org/Orbital_Cellulitis).
- Liao S, Durand ML, Cunningham MJ. Sinogenic orbital and subperiosteal abscesses: microbiology and methicillin-resistant *Staphylococcus aureus* incidence. *Otolaryngol Head Neck Surg*. 2010;143(3):392-6. DOI: 10.1016/j.otohns.2010.06.818.
- Kennedy DW, Bolger WE, Zinreich SJ. Diseases of the sinuses: diagnosis and management. 1<sup>st</sup> Edition. PMPH USA; 2001.



This is an open access article published under the terms and conditions of the Creative Commons Attribution-NonCommercial-NoDerivatives 4.0 International (CC BY-NC-ND 4.0) License (<https://creativecommons.org/licenses/by-nc-nd/4.0/>). CC BY-NC-ND 4.0 license requires that reusers give credit to the creator by citing or quoting the original work. It allows reusers to copy, share, read, download, print, redistribute the material in any medium or format, or to link to the full texts of the articles, for non-commercial purposes only. If others remix, adapt, or build upon the material, they may not distribute the modified material.